

Ahmed Valve Implantation Versus Sub-Scleral Trabeculectomy with Mitomycin in Neovascular Glaucoma Pretreated with Intra-Vitreous Ranibizumab and Panretinal Photocoagulation

¹Hazem Helmy and ²Mahmoud Leila

¹Glaucoma and Optic Nerve Diseases Department, Glaucoma Unit,
Research Institute of Ophthalmology, Egypt

²Retina Department, Vitreoretinal Surgery Unit, Research Institute of Ophthalmology, Egypt

Abstract: This work aimed to compare the effectiveness of Ahmed valve implant versus sub-scleral trabeculectomy with mitomycin C in patients with neovascular glaucoma pretreated with intra-vitreous ranibizumab and panretinal photocoagulation. Methods: prospective comparative non-randomized controlled study including patients with NVG pretreated with intra-vitreous ranibizumab and PRP then evenly distributed into two groups. Patients enrolled in group 1 underwent Ahmed valve implantation; whereas those enrolled in group 2 underwent sub-scleral trabeculectomy combined with MMC. Results: the study recruited 50 patients. Mean age was 62 years. Mean pre-operative IOP was 46.5 mmHg in group 1 and 46.2 mmHg in group 2. Mean post-operative IOP in group 1 was 12.7 and 18.9 mmHg at months 1 and 24, respectively. Mean post-operative IOP in group 2 was 12.15 and 19.7 mmHg at months 1 and 24, respectively. The difference between both groups in terms of IOP values was not statistically significant at any time point throughout the study. Post-operative complications occurred in 30% and 45% of patients in groups 1 and 2 respectively and were controlled medically within one week. Conclusion pretreating NVG with intra-vitreous ranibizumab and PRP improves glaucoma surgery success rate. Ahmed valve implant and trabeculectomy with MMC appear to be equally effective in controlling IOP.

Key words: Ahmed Valve Implantation • Subscleral Trabeculectomy with Mitomycin • Ranibizumab and PRP in NVG

INTRODUCTION

Neovascular glaucoma (NVG) is a progressive secondary glaucoma that is notorious of being resilient to treatment [1]. The disease begins with neovascularization of the iris and/or the angle in the presence of normal intraocular pressure (IOP) [2]. Later on, synechial angle closure ensues and IOP increases markedly. The disease is also characterized by progressive inflammation of the anterior segment [3-5]. Pathogenesis could be multifactorial and often involves underlying causes not present in other types of glaucoma including diabetes mellitus (DM), central retinal vein occlusion (CRVO) and ocular ischemic syndrome [1,6]. These conditions precipitate retinal ischemia that trigger release of vascular endothelial growth factor (VEGF), interleukins and other angiogenic factors that eventually cause

neovascularization of the anterior segment. Neovascularization obstructs the trabeculum and causes peripheral anterior synechia (PAS). Consequently, aqueous outflow decreases and IOP increases [7-9]. Treating the underlying ischemia is, therefore, crucial in controlling the disease. In addition, anti-VEGF drugs are useful in promoting regression of neovascularization thereby evading PAS, angle closure and IOP rise [10-13].

Despite the encouraging outcome of anti-VEGF treatment, surgery often is the method of choice for lowering IOP especially in cases of synechial angle closure. Ahmed glaucoma valve is considered the first choice for treating these cases. The procedure does not entail iris manipulation that may precipitate bleeding and is not associated with marked post-operative hypotony like other glaucoma implants, mini-shunts, or trabeculectomies [14].

Glaucoma filtering surgery for NVG in the form of traditional trabeculectomy is often unsuccessful [15]. Therefore, antimetabolites, like MMC and 5-fluorouracil (5 FU), are useful to augment the therapeutic effect of surgery. These agents act by modulating the wound healing process to lessen scar formation around scleral flap in trabeculectomy [16]. Ablation of VEGF-producing ischemic retina and hence the neovascular stimulus using adequate PRP has been used to improve the effectiveness of augmented trabeculectomy [17].

The aim of this study is to compare the effectiveness of Ahmed valve implant versus sub-scleral trabeculectomy with MMC in patients with NVG pretreated with intra-vitreous ranibizumab and panretinal photocoagulation.

MATERIALS AND METHODS

The study included 50 patients with NVG. Patients were recruited from the glaucoma and retina clinics of the Research Institute of Ophthalmology – Egypt during 2011-2012. All surgical procedures were done by the same surgeon (HH). Inclusion criteria were NVG with IOP uncontrolled with medical treatment, synechial angle closure greater than 180° and angle grading 0-1 by gonioscopy. Visual acuity had to be better than hand movement (HM). Patients with visual acuity worse than HM, previous ocular surgery, media opacities precluding fundus examination and laser treatment, medical condition that would contraindicate intra-vitreous ranibizumab injection as uncontrolled hypertension or cerebrovascular disease were excluded from the study.

Pre-operative examination included Snellen best-corrected visual acuity (BCVA), slit-lamp anterior segment examination, gonioscopy, goldmann's applanation tonometry and fundus examination using indirect ophthalmoscopy and slit-lamp biomicroscopy using +90D lens.

All patients received intra-vitreous injection of ranibizumab (Lucentis, Genentech, Inc., South San Francisco, CA). Lucentis was injected at a dose of 0.5mg in 0.05mL in the operation theatre under complete sterile conditions. Three days later, patients underwent PRP according to the protocol of the central retinal vein occlusion study group [18]. One week later patients were examined to detect regression of neovessels and were allotted into 2 groups each comprising 25 patients. Patients enrolled in group 1 underwent Ahmed valve implantation; whereas those enrolled in group 2 underwent sub-scleral trabeculectomy combined with MMC application.

Surgical Techniques

Ahmed Valve Implantation (AGV S2 model, New World Medical, Inc., Rancho Cucamonga, California, USA):

Fornix-based conjunctival flap (10-12 mm) with a relaxing incision was fashioned in the supero-temporal quadrant. The tube of the valve was primed with balanced salt saline (BSS) before insertion in order to ensure that all air is removed and the valve is functioning. The body of the plate was held near the eyelets and inserted into a sub-conjunctival pocket created with the anterior edge 8-10 mm from the limbus. The valve plate was sutured to the sclera with non-absorbable 10/0 nylon sutures. The length of the drainage tube was measured by placing it over the cornea to ensure that the future cut length is adequate when placed into the anterior chamber. The drainage tube was then cut with a bevel facing upward toward the corneal endothelial surface and extended 2 mm from the limbus inside the anterior chamber. A paracentesis was then performed using a microkeratome to allow reformation of the anterior chamber when needed. A limbal-based half thickness scleral flap 4x4 mm was then dissected and a 23-gauge needle was used to enter the anterior chamber under the scleral flap, the tube was then inserted into the anterior chamber and the flap was sutured over the tube using 8/0 nylon sutures. The conjunctiva was closed with 8/0 polyglactin sutures. Antibiotics and steroids were injected sub-conjunctivally 180° away from the surgical site.

Sub-scleral Trabeculectomy Augmented with MMC (Mitomycin 10 mg, Kyowa Hakko Kogyo Co. Ltd., Tokyo, Japan):

A fornix-based conjunctival peritomy 5-6 mm was fashioned at the superior limbus using blunt dissection. A blunt scissor was used to dissect postero-laterally under tenon's capsule to the mid-equator to promote posterior outflow. A 4x4 mm half-thickness scleral flap was created and dissection was carried anteriorly into clear cornea. Three sponges 1 mm wide and 2 mm long were soaked in 0.4 mg/ml mitomycin C. The first sponge was placed under the conjunctiva and pushed temporally as far as possible. The second sponge was placed nasally and the third sponge was placed at the 12 o'clock position. The sponges were applied for 3 minutes then removed. The area of the sclera and underside of tenon's/conjunctival flap was washed with 25 ml BSS. Paracentesis was done obliquely parallel to the limbus in the peripheral cornea away from the surgical site. Acetylcholine was injected for induction of miosis. An internal scleral block excision was done followed by peripheral iridectomy. The scleral flap was closed using two 10/0 nylon sutures one in each corner. The

conjunctiva was closed using 8/0 polyglactin wing sutures. The bleb was tested using BSS injected through the paracentesis to ensure patency of the ostium, as well as formation and sealing of bleb. Antibiotic and steroids were injected sub-conjunctivally away from surgical site.

Post-operatively, all patients were examined at one day, one week, 1 month, 3 months and then 3-monthly thereafter. Follow-up period was set at 24 months. Each visit included Snellen BCVA measurement, slit-lamp anterior segment examination, goldmann's applanation tonometry, fundus examination using indirect ophthalmoscopy and slit-lamp biomicroscopy using +90D lens. Gonioscopy was performed at each visit as from one month post-operatively. Main outcome measure was IOP ≥ 6 mmHg and ≤ 21 mmHg. Early post-operative hypotony was defined as IOP ≤ 5 mm Hg. Secondary outcome measure was detection of surgical complications.

All procedures and follow-up visits were done at the Research Institute of Ophthalmology (R.I.O.) - Ministry of Scientific Research, Egypt. The study was performed in accordance with the tenets of the Declaration of Helsinki of 1975 (The 1983 revision). The Research Committee of The Research Institute of Ophthalmology approved the protocol of the study. All patients received a thorough explanation of the procedures entailed in the study and signed an informed consent prior to enrollment.

Statistical Analysis: For all determinations, statistical analysis was carried out including the calculation of the mean, standard deviation, standard error and t-value at level $p < 0.05$ for both groups. The results were statistically evaluated according to the "t" test.

Independent-Samples t-Test: The Independent-Samples T-Test procedure compares means for two groups of cases. Ideally, for this test, the subjects should be randomly assigned to two groups, so that any difference in response is due to the treatment and not to other factors. The significance of the measured data was considered as follows, non-significant (N.S) when $P > 0.05$, significant (S) when $P < 0.05$ and highly significant (H.S) when $P < 0.01$, where P is the probability (Reflect of null hypothesis).

Regression Analysis: The regression line can thus be written as $y_i = A + b x_i$

The same test was used for comparison of two groups in order to draw the experimental results as an illustrative graph showing the effect of different treatments using the whole studies.

RESULTS

Patient Characteristics: The study recruited 50 patients distributed evenly among two groups. Ten patients, 5 from each group were excluded from the study because they did not complete the required follow-up period. Statistical analysis was therefore performed for the remaining 40 patients, 21 women and 19 men. Mean age was 62 years (Range 40-79, SE 1.4). Mean pre-operative IOP was 46.3 mmHg (Range 39-51). Pre-operatively, 20 patients (50%) relied on 3 topical anti-glaucoma medications, whereas the remaining 50% relied on 4 drops. Underlying disease that caused NVG was CRVO in 15 patients (37.5%), PDR in 22 patients (55%) and ocular ischemic syndrome in 3 patients (7.5%). Gonioscopy revealed 180°, 270° and 360° synechial angle closure in 4 (10%), 4 (10%) and 32 (80%) of patients respectively (Table 1).

Post-operative Outcome

Intra-ocular Pressure Control: In group 1, IOP dropped at 1 month post-operatively to a mean of 12.7 mmHg from a mean pre-operative value of 46.5 mmHg ($p < 0.000$). IOP continued rising steadily to reach mean value of 18.9 mmHg at 24 months. Mean difference between pre-operative and post-operative IOP was (33.8 mmHg, SE 0.6) at 1 month ($p < 0.000$) and (27.5 mmHg, SE 1.03) at 24 month ($p < 0.000$).

Table 1: Baseline characteristics

	N (%)
Female	21 (52.5)
Male	19 (47.5)
Mean Age(years)	
Group 1 (Ahmed valve)	61.1
Group 2 (Trabeculectomy with MMC)	63
Total	62
Underlying pathology	
CRVO	15 (37.5)
PDR	22 (55)
Ocular Ischemic Syndrome	3 (7.5)
Gonioscopy	
180° closure	4 (10)
270° closure	4 (10)
360° closure	32 (80)
Mean pre-operative IOP(mmHg)	
Group 1	46.5
Group 2	46.2
Total	46.3

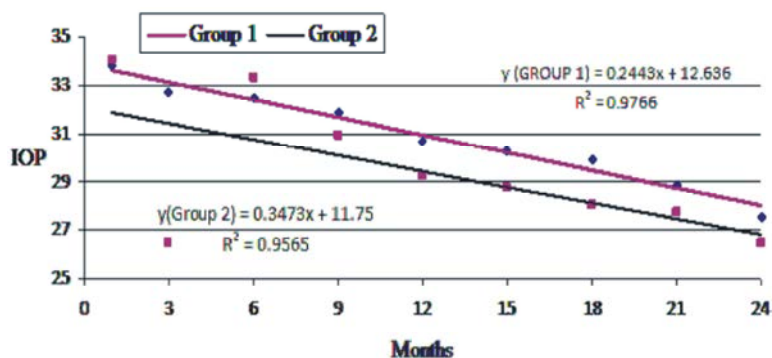


Fig. 1: Comparison between group 1 and group 2 for post-operative IOP values

In group 2, IOP dropped at 1 month post-operatively to a mean of 12.15 mmHg from a mean pre-operative value of 46.2 mmHg (p 0.000). IOP continued rising steadily to reach mean value of 19.7 mmHg at 24 months. Mean difference between pre-operative and post-operative IOP was (34.05 mmHg, SE 0.7) at 1 month (p 0.000) and (26.4 mmHg, SE 1.006) at 24 month (p 0.000).

The difference between both groups in terms of IOP values both at the start of follow-up and through the end of the study was not statistically significant at any time point. Figure 1.

Thirty-three (82.5%) of patients did not require additional anti-glaucoma medication in the post-operative period. Four patients in group 1 and 3 patients in group 2 required single anti-glaucoma topical medication to maintain their IOP below 21mm Hg.

Surgical Complications: In terms of post-operative complications, 6 patients in group 1 (30%) developed complications. These included hyphema in 5 patients and choroidal effusion in 1 patient. In group 2, 9 patients (45%) developed complications. These included hyphema in 6 patients, early hypotony in 2 patients and late wound leak in 1 patient.

DISCUSSION

Patients with NVG refractory to medical and laser therapy are often managed with glaucoma drainage implants or trabeculectomy with antimetabolites. Glaucoma drainage implants are recommended as primary choice in patients with NVG having severe inflammation of the anterior segment [19]. Trabeculectomy with antimetabolites could be an appropriate procedure in selected cases of NVG. The rationale for using antimetabolites as MMC is derived from the alkylating properties of the drug that effectively inhibit DNA

replication and fibroblast activity thus augmenting the success rate of filtration surgery [20-21].

Nevertheless, Hyung and Kim [16] reported a success rate as low as 29% at 1 year follow-up after using MMC with trabeculectomy. The authors attributed this high failure rate to severe inflammation of anterior segment and high levels of VEGF in the aqueous humor that promoted fibroblast proliferation and scar formation. In concordance, Pe'er *et al.* [22] implicated VEGF as a predominant factor in the pathogenesis of intraocular neovascularization and NVG. Similarly, Boyed *et al.* [23] found a close temporal correlation between aqueous VEGF levels and iris neovascularization and permeability in ischemic CRVO.

Proper management of NVG refractory to medical treatment mandates maximum control of neovascularization and reduction of VEGF load prior to incisional surgery to halt the scarring cascade and post-operative complications including post-operative bleeding and inflammation, corneal edema, hyphema and /or vitreous hemorrhage [24].

The current study evaluated the surgical outcome of Ahmed valve implant versus trabeculectomy with MMC for eyes with NVG refractory to medical treatment. Patients were pretreated with anti-VEGF and PRP.

Post-operative IOP dropped significantly from baseline pre-operative value in both groups included in the present study. Though IOP values have shown gradual steady rise throughout the follow-up period, the mean value remained below 21 mmHg in 100% of our cases while maintaining statistical significance as compared to pre-operative IOP values. It is worthy of note that 33 (82.5%) of our patients did not require any additional anti-glaucoma medication at any time during the post-operative period. We did not detect a statistically significant difference in terms of post-operative IOP values between Ahmed valve implant and sub-scleral

trabeculectomy with MMC both at the start of follow-up and through the end of the study at any time point. Therefore, we don't have basis to recommend that one technique is more effective than the other.

In comparison, Mahdy *et al.* [25] compared Ahmed valve implantation with avastin versus Ahmed valve alone in a series of 40 patients with refractory NVG. Patients were pre-treated with PRP. These authors reported control of IOP to values of ≤ 21 mmHg in 75% of cases without medication and in 20% of cases with medication in the group treated with Ahmed valve with avastin and in 50% of patients in the group treated with Ahmed valve alone, but with 25% of those patients requiring post-operative medication. The follow-up period was 18 months.

Shen *et al.* [26] compared trabeculectomy with MMC versus Ahmed valve implantation. Their inclusion criteria did not require pre-treatment with anti-VEGF or PRP. The average follow-up period was 31 months for the Ahmed valve group and 25 months for the trabeculectomy group. They reported success rates 70% and 65% at 1 year and 60% and 55% at 2 years after Ahmed valve and trabeculectomy, respectively.

The higher success rates that we have seen in the present study could be attributed to incorporating anti-VEGF and PRP as pretreatment in all our patients. While PRP is the standard method of eliminating VEGF through ablating the VEGF-producing ischemic retina, photocoagulation has no role in clearing up VEGF molecules already released in aqueous humor and vitreous prior to PRP. Anti-VEGF agents act to neutralize existing VEGF in addition to their ability to inhibit post-operative inflammation and fibroblast proliferation [27,28].

In the present study we experienced substantial regression of anterior segment neovascularization and minimal post-operative inflammation which we believe were decisive in inhibiting fibroblastic activity that would eventually induce scarring. In accordance with our findings, Wakabayashi *et al.* [29] demonstrated that intra-vitreous bevacizumab injection with or without PRP can effectively treat neovascularization and cause regression of iris and anterior chamber neovessels within days to weeks without damaging drainage structures of the eye.

Similarly, Ishibashi *et al.* [11] reported the angiographic features of anterior segment neovascularization following intra-vitreous avastin. These authors documented marked reduction of vascular permeability of iris and angle neovessels 4-6 days after injection.

In contrast, Kyoung Tak *et al.* [24] reported contradicting findings. In a retrospective case series comparing Ahmed valve with and without avastin for treating NVG, these authors found that avastin does not seem to improve the success rate of Ahmed valve procedures.

Regarding post-operative complications in the current study, 30% of patients in group 1 and 45% of patients in group 2 developed post-operative complications that were controlled medically within one week approximately. None of our patients developed serious ocular complications. We did not detect systemic vascular complications attributed to lucentis injection.

In comparison, Higashide *et al.* [30] conducted a retrospective review of 84 eyes of 70 patients with NVG who received avastin to treat anterior segment neovascularization. Though they did not report systemic side effects, 2 of their 70 patients developed central retinal artery occlusion approximately 3 days after injection. The authors specified that both patients had NVG secondary to ocular ischemic syndrome and recommended caution regarding the use of anti-VEGF in this clinical situation.

CONCLUSION

Pretreating patients with NVG using intra-vitreous ranibizumab (Lucentis) and PRP reverse the underlying pathology and halts VEGF-induced inflammatory reaction associated with surgery. Consequently, the success rate of glaucoma surgery improves. Ahmed valve implant and trabeculectomy with MMC appear to be equally effective in controlling IOP.

REFERENCES

1. Brown, G.C., L.E. Magargal, A. Schachat and H. Shah, 1984. Neovascular glaucoma. Etiologic considerations. *Ophthalmology*, 91(4): 315-320.
2. Kubota, T., A. Tawara, Y. Hata, A. Khalil and H. Inomata, 1996. Neovascular tissue in the intertrabecular spaces in eyes with neovascular glaucoma. *Br J Ophthalmol.*, 80: 750-754.
3. Fiedler, U., Y. Reiss, M. Scharpfenecker, V. Grunow, S. Koidl, G. Thurston, N.W. Gale, M. Witzernath, S. Rosseau, N. Suttorp, A. Sobke, M. Herrmann, K.T. Preissner, P. Vajkoczy and A.G. Hellmut, 2006. Angiopoietin-2 sensitizes endothelial cells to TNF- α and has a crucial role in the induction of inflammation. *Nature Medicine*, 12: 235-239.

4. Jonas, J.B., I. Kreissig and R.F. Degenring, 2003. Neovascular glaucoma treated by intravitreal triamcinolone acetate. *Acta Ophthalmol Scand*, 81: 540-541.
5. Hayreh, S.S., 2007. Neovascular glaucoma. *Prog Retina Eye Res.*, 26: 470-485.
6. Sivak-Callcott, J.A., D.M. O'Day, J.D. Gass and J.C. Tsai, 2001. Evidence-based recommendations for the diagnosis and treatment of neovascular glaucoma. *Ophthalmology*, 108(10): 1767-1776.
7. Hamanaka, T., N. Akabane, T. Yajima, T. Takahashi and A. Tanabi, 2001. Retinal ischemia and angle neovascularization in proliferative diabetic retinopathy. *Am. J. Ophthalmol.*, 132: 648-658.
8. Tripathi, R.C., J. Lixa, B.J. Tripathi, K. Chalam and A.P. Adamis, 1998. Increased level of vascular endothelial growth factor in aqueous humor of patients with neovascular glaucoma. *Ophthalmology*, 105: 232-237.
9. Chen, K.H., C.C. Wu, S. Roy, S.M. Lee and J.H. Liu, 1999. Increased interleukin-6 in aqueous humor of neovascular glaucoma. *Invest Ophthalmol Vis Sci.*, 40: 2627-2632.
10. Kohno, R.I., Y. Hata, Y. Mochizuki, R. Arita, S. Kawahara, T. Kita, M. Miyazaki, T. Hisatomi, Y. Ikeda, L.P. Aiello and T. Ishibashi, 2010. Histopathology of neovascular tissue from eyes with proliferative diabetic retinopathy after intravitreal bevacizumab injection. *Am. J. Ophthalmol.*, 150: 223-229.
11. Ishibashi, S., A. Tawara, R. Sohma, T. Kubota and N. Toh, 2010. Angiographic changes in iris and iridocorneal angle neovascularization after intravitreal bevcizumab injection. *Arch Ophthalmol.*, 128(12): 1539-1545.
12. Kotecha, A., A. Spratt, L. Ogunbowale, R. Dell'Omo, A. Kulkarni, C. Bunce and W.A. Franks, 2011. Intravitreal bevacizumab in refractory neovascular glaucoma. A prospective observational case series. *Arch Ophthalmol.*, 129(2): 145-50.
13. Murphy, R.P. and P.R. Egbert, 1979. Regression of iris neovascularization following panretinal photocoagulation. *Arch Ophthalmol.*, 97(4): 700-702.
14. Haverly, R.F., 2010. Surgical management of neovascular glaucoma. *Tech Ophthalmol.*, 8: 87-93.
15. Mietz, H., B. Raschka and G.K. Krieglstein, 1999. Risk factors for failure of trabeculectomies performed without antimetabolites. *Br J. Ophthalmol.*, 83: 814-821.
16. Hyung, S.M. and S.K. Kim, 2001. Mid-term effects of trabeculectomy with mitomycin C in neovascular glaucoma patients. *Korean J. Ophthalmol.*, 15: 98-106.
17. Al Obeidan, S.A., E.A. Osman, S.A. Al-Amro, D. Kangave and A.M. Abu El-Asrar, 2008. Full preoperative panretinal photocoagulation improves the outcome of trabeculectomy with mitomycin C for neovascular glaucoma. *Eur J. Ophthalmol.*, 18: 758-764.
18. The Central Vein Occlusion Study Group, 1995. A randomized clinical trial of early panretinal photocoagulation for ischemic central vein occlusion. The Central Vein Occlusion Study Group N Report. *Ophthalmology*, 102: 1434-1444.
19. Netland, P.A., 2009. The ahmed glaucoma valve in neovascular glaucoma. *Trans Am Ophthalmol Soc.*, 107: 325-342.
20. Sisto, D., M. Vertugno, T. Trabucco, F. Cantatore, G. Ruggeri and C. Sborgia, 2007. The role of antimetabolites in filtration surgery for neovascular glaucoma: intermediate-term follow-up. *Acta Ophthalmol Scand*, 85: 267 -271.
21. Khaw, P.T. and A. Wilkins, 2008. Antifibrotic agents in glaucoma surgery. In: Yanoff M, Duker JS, eds. *Ophthalmology*. 3rd ed. Philadelphia, PA: Mosby, pp: 1590-1591.
22. Pe'er, J., M. Neufeld, M. Baras, H. Gnessin, A. Itin and E. Keshet, 1997. Rubeosis iridis in retinoblastoma. Histological findings and the possible role of vascular endothelial growth factor in its induction. *Ophthalmology*, 104: 1251-1258.
23. Boyd, S.R., I. Zachary, U. Chakravarthy, G.J. Allen, G.B. Wisdom, I.A. Cree, J.F. Martin and P.G. Hykin, 2002. Correlation of increased vascular endothelial growth factor with neovascularization and permeability in ischemic central retinal vein occlusion. *Arch Ophthalmol.*, 120: 1644-1650.
24. Kyoung Tak, M., Y. Jong Yun, K. Ji Hyun, K. Na Rae, H. Samin, L. Eun Suk, S. Gong Je and K. Chan Yun, 2012. Surgical results of ahmed valve implantation with intraoperative bevacizumab injection in patients with neovascular glaucoma. *J Glaucoma*, 21(5): 331-336.
25. Mahdy, R.A., W.M. Nada, K.M. Fawzy, H.Y. Alnashar and S.M. Almosalamy, 2013. Efficacy of intravitreal bevacizumab with panretinal photocoagulation followed by ahmed valve implantation in neovascular glaucoma. *J. Glaucoma*, 22(9): 768-772.

26. Shen, C.C., S. Salim, H. Du and P.A. Netland, 2011. Trabeculectomy versus ahmed valve implantation in neovascular glaucoma. *Clin Ophthalmol*, 5: 281-286.
27. Kiuchi, Y., R. Sugimoto, K. Nakae, Y. Saito and S. Ito, 2006. Trabeculectomy with mitomycin C for treatment of neovascular glaucoma in diabetic patients. *Ophthalmologica*, 220: 383-388.
28. Li, Z., T. Van Bergen, S. Van de Veire, I. Van de Vel, H. Moreau, M. Dewerchin, P.C. Maudgal, T. Zeyen, W. Spileers, L. Moons and I. Stalmans, 2009. Inhibition of vascular endothelial growth factor reduces scar formation after glaucoma filtration surgery. *Invest Ophthalmol Vis Sci.*, 50: 5217-5225.
29. Wakabayashi, T., Y. Oshima, H. Sakaguchi, Y. Ikuno, A. Miki, F. Gomi, Y. Otori, M. Kamei, S. Kusaka and Y. Tao, 2008. Intravitreal bevacizumab to treat iris neovascularization and neovascular glaucoma secondary to ischemic retinal diseases in 41 consecutive cases. *Ophthalmology*, 115(9): 1571-1580.
30. Higashide, T., E. Murotani, Y. Saito, S. Ohkubo and K. Sugiyama, 2012. Adverse events associated with intraocular injections of bevacizumab in eyes with neovascular glaucoma. *Graefes Arch Clin Exp Ophthalmol.*, 250(4): 603-610.