

Ultrasound Diagnosis of Cholecystitis in a Dog. (A Case Report)

A. Aissi and C. Slimani

Surgery and Imaging Service, Veterinary Department, Faculty of Sciences, Batna University, Algeria

Abstract: The routine abdominal ultrasonography, in dogs is now being used for diagnosis of acute and chronic gallbladder diseases. Cholecystitis often leads to vague signs such as vomiting, fever and abdominal pain. The usual cause of cholecystitis is thought to be an ascending bacterial infection from gastrointestinal tract or from hematogenous bacteria. When cholecystitis becomes severe, gallbladder shows necrobiotic changes and even rupture may be occurred, with subsequent biliary peritonitis. Ultrasonography identifies increased gallbladder wall thickness and echogenicity; dilated, tortuous bile ducts; and concurrent cholelithiasis.

Key words: Dog • Ultrasonography • Cholecystitis • Diagnosis • Liver

INTRODUCTION

A three-year-old, male, crossbred dog was referred to the Batna University, Surgery and imaging service, for ultrasound diagnosis of a chronic liver problem. The dog was depressed with no appetite for one month. The dog had been treated for liver disease but the serum alanine aminotransferase (ALT) and alkaline phosphatase (ALP) remained at the high level (149-254 U/L and 1,056-1,810 U/L), respectively, over a period of three weeks. On the day prior to referral, ALT and ALP were 184 U/L and 2,710 U/L. The dog would not eat unless the owner fed her. On admission to the service, the dog was depressed and lethargic. Rectal temperature was 40,2. Abdominal radiographs were performed and a mild hepatomegaly was evident.

Ultrasonographic Findings: Ultrasonographic examination of the abdomen was performed using a real time scanner (Siemens) with a 5 MHz broadband, convex, phased array transducer. Sagittal and transverse scans of the hepatic parenchyma revealed a normal echogenicity (Fig. 1) which was slightly more echogenic compared to that of the cortex of the right kidney and hypoechoic to the head of the spleen. The gallbladder was oval in shape and anechoic in echogenicity with distal acoustic enhancement. The gallbladder wall was symmetrically thickened, about 4 mm. It appeared as a hypoechoic region between the two echogenic lines associated with gallbladder oedema. A small amount of echogenic sediment was present within the gall bladder. Other abdominal organs appeared normal.

Diagnosis: Ultrasonographic diagnosis: Gall bladder wall thickening (cholecystitis)

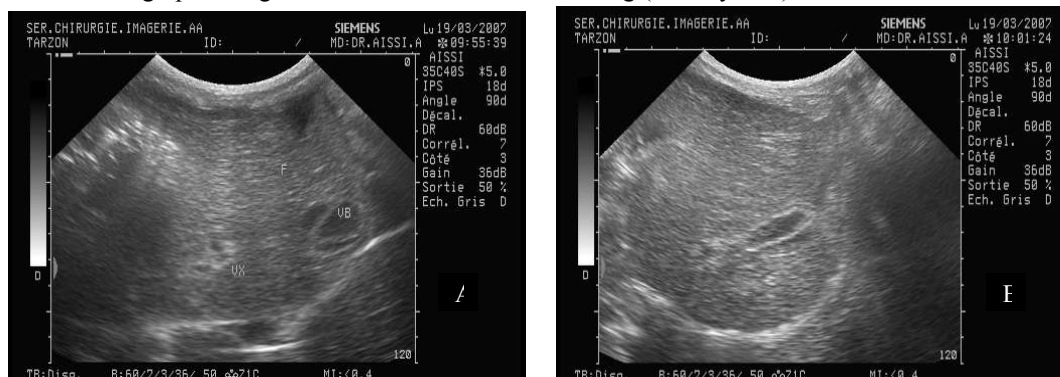


Fig. 1 (A and B): Sagittal and transverse scans of the hepatic parenchyma revealed a normal echogenicity; the gallbladder wall was symmetrically thickened with oedema

Corresponding Author: A. Aissi, Surgery and Imaging Service, Veterinary Department, Faculty of Sciences, Batna University, Algeria

DISCUSSION

The normal gallbladder is sonographically seen as an anechoic, smooth-marginated, round to oval structure within the liver, just to the right of the midline. Acoustic enhancement is commonly seen distal to the gallbladder. Slice thickness and sidelobe artifacts can be seen within the gallbladder lumen and can be minimized by changing the angle of the transducer and ultrasound beam or repositioning the patient. The size of the gallbladder varies with the fasting or fed condition of the patient. Echogenic sediment may be detected within the gallbladder but this finding does not correlate with disease in the dog or cat. Normally, the gallbladder wall is nonvisualized or poorly visualized as a thin echogenic line [1]. When the gallbladder wall becomes thickened from wall edema in inflammatory diseases, an echogenic double-rim effect is produced by reflections from the inner and outer walls. These two echogenic rims are separated by an intramural hypoechoic region. However, thickening of the gallbladder wall in man and in animals is a nonspecific pathologic finding. In dog, it has been identified in cases of acute or chronic hepatitis,

cholecystitis or cholangiohepatitis [1-2]. It can also be seen in association with other conditions such as sepsis and neoplasia [3-4]. Ultrasonically guided, percutaneous, liver biopsy and cholecystocentesis for cytological examination and culture of bile have been suggested as aids to determine the cause of gallbladder wall thickening.

REFERENCES

1. Nyland, T.G. and D.A. Hager, 1985. Sonography of the liver, gallbladder and spleen. *Vet. Clin. North Am. Small Anim. Pract.*, 15: 1123-1148.
2. Nyland, T.G. and R.D. Park, 1983. Hepatic ultrasonography in the dog. *Vet. Radiol.*, 24: 74-84.
3. Willard, M.D., R.W. Dunstan and J. Faulkner, 1988. Neuroendocrine carcinoma of the gallbladder in a dog. *J. Am. Vet. Med. Assoc.*, 192: 926-928.
4. Rivers, B.J., P.A. Walter, G.R. Johnston, L.K. Merkel, and R.M. Hardy, 1997. Acalculous cholecystitis in four canine cases: ultrasonographic findings and use of ultrasonographic-guided, percutaneous cholecystocentesis in diagnosis. *J. Am. Anim. Hosp. Assoc.*, 33: 207-214.