

## A Comparative Parasitological Study on Treatment of *Hymenolepis nana* among Immunocompetent and Immunocompromised Infected Mice

<sup>1</sup>Ahmed M.S. Bayoumy, <sup>2</sup>Basma, M. Abou El-Nour and <sup>3</sup>Eman Ali

<sup>1</sup>Department of Parasitology, Faculty of Medicine, Al Azhar University, Cairo, Egypt

<sup>2</sup>Department of Zoology, Faculty of Science (girls), Al Azhar University, Cairo, Egypt

<sup>3</sup>Department of Parasitology, Theodor Bilharz Research Institute, Imbaba, Giza, Egypt

**Abstract:** Hymenolepiasis is the most prevalent tapeworm infection of children worldwide. It is considered as an opportunistic parasite with a life-threatening effect among immunosuppressed patients, so it must be eliminated before initiating immunosuppressive therapy for fear of cysticercoid dissemination. Praziquantel is the drug of choice for the treatment of *H. nana* but it was found to be hepatotoxic, genotoxic and carcinogenic in albino rats. Mirazid (*commiphora molmol*) is considered as a new safe herbal and effective treatment of hymenolepiasis, which has side degree of prevalence and spreading not only in Egypt, but worldwide. The aim of the present work was to make a comparison between the effects of treatment with Praziquantel (PZQ) (standard treatment) and Mirazid among immunocompetent and immunocompromised infected albino mice through parasitological parameters (worm load and mortality rate). A total of 132 clean male albino mice were divided into two main groups (immunocompetent group) where 60 animals were divided into equal 5 groups which were infected and treated with Mirazid beside PZQ. Another 72 infected immunocompromised animals (injected by cortisone) were divided into equal six groups, were also treated with Mirazid and PZQ. At the end of experiment worms were extracted, counted, fixed and stained with carmine to evaluate the effect of the used drugs. Mortality rate in immunocompetent groups reached (16.60%) comparing to its control group (33.30%). While in immunocompromised groups it reached (25%&33.3%) comparing to its control group (50%). Both PZQ and Mirazid showed a significant reduction in the mean of worm burden comparing with infected non treated group in both main groups. The adult worms recovered from Mirazid and PZQ treated group showed many pathological changes. Mirazid showed higher cure rates than PZQ, 95.45% and 74.54% at 15<sup>th</sup> day and at 21<sup>st</sup> day it reached 100% respectively but Mirazid was found to give more changes in the morphology and decrease of adult worm biomass and number of eggs production.

**Key words:** *H. nana* • Mice • Praziquantel • Mirazid • Immunosuppression • Parasitological And Biochemical Parameters

### INTRODUCTION

*Hymenolepis nana* (dwarf tapeworm) is the most common human tapeworm infection, with an estimated 50 to 75 million carriers worldwide including Egypt particularly in immunocompromised patients [1,2]. It is a common parasite of children owing to the lack of fecal hygiene together with bad feeding habits [3].

Immunosuppression leads to delayed worm expulsion and allows the continuation of worms to maturity and chronic course of infection, resulting in hyperinfection of

the intestine by adult worms and invasion of the mesenteric lymph nodes and liver by oncospheres, where they develop into mature cysticercoids [4,5].

The parasite causes vague abdominal symptoms along with diarrhea, epigastric pain, nausea, vomiting, irritability, anaemia, anorexia, headache and weight loss as well as general weakness [6]. Also, Roberts & Janovy [2] reported that *H. nana* can cause restless sleep, pruritis ani, hives, extremity dizziness and behavioral disturbances as well as seizures. It has also negative impact on vitamin B12, folate level and anthropometric parameters [7].

Praziquantel is a broad-spectrum, anthelmintic drug against trematode and cestode infections in humans and animals. The precise mechanism of action of praziquantel is still poorly understood. There are also emerging problems with praziquantel treatment, which include the appearance of drug resistance [8], allergic, anaphylactic, or hypersensitivity reactions in some individuals [9,10].

Due to the increased demand for using plants in therapy "back to nature" instead of using synthetic drugs, which may have adverse effects more dangerous than the disease itself [11]. In addition, the emergence of parasitic resistance to current chemotherapies highlights the importance of plant essential oils as novel antiparasitic agents [12]. According to that Massoud *et al.* [13] reported that Mirazid (*Commiphora molmol*) is considered as a new safe and effective drug for treatment of human hymenolepiasis. They added that it has good clinical improvement with negligible side effects and has side degree of prevalence and spreading not only in Egypt, but world wide.

So this study aimed to make a comparison between the effects of treatment with praziquantel (standard treatment) and *Commiphora molmol* (mirazid) among immunocompetent and immunocompromised infected albino mice through parasitological parameters (worm burden and mortality rate).

## MATERIALS AND METHODS

**Experimental Design:** A total of 132 clean (non infected) male albino mice, weighing about 23 g, were purchased from Theodor Bilharz Research Institute and kept in separate cages at room temperature ( $25 \pm 2^\circ\text{C}$ ) in a light controlled room with an alternating 12 hour light/dark cycle. They were fed on standard rodent pellets and some vegetables as a source of vitamins. At the end of time of each group, all animals were sacrificed (at day 15 and 21 post infection) where mortality rate, worm load and worm morphology were evaluated.

Animals were divided into two main groups:

**Immunocompetent Group:** Included 60 immunocompetent healthy animals that were divided into equal 5 groups:

*Group A:* Mirazid treated group.

Infected and treated with mirazid orally in a dose of 10 mg/kg body weight for 6 days post infection according to Massoud *et al.* [13].

*Group B:* Mirazid control group.

Treated with mirazid orally in a dose of 10 mg/kg body weight for 6 days (Mirazid control).

*Group C:* Praziquantel treated group.

Infected and treated with praziquantel orally at the 10<sup>th</sup> day post infection in a dose of 25 mg/kg body weight one time according to Bhattacharya *et al.* [14].

*Group D:* Praziquantel control group.

Treated with praziquantel orally in a dose of 25 mg/kg body weight one time (praziquantel control).

*Group E:* Infected untreated control group.

Infected with 250 *H. nana* eggs orally /mouse (control group).

**Immunocompromised Group:** In which 72 immunocompromised animals were divided into equal six groups:

According to Medeiros *et al.* [15] the animals under immunocompromisation were injected subcutaneously with dexamethasone sodium phosphate in a dose of 8mg/kg body weight for 7 days to avoid edema or undesirable increase in body weight.

*Group F:* Cortisone control group.

Injected by dexamethasone sodium phosphate (cortisone control).

*Group G:* Cortisone and infected group.

Injected by dexamethasone sodium phosphate and infected with 250 *H.nana* eggs orally/mouse.

*Group H:* Cortisone, infected and mirazid treated group.

Injected by dexamethasone sodium phosphate, infected with 250 *H. nana* eggs orally/mouse and treated with mirazid orally in a dose of 10mg/kg body weight for 6 days post infection.

*Group I:* Cortisone and mirazid treated control group.

Injected by dexamethasone sodium phosphate and treated with mirazid orally in a dose of 10mg/kg body weight for 6 days post injection.

*Group J:* Cortisone, infected and praziquantel treated group.

Injected by dexamethasone sodium phosphate, infected with 250 *H. nana* eggs orally/mouse and treated with praziquantel orally in a dose of 25mg/kg body weight one time at 10<sup>th</sup> day post infection.

**Group K:** Cortisone and praziquantel control group.

Injected by dexamethasone sodium phosphate and treated with praziquantel orally in a dose of 25mg/kg body weight one time at 10<sup>th</sup> day post injection.

Infection of animals with (200 – 250 egg/mouse orally) was done according to Ito *et al.* [16].

**Collection of Worms (Worm Burden) Was Done According to Kumazawa [17]:** The infected animals were sacrificed at the end of each experiment by decapitation. To obtain the adult worms, the small intestine was removed and cut longitudinally very carefully in a Petri-dish containing saline solution and left for 1/2 hour in order to release the worms from the intestinal mucosa. All worms in the Petri-dish were collected; gravid segments which can be detected under the dissecting microscope were separated and collected in a beaker, then worms were collected, counted and washed thoroughly by sterile saline

**Worms Morphology:** The worms were collected, then washed thoroughly by sterile saline and stained with Semichon's acid carmine and examined under light microscope according to Garcia and Bruckner [18].

**Drugs:** Praziquantel is manufactured by Egyptian International Pharmaceutical Industries Company (EPICO). Its chemical formula is 2- cyclohexylcarbonyl 1,2,3,6,7 11b hexahydro- 4h- pyrazino- (2,1-a) Isoquinoline-4-one. According to Bhattacharya *et al.* [14] Praziquantel was given orally in a dose of (0.4/ml = 25 mg/kg) at the 10<sup>th</sup> day post infection.

The tablet was dissolved in 10% of dimethyle sulphoxide to obtain concentration of 25mg/kg.

**Mirazid: (Pharco, Egypt, Alexandria):** Mirazid was used in a dose of 10mg/kg and given orally at the first day of infection for 6 days daily before breakfast according to Massoud *et al.* [13].

**Dexamethasone Sodium Phosphate (Cortison):** Injection of dexamethasone sodium phosphate was done in a dose of 8mg/kg body weight (0.5mg/mouse for 7days) according to Medeiros *et al.* [15].

**Statistical Analysis:** Results were analyzed for statistical significance using t-test or analysis of variance (ANOVA). Statistical evaluation was conducted with SPSS version 15.0. Values of  $p < 0.05$  were regarded as significant.

## RESULTS

### Mortality Rate

**Among Immunocompetent Groups:** Mortality rate reached (16.60%) in groups (A, B, C&D) while it reached (33.30%) among group (E) (infected only), Table 1.

**Among Immunocompromised Groups:** Mortality rate reached (33.3%) in groups (F&J), while it reached (41.6%) in groups (I&K). It reached (50% &25%) in groups (G and H) respectively, Table 2.

### Worm Burden

**Among Immunocompetent Groups:** Table 3 and Figure 1 demonstrated comparison between worm burden among immunocompetent groups of mice. Scarification at 15<sup>th</sup> day after infection revealed that mirazid treated group (A) induced a highly significant decrease in worm burden ( $P \leq 0.001$ ) compared to control infected group (E). The percentage of decrease was 95.45%. Mice treated with PZQ after infection group (C) induced a highly significant decrease in worm load ( $P \leq 0.001$ ) compared to control group (E). The percentage of decrease was 94.54%, while at 21<sup>th</sup> day the percentage of decrease among immunocompetent groups (A&C) was 100% respectively. Worms were changed in length and became longer.

**Among Immunocompromised Groups:** Table 4 and Figure 2 showed a highly-significant reduction in worm number ( $P \leq 0.001$ ) in cortisone, infected and mirazid treated group (group H) in comparison with cortisone and infected group (G). The percentage of decrease was 15%. Also, cortisone, infected and PZQ treated group (J) recorded highly significant increase in worm number ( $P \leq 0.001$ ) in comparison with group (G) the percentage of increase was -68.49% at 15<sup>th</sup> day post infection. Group J recorded non-significant difference from control group at  $P > 0.05$ , also group H recorded non-significant increase  $P > 0.05$  at 21<sup>th</sup> day. Worms were increased in length compared to control group (G).

**Immunocompetent Groups:** Figs. (3 and 4): showed the effect of Mirazid on adult worms of *H. nana* (group A). Most of the extracted worms of this group showed malformation in the proglottids, loss of internal structures of the segments and less number of eggs. Degeneration of the gonads, rupture of the gravid proglottids as well as decrease of the width and constriction of the segments was also found.

Table 1: Mortality rate among immunocompetent groups.

Groups	No of mice	No of dead mice at the end of experiment	Mortality rate
Mirazid treated group (A)	12	2	16.6 %
Mirazid control group (B)	12	2	16.6 %
PZQ treated group (C)	12	2	16.6 %
PZQ control group (D)	12	2	16.6 %
Infected nontreated control group (E)	12	4	33.3 %

Table 2: Mortality rate among immunocompromised groups

Groups	No of mice	No of dead mice at the end of experiment	Mortality rate
Cortisone control group (F)	12	4	33.3 %
Cortisone infected group (G)	12	6	50 %
Cortisone infected and mirazid treated group (H)	12	3	25 %
Cortisone and mirazid treated control group (I)	12	5	41.6 %
Cortisone infected and PZQ treated group (J)	12	4	33.3 %
Cortisone and PZQ treated control group (K)	12	5	41.6 %

Table 3: Worm burden and worm length among different infected immunocompetent groups.

		Group A (mirazid treated)					Group C (praziquantel treated)					Group E (infected untreated)			
Time of scarification	Mice (No)	1	2	3	4	5	1	2	3	4	5	1	2	3	4
15 <sup>th</sup> day	Worm load (No)	1	1	0	0	0	2	5	0	0	0	5	6	7	4
	Mean	0.25***					1.40***					5.5			
	S.D.	0.50					2.19					1.29			
	P	<0.001					<0.001								
	Worm length (cm)	2	3	-	-	-	1-2	4-5	-	-	-	1-3	1-3	1-3	1-3
21 <sup>th</sup> day	Worm burden (No)	0	0	0	0	0	0	0	0	0	0	12	14	13	11
	Mean	0.00***					0.00***					12.5			
	S.D.	0.00					0.00					1.53			
	P.	≤0.001					≤0.001								
	Worm length (cm)	-	-	-	-	-	-	-	-	-	-	3-4	3-4	3-4	3-4

(\*\*\*) Significantly different from control group at  $P \leq 0.001$

Table 4: Worm burden and worm length among different infected immunocompromised by cortisone groups

		Group H (mirazid treated)					Group J (praziquantel treated)					Group G (infected untreated)		
Time of scarification	Mice (No)	1	2	3	4	5	1	2	3	4	5	1	2	3
15 <sup>th</sup> day	Worm burden(No)	23	25	22	24	22	40	48	55	41	-	32	25	25
	Mean	23.20***					46***					27.3		
	S.D.	1.30					6.98					0.00		
	P.	<0.001					<0.001					--		
	Worm length (cm)	2-3	2-3	2-3	2-3	2-3	4	3	4	4	-	4	3	4
21 <sup>th</sup> day	Worm burden (No)	23	25	26	30	-	43	65	34	29	-	40	45	50
	Mean	26 a					42.75 a					45		
	S.D.	2.94					15.92					0.00		
	P.	>0.05					>0.05					--		
	Worm length (cm)	2-3	2-3	2-3	2-3	-	3-4	4-5	4-5	4-5	-	3-4	4-5	4-5

(\*\*\*) Significantly different from control group at  $P \leq 0.001$  (a) Non-significant  $P \geq 0.05$

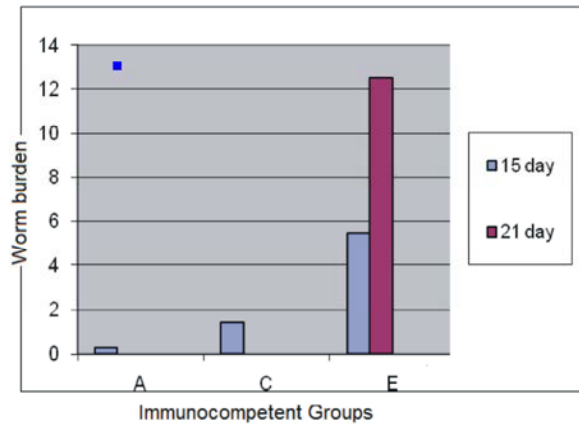


Fig. 1: A diagrammatic presentation of worm burden among immunocompetent groups

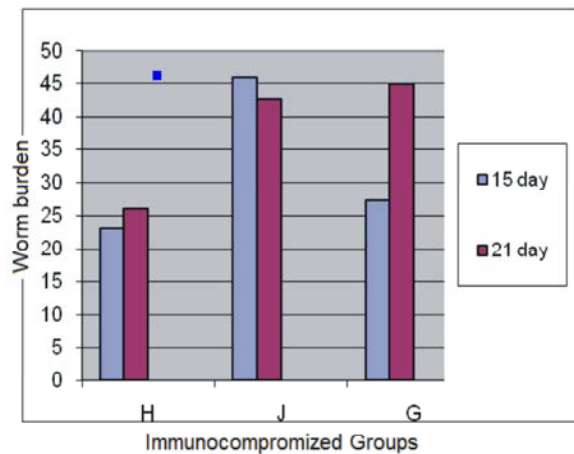


Fig. 2: A diagrammatic presentation of worm burden among immunocompromised groups

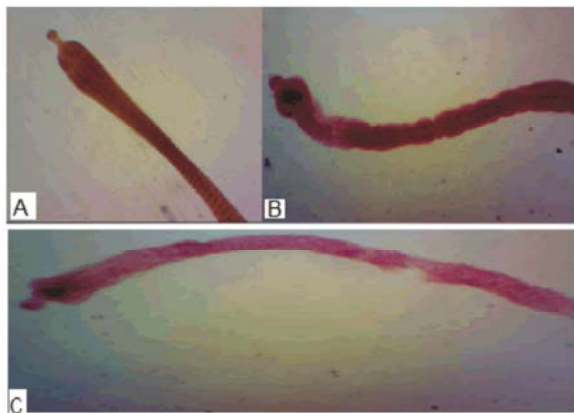


Fig. 3: A- Normal appearance of scolex and segment (X70)  
B- Malformation of scolex in group A (Mirazid treated group) (X70)  
C- Malformation, elongation of the worm and rupture of segments in group C (Praziquantel treated group) (X70)

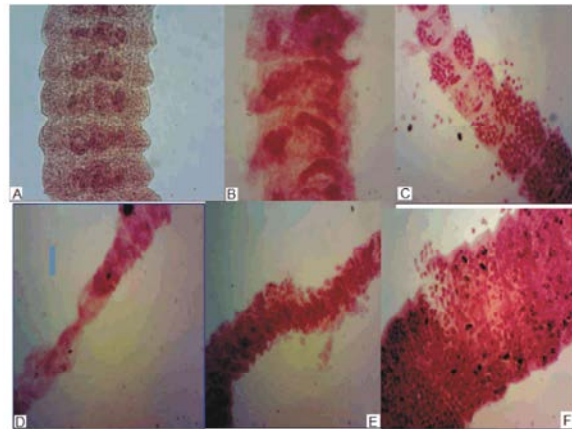


Fig. 4: A- Normal mature segments (X100)

B&E degenerated mature segments and loss of internal structures among group A (Mirazid treated) (X100)

C- Malformation and ruptured segments associated with less number of eggs among group A (Mirazid treated) (X100)

D- Malformed segments associated with loss of internal structure and deformity of the lateral margins in group C (Praziquantel treated) (X100).

F- Ruptured gravid segments among group C (Praziquantel treated) (X100)

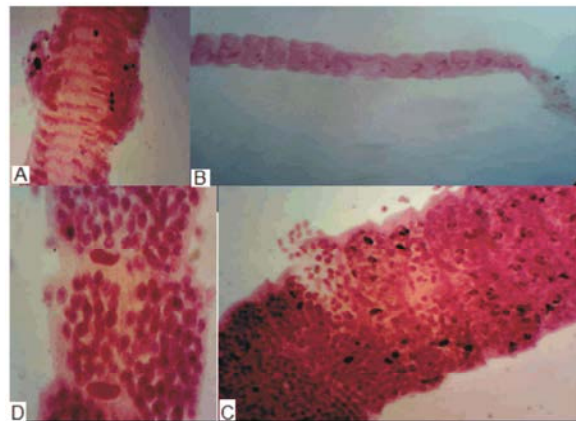


Fig. 5: Shows the effect of combined cortisone and mirazid treatment group (H) as well as praziquantel treatment group (J) on infected mice.

A-Malformation of mature segments among group H (immunocompromised mirazid treated group) (X100).

B- Malformation of mature segments among group J (immunocompromised Praziquantel treated) (X70).

C- Malformation of gravid segments among group H (immunocompromised D- Malformation of gravid segments among group J (immunocompromised PZQ treated group (X100

The effect of praziquantel on adult *H. nana* (group C) led to elongation and malformation of worms. Also rupture and constriction of the segments as well as loss of internal organs and deformity of the lateral margins were found.

**Immunocompromised Groups:** In immunocompromised infected group (G) some of the extracted worms were freely present in the lumen (not attached to the wall of small intestine). Some showed normal formation while the others showed malformation in mature and gravid segments.

Fig. 5 showed the effect of combined cortisone and mirazid treatment group (H) as well as praziquantel treatment group (J) on adult *H. nana*. Some of the extracted worms showed malformation in the scolex, immature, mature and gravid segments.

## DISCUSSION

*H. nana* is known to be one of the most common intestinal parasites affecting children in Egypt with maximum incidence between five and ten years [19] probably because their immunological status and hygiene practices are still in development [20-22]. It was estimated that over 43.5 million persons throughout the world were infected [23]. In Egypt, many authors reported different prevalence rate of infection with *H. nana* reached to 20.1 % [13 & 19]. Throughout the last years, *H. nana* was being considered as an opportunistic parasite with a life-threatening effect among immunosuppressed patients [5,24], thus hymenolepiasis should be eliminated before initiating immunosuppressive therapy for fear of cysticercoids dissemination and persistence of infection through autoinfection which led to prolonged infection duration [25]. Praziquantel was the drug of choice for the treatment of *H. nana* [8, 26] but cuse of the tapeworm's relative resistance to chemotherapy and the potential tendency for autoinfection, also it was found hepatotoxic, genotoxic and carcinogenic in albino rats [27]. So the patient should receive another course of treatment [14]. Mirazid (*commiphora molmol*) is considered as a new safe and effective herbal treatment of hymenolepiasis, which has side degree of prevalence and spreading not only in Egypt, but world wide [13].

In the present work, the effect of Mirazid on infected mice with *H. nana* was studied through estimation of parasitological parameters (mortality rate, worm burden and worm morphology). They were divided

into two groups, immunocompetent and immunocompromised to make a comparison between the effect of treatment with praziquantel (standard treatment) and *Commiphora molmol* (new herbal treatment) among both groups.

Mirazid was used in a dose of 10 mg/kg [13] given orally at the first day of infection for 6 days daily in empty stomach while praziquantel was used in a dose of 25mg/kg and was given orally for mice at the 10<sup>th</sup> day of infection [28]. According to Medeiros *et al.* [15] the animals under immunocompromisation were injected subcutaneously with dexamethasone sodium phosphate in a dose of 8mg/kg body weight for 7 days to avoid edema or undesirable increase in body weight. Regarding mortality rate among immunocompetent groups, it reached (16.60%) in groups (A, B, C&D) while it reached (33.30%) among group (E) (infected only). While mortality rate among immunocompromised groups, it reached (33.3%) in group (F&J), while it reached (41.6%) in group (I&K). It reached (50% & 25%) in group (G and H) respectively, the data is coincided with [13,29&30]. Regarding worm burden there was a decrease in number of worms in treated animals with Mirazid compared to infected untreated control group (group E). The data is coincided with [13, 29, 30].

Praziquantel is a broad-spectrum, anthelmintic against trematode and cestode infections in humans and animals. [8].

In this study, both PZQ (group C) and mirazid (group A) showed a highly significant reduction ( $P < 0.001$ ) in the mean number of worm in comparison with infected untreated control group.

Depending on worm burden at 15<sup>th</sup> day after infection, the protection level of Mirazid in immunocompetent group (A) reached 95.45% which agreed with Massoud *et al.* [13, 31] who reported that parasitological cure rate was 95.2% for *H. nana* infection. Also Massoud *et al.* [32] in Egypt carried out a field study for efficacy and safety of Mirazid in *H. nana* treatment and found that the parasitological cure rate reached 98% a week post-treatment and 100% 2, 3&4 weeks follow-up. Mice treated with PZQ 15<sup>th</sup> day after infection group (C) induced a highly significant decrease in worm burden ( $P \leq 0.001$ ) compared to control group (E). The percentage of decrease was 94.54% which coincided with that obtained by Botros *et al.* [33, 34]. At 21<sup>st</sup> day, the percentage of decrease among both immunocompetent groups (A&C) was 100% respectively and worms were changed in length and became longer.

Regarding morphological changes in the adult worms, there were some degree of worm elongation and abnormality in gravid segments of the worms when using praziquantel which coincided with that obtained by [35,36]. The adult worms recovered in Mirazid treated group showed many pathological changes such as attenuation of the segments, constrictions of the worms, degeneration and loss of the internal organs, decreased egg development in gravid segments as well as formation of cuticle, swellings, shrinkage and deformity of the lateral margin of the worms which agreed with [5, 37].

Regarding worm burden in immunocompromised groups, the data revealed significant correlation ( $P<0.05$ ) between groups G and H after 15<sup>th</sup> and 21<sup>st</sup> day of infection, which coincided with Lucas *et al.* [38] and El-Shafey [36]. There was non-significant reduction of the mean of worm number ( $P>0.05$ ) after 15<sup>th</sup> and 21<sup>st</sup> day of infection, in groups (H and J). Also at the 21<sup>st</sup> day post infection there was non-significant reduction of the mean of worm number ( $P<0.05$ ) in comparison with cortisone and infected, non treated group.

In addition, the cuticle of the worm was exposed to severe destruction in the form of extensive swelling, erosion, vacuolization and peeling which results in exposure of the worm surface antigen leading to attraction of inflammatory cells like neutrophils and eosinophils which attack the worms [39,40]. Worm expulsion in those groups can be explained by excessive production of mucus which traps the worms (due to cortisone) where the worms have to utilize more energy to break the sticky mucin to move into a more desirable region of the intestine. This reflects the decreased biomass of worms where goblet cells and mucin secretion are higher [41,42]. The resulted data coincided with Sanad and Al-Furayhi [5]. They showed significant increase in infection intensity, significant decrease in intestinal mast cell count, dissemination of larvae to the liver, toxic hepatitis, morphological, abnormalities in adult worms, prolongation of patent period and more severe villous changes by using cortisone.

In conclusion Mirazid was found to change the morphology and decrease adult worm biomass and the number of eggs produced than PZQ.

## REFERENCES

1. El Gammal, N., S.A. El-hAl, F.H. Osman, S. Salem and S. Mostafa, 1995. Comparative study of parasitic infections among school children in two rural areas in Upper (*Demo village*) and Lower Egypt (Malames village). Egypt. J. Commu. Med., 13(1): 25-30.
2. Roberts, L.S. and J. Janovy, 2005. Tapeworms. In: Roberts, L.S. and Janovy, J. (ed) Foundations of Parasitology. (7th Ed.), McGraw-Hill, New York. USA, pp: 354-356.
3. Mirdha, B.R. and J.C. Samantray, 2002. Hymenolepis nana: a common cause of paediatric diarrhea in urban slum dwellers in India. J. Trop. Paediatr., 48: 331.
4. Ito, A., 1985. Thymus dependency of induced immune responses against Hymenolepis nana (cestode) using congenitally athymic nude mice. Elin. Exp. Immunol., 60: 87-94.
5. Sanad, M.M. and L.M. Al Furayhi, 2006. Effect of some imunomodulators on the host-parasite system in experimental Hymenolepis nana. Egypt. J. Med. Sci., 36(1): 65-80.
6. Strickland, G.T., 2000. Hunter's Tropical Medicine and Emerging Infectious Diseases. 8<sup>th</sup> ed. W.B. Saunders Company: Philadelphia, London, Toronto, Montreal, Sydney, Tokyo.
7. Mohamed, M.A. and M.A. Hegazi, 2007. Intestinal permeability in Hymenolepis nana as reflected by non invasive lactulose/mannitol dual permeability test and its impaction on nutritional parameters of patients. J. Egypt Soc. Parasitol., 37(3): 1-16.
8. Chai, J.Y., 2013. Praziquantel treatment in trematode and cestode infections: Anupdate. Infection & Chemotherapy, 45(1): 32-43.
9. Kyung, S.Y., Y.K. Cho, Y.J. Kim, J.W. Park, S.H. Jeong, J.I. Lee, Y.M. Sung and S.P. Lee, 2011. A paragonimiasis patient with allergic reaction to praziquantel and resistance to triclabendazole: successful treatment after desensitization to praziquantel. Korean J. Parasitol., 49: 73-7.
10. Lee, J.M., H.S. Lim and S.T. Hong, 2011. Hypersensitive reaction to praziquantel in a clonorchiasis patient. Korean J. Parasitol., 49: 273-5.
11. Mady, N.I., A.F. Allam and A.I. Salem, 2001. Evaluation of the addition of Nigella sativa oil to triclabendazole therapy in the treatment of human fascioliasis. J. Egypt. Pharmacol. Exp. Ther., 20: 807-827.
12. Etewa, S.E. and S.M. Abaza, 2011. Herbal medicine and parasitic diseases. P.U.J., 4(1): 3-14.
13. Massoud, A.M., A.M. El-Shazly, S.A. Shahat and T.A. Morsy, 2007. Mirazid in treatment of human hymenolepiasis. J. Egypt. Soc. Parasitol., 37(3): 863-876.
14. Bhattacharya, S., C.K. Roy, S. Das, P. Goswami, J. Mondal and D.P. Ghosal, 2003. A case of disseminated hydatidosis. J. Indian. Med. Assoc., 101(11): 672-674.

15. Medeiros, C.S., N.T. Pontes-Filho, C.A. Camara, J.V. Lima-Filho, P.C. Oliveira, S.A. Lemos, A.F.G.K. Leal, J.O.C. Brandao and R.P. Neves, 2010. Antifungal activity of the naphthoquinone betalaphone against disseminated infection with *Cryptococcus neoformans* var. *neoformans* in dexamethasone – immunosuppressed swiss mice. Brazilian journal of Medical and Biological Research, 43: 345-349.
16. Ito, A., H. Onitake, J. Sasaki and T. Takami, 1991. *Hymenolepis nana*: Immunity against oncosphere challenge in mice previously given viable oncospheres of *Hymenolepis nana*, *Hymenolepis diminuta*, *Hymenolepis microstoma* and *Taenia taeniformis*. Int. J. Parasitol., 21: 241-245.
17. Kumazawa, H., 1992. A kinetic study of egg production, fecal egg output and the rate of proglottid shedding in *Hymenolepis nana*. J. Parasitol., 78: 498-504.
18. Garcia, L.S. and D.A. Bruckner, 1997. Fixation and special preparation of fecal parasite specimens and arthropods. In: Garcia, L.S. and Bruckner, D.A. (Eds.), Diagnostic Parasitology (3<sup>rd</sup> Ed). ASM Press, Washington, D.C., pp: 735-740.
19. El-Sherbini, G.T. and M.M. Abosedra, 2013. Risk factor associated with intestinal parasitic infections among children. J. Egypt. Soc. Parasitol., 43(1): 287-194.
20. Willms, K. and J. Sotelo, 2001. Cestodes. In: Gillespie, S. & Pearson, R. D. (eds.), Principles and Practice of Clinical Parasitology (1st Ed.), John Wiley & Sons Ltd, USA, pp: 627-629.
21. Muniz, P.T., T.G. De Castro, T.S. De Araújo, N.B. Nunes, M. Da Silva-Nunes, E.H. Hoffmann, M.U. Ferreira and M.A. Cardoso, 2007. Child health and nutrition in the Western Brazilian Amazon: population-based surveys in two counties in Acre State. Cad. Saúde Pública, 23(1): 1283-1293.
22. Pinheiro, I.O., M.F. De Castro, A. Mitterofhe, F.A. Condé Pires, C. Abramo, C.L. Ribeiro, S.H. Tibiriçá and E.S. Coimbra, 2011. Prevalence and risk factors for giardiasis and soil-transmitted helminthiasis in three municipalities of Southeastern Minas Gerais State, Brazil. Parasitol. Res., 108: 1123-1130.
23. Heelan, J.S., 2004. Cases in human parasitology. ASM, Prees. Washington, DC., pp: 165.
24. Gupta, A., B.K. Upadhyay, A. Khaira, D. Bhowmik and S.C. Tiwari, 2009. Chronic diarrhea caused by *Hymenolepis nana* in a renal transplant recipient. Clin. Exp. Nephrol., 13(2): 185-186.
25. Raether, W. and H. Hänel, 2003. Epidemiology, clinical manifestations and diagnosis of zoonotic cestode infections: an update. Parasitol. Res., 91(5): 412-438.
26. Cioli, D. and L. Pica-Mattoccia, 2003. Praziquantel. Parasitol. Res., 90: 3-9.
27. Omar, A.M., G.E. El-Mesallamy and S.H. Eassa, 2005. Comparative study of the hepatotoxic, genotoxic and carcinogenic effects of praziquantel (distocide) and the natural myrrh extract (Mirazid) on adult male albino rats. J. Egypt. Soc. Parasitol., 35(1): 313-328.
28. Andrews, P., H. Thomas, R. Pohlke and J. Seubert, 1983. Praziquantel. Medl Res. Rev., 3: 147-200.
29. Massoud, A.M., E.T. El-Sherbini, N.M.K. Saleh, M.F. Abou El-Nour and A.T.A. Morsy, 2010. Mirazid treatment of three zoonotic trematodes in Beni Swif and Dakhalia governorates. J. Egypt. Soc. Parasitol., 40(1): 119-134.
30. Beshay, E.V., 2012. Evaluation of effects of *Nigella sativa* (Black seeds) on histopathological, immunological and apoptotic changes in experimental *Hymenolepiasis nana*. Ph.D. Thesis, Faculty of Medicine, Menoufiya University. Egypt.
31. Massoud, A.M., M.M. El-Kholy, F.A. El-Shennawy and R.E. Farag, 2004. Study of some immune aspects in patients with fascioliasis before and after *Commiphora molmol* (Mirazid) treatment. J. Egypt. Soc. Parasitol., 34(1): 315-332.
32. Massoud, A.M., S.M. Motawea, A. El-Gilany, A. El-Shazly, A. Sitten and M. Gaballah, 2001. Mirazid, a new herbal treatment highly effective against intestinal nematodes. A study carried out under field conditions in rural Egypt. J. Environ. Sci., 21(5): 121-138.
33. Botros, S., H. Sayed, H. El-Dusoki, H. Sabry, I. Rabie, M. El-Gannam, M. Hassanein, Y. Abd El-Wahab and D. Engels, 2005. Efficacy of mirazid in comparison with praziquantel in Egyptian *S.mansoni* infected school children and households. Am. J. Trop. Med. Hyg., 72(2): 119-123.
34. El Sobky, M.M. and H.M. El Mazar, 2004. The efficacy of nitazoxanide as a new promising antiparasitic drug on experimental *Hymenolepis nana* infection. Egypt. J. Med. Sci., 25(1): 87-99.
35. Campos, A.E., H. Muller and H.G. Haley, 1984. Activity of praziquantel against *Hymenolepis nana* at different developmental stages, in experimentally infected mice. Rev. Inst. Med. Trop. Soapaulo, 26(6): 334-340.



36. El-Shaffey, O.K., 1992. Parasitic infections among primary school children in Menofia Governorate with special studies on *Hymenolepis nana*. M.SC. Thesis, Faculty of medicine. Cairo University. Egypt.
37. Massoud, A.M., H.A. Shalaby, R.M. El Khateeb, M.S. Mahmoud and M.A. Kutkat, 2013. Tegumental histological effects of Mirazid and myrrh volatile oil on adult *Fasciola gigantica*. *Asian Pac. J. Trop Biomed.*, 3(6): 501-504.
38. Lucas, S.B., O. Hassounah, R. Muller and M.J. Doenhoff, 1980. Abnormal development of *H.nana* in immunosuppressed mice. *J. Helminth.*, 54: 7-82.
39. Doenhoff, M.J., D. Cioli and J. Utzinger, 2008. Praziquantel: mechanisms of action, resistance and new derivatives for schistosomiasis. *Curr. Opin. Infect. Dis.*, 21(6): 659-667.
40. Elliott, A.M., J. Ndibazza, H. Mpairwe, L. Muhangi, E.L. Webb, D. Kizito, P. Mawa, R. Twayongyere and M. Muwanga, 2011. Treatment with anthelmintics during pregnancy: what gains and what risks for the mother and child?. *Parasitology*, 138(12): 1499-1507.
41. Ohyama, M., T. Otake, S. Adachi, T. Kobayashi and K. Morinaga, 2007. A comparison of the production of reactive oxygen species by suspended particulate matter and diesel exhaust particles with macrophages. *Inhal. Toxicol.*, 19(1): 157-160.
42. Webb, R.A., T. Hoque and S. Dimas, 2007. Expulsion of the gastrointestinal cestode, *Hymenolepis diminuta* by tolerant rats: evidence for mediation by a Th2 type immune enhanced goblet cell hyperplasia, increased mucin production and secretion. *Parasite Immunol.*, 29: 11-21.