

Zinc, Vitamin E and Selenium Oral Supplementation Reduces the Severity of Foot-and-Mouth Disease Clinical Signs in Sheep

*M.K. EL-Bayoumy, K.A. Abdelrahman,
T.K. Farag, A.M. Allam and Hala A.A. Abou-Zeina*

Department of Parasitology and Animal Diseases, National Research Center, Giza, Egypt

Abstract: The study was carried out to investigate the effect of multi-nutrient antioxidants (zinc, Vitamin E and Selenium) administration on the clinical signs and immunological alterations in sheep infected with Foot-and-mouth disease (FMD) during the outbreak of 2012 in Egypt. To conduct this work, twenty sheep showing typical symptoms of FMD infection raised in a private farm at Beni-Suef Governorate were selected; they were not previously vaccinated against FMD virus. Animals were divided into four equal groups treated with different therapeutic protocols and the study was run for eight weeks, group A was treated with symptomatic treatment against clinical signs of FMD; while group B was treated orally with multi-nutrient antioxidants [zinc methionine (Zn-Met) and Vitamin E with Selenium enriched yeast], group C was treated with the symptomatic treatment and multi-nutrient antioxidants together and group D was left without treatment and kept as control group. Sera were collected for detection of FMD infection and evaluation of antibody titers using 3ABC indirect ELISA while virus shedding was detected for eight weeks in different groups in oral epithelial swabs using reverse transcription polymerase chainreaction (RT-PCR). Results revealed differences in term of healing of lesions between the four groups and the clinical signs were quite prompt among sheep in group C which received zinc, Vitamin E and Selenium with the symptomatic treatment of the FMD than other three groups, so its use as an antioxidants supplementation could be used to enhance the reduction and treatment of clinical signs of FMD infection in sheep, although it had no effect on humeral immunity nor viral shedding.

Key words: Antioxidants • FMD • RT-PCR • ELISA and Sheep

INTRODUCTION

Foot-and-mouth disease (FMD) is the most contagious disease of mammals causing severe economic loss in susceptible cloven-hoofed animals (OIE, 2009) [1]. The natural route of infection is via the upper respiratory tract and the initial virus replication usually occurs in the pharyngeal epithelium resulting in viremia, primary vesicles and fever. Viremia occurs within 1-2 days resulting in virus excretion from the respiratory tract, feces, urine, saliva, milk and semen. The virus enters the blood then disseminates to various predilection sites such as mouse, nose, hooves and also sometimes udder and teats. Secondary vesicles occur and from which further virus are released [2]. The susceptibility of sheep to FMD

may vary with the breed of animal and strain of virus [3], sheep may play an important role in spreading of FMD virus (FMDV) by harboring acute infection without manifesting substantial clinical signs of disease, all of the most recent outbreaks of FMD within and around the European Union member states have involved sheep [4-7] and in North Africa, a definite predilection for sheep has been reported [8]. Sheep have generally been neglected with regard to their epidemiological role in the spread of FMD [9]. The FMD outbreaks in Egypt were officially reported by the OIE on March 2012, the affected species include cattle, buffalo and sheep, where young buffaloes appeared to be the category of animals more severely affected [10]. Livestock census data in Egypt estimate 7.5 million heads of small ruminants are at risk according to FAO [11].

Corresponding Author: M.K. EL-Bayoumy, Department of Parasitology and Animal Diseases, National Research Center, Giza, Egypt.

Certain nutrients such as vitamin E (Vit E), selenium (Se) and zinc (Zn) are common antioxidants normally included in animal's diet. These elements improve different functions of the immune system and exhibit important protective role during bacterial and viral infections as well as parasitic infestations [12]. As a result, dietary antioxidants modulate the host susceptibility or resistance to infectious pathogens [13, 14]. Combinations of antioxidants may be more effective than any single one [15, 16]. Interestingly, high concentrations of such nutrients in the diet above the predicted requirements will prevent protein and lipid oxidation and improve immune functions in ruminants [17]. There is evidence that nutritionally induced-oxidative stress status of the host can have a profound influence on virus, so that a normally avirulent virus becomes virulent because of changes in the viral genome [18].

The current study was carried out to investigate the effect of oral supplementation of zinc, Vitamin E and Selenium with or without the symptomatic treatment on the clinical signs and antibody titer in sheep infected with FMD, besides reverse transcription-PCR (RT-PCR) was performed for confirmation of infection with FMDV and to detect its shedding in oral epithelium throughout the experimental time.

MATERIALS AND METHOD

Humane Care and Use of Animals: All animals were housed and operated in accordance with applicable local laws, regulations, policies and guidelines of National Research Center (Giza-Egypt).

Animals and Clinical Signs Scoring: This work was conducted during the FMD outbreak recorded between March to May 2012 on twenty local breed (Osseimi) sheep not vaccinated against FMD, they were raised in a private farm (541 heads) at Beni-Suef Governorate-Egypt. Some animals in the flock showed typical clinical signs of FMD infection (pyrexia, lameness and/or oral lesions) the morbidity rate was approximately about 20% (n=108) and no mortality was recorded during the experiment duration (8 weeks).

Sheep were monitored daily for typical clinical symptoms of throughout the experimental period, they were also examined clinically for abnormal findings, pulse and respiratory rates as previously described [19].

Clinical score of 1 to 5 was assigned to describe the severity of the disease according to Eva Perez-Martin [20]; score of 1 was assigned when one or more vesicular

lesions were detected in one foot, score of 2 was assigned if two feet had vesicular lesions, score of 3 was assigned if three feet had vesicular lesions, etc. an additional score of 1 was assigned if lesions were found in the mouth. For evaluation of zinc, Vitamin E and Selenium effects, clinical signs were scored for each animal every two days until complete clinical cure of lesions are obvious.

Experiment Groups and Treatment Protocols: Sheep showing typical clinical symptoms of FMD with score "3" were chosen for conducting this work. They were divided into 4 equal groups (n=5) and undertaken different therapeutic protocols for 8 weeks. Group A treated with antipyretic and analgesic medicine (Vetalgin-Intervet) and a broad-spectrum, long-acting antibiotic (Terramycin/LA-Pfizer) and neither protective dressing nor immunomodulator was applied. Group B was supplied with multi-nutrient antioxidants only which is Zinc methionine (Zn-Met/10 Zinc chelated with methionine hydroxy analogue – IBEX International) and Vit E with Se enriched yeast (E 60.000, Sanovet, Austria – Composition: Vit E 60g, Se yeast 12g, L-lysine 0.08g and carrier: dextrose up to 1 kg). Both supplements were administered orally at level of 5 g/head/day. Group C was treated with multi-nutrient antioxidants, antipyretic and analgesic medicine (Vetalgin-Intervet) and broad-spectrum, long-acting antibiotic as previously used at both groups A and B. Group D was kept without treatment as a control group.

Detection of Nonstructural Protein 3ABC by ELISA: Blood samples from each animal were collected every 4 weeks for two months (Sixty serum samples) and stored at -80°C according to Edwards *et al.* [21]. Serum samples were used to monitor antibody against nonstructural polyprotein (NSP) 3ABC of FMD antigen using ELISA (IDEXX FMD 3ABC Ab Test Kit), it was performed in accordance to the manufacturers' instructions. According to the ELISA test kit manual, samples with percentage values >30% were considered positive, <20% as negative and samples between 20% and 30% were considered suspicious.

Detection of FMD Virus by Reverse Transcription PCR (RT-PCR): Collection and transportation of specimens were applied according to Kitching and Donaldson [22]. Oral epithelium swabs were collected weekly from clinically infected sheep of the four groups for detection of FMDV. Oral swabs were maintained in transport medium containing equal volumes of glycerol and phosphate-buffered saline (pH 7.2-7.6) containing 2%

Table 1: Oligonucleotide primers used for RT-PCR

Primer name	Primer sequence (5' to 3')	Region	Expected size (bp)
1F	GCC TGG TCT TTC CAG GTC T	5' UTR	328
1R	CCA GTC CCC TTC TCA GAT C	5' UTR	

antibiotic-antimycotic (BioWhittaker, Walkersville, MD). Viral RNA was extracted from 140 µL of each collected samples using a QIAamp Viral RNA Extraction Kit (QIAGEN, Germany) according to the manufacturers' protocol. The extracted RNA was subjected to RT-PCR using universal primers 1F/1R (Table 1) (10 pM for each) [23]. RT-PCR was performed using a "Thermo Scientific Verso 1-Step RT-PCR Reddy Mix Kit" with an initial 30-min incubation at 50 °C; followed by 95 °C for 15 min; 35 cycles at 94 °C for 30 s, 55 °C for 30 s and 72 °C for 90 s; and a final 10-min incubation at 72 °C. These validated 1F/1R primers generated a 328-bp product regardless of serotype.

The PCR results were then analyzed by gel electrophoresis according to the methods described by Ireland and Binopal [24].

RESULTS

Clinical Signs: Clinical symptoms started with high fever (42-43°C) which persisted for 3-4 days, lameness, anorexia, loss of general health condition and infected animals usually separate itself from the rest of the flock. About 20% (n=21) of infected sheep showed vesicles and/or ulcers on the dental pad and dorsum of the tongue.

Foot lesions along the coronary band and inter digital space was obvious for 2-3 weeks. Healing of lesions and completely disappearance of clinical signs was quiet prompt and fast among sheep of group C than group A by three to five days. Clinical signs in some animals of control group D lasted four to six days more than groups A and C, an overall improvement of the general health conditions and performance of sheep treated with antioxidants at group C were obvious. Comparing of mean values of the clinical signs of the four groups is illustrated in "Figure 1".

Detection of Nonstructural Protein 3ABC by ELISA: Results showed positive antibody titer against (NSP) 3ABC of FMD antigen in all infected animals at the start of the experiment which confirm the FMD infection and negative vaccination of sheep with any FMD vaccines. The mean antibody titers at the appearance of clinical signs were ranging from (6.6-12.4 %). After one month of treatment, results revealed high antibody titers with an average ELISA percent of (80.1-101.1%) and then it slightly declined after two months with an average percent of (70.1-88.7%). Comparing of antibody titers in the four groups showed no noticeable difference in titers percentage between groups as illustrated in Figure 2.

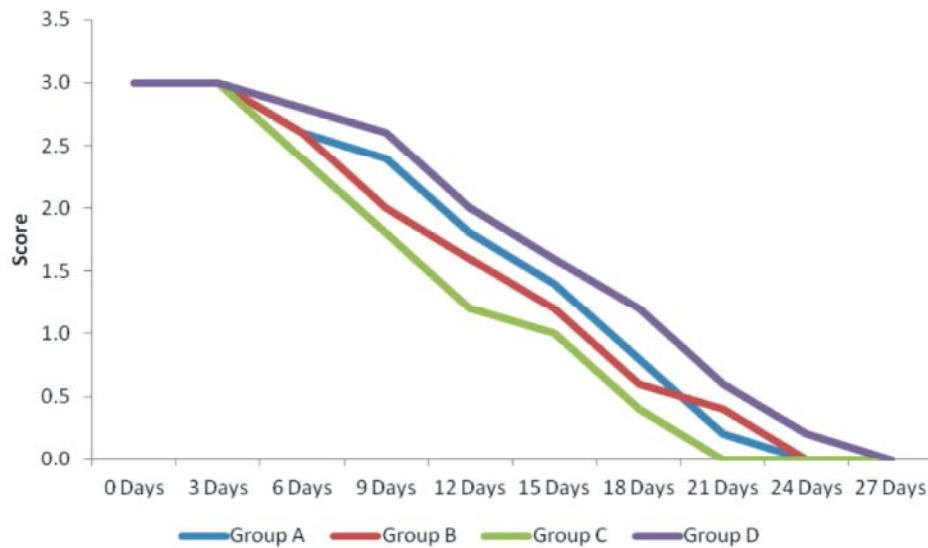


Fig. 1: Clinical signs mean scores of all groups

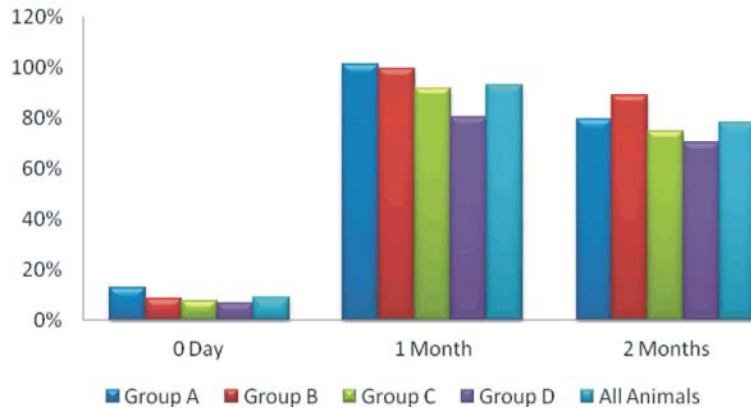


Fig. 2: Percentage of Antibody titer against FMD NSP-3ABC ELISA

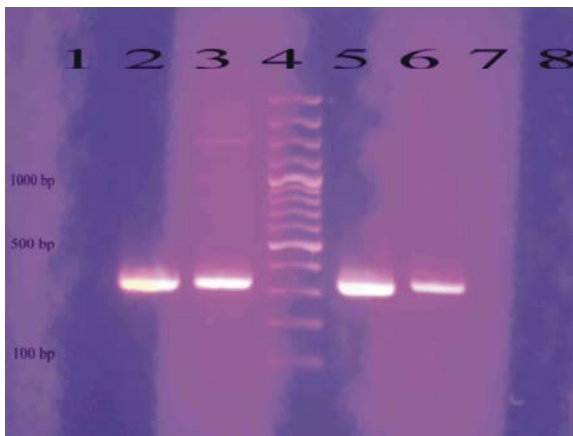


Photo 1: Detection of FMDV genome by RT-PCR using universal primers: Lane 1: negative specimen, lane 4: 100 bp DNA ladder, lanes 2, 3, 5 and 6: positive FMDV isolates (~328 bp)

Reverse Transcription PCR (RT-PCR) for Detection of FMDV: RT-PCR was run on the swabs collected from clinically infected animals for 8 weeks using the universal primers of FMDV. The amplification products showed positive results identified at the expected position of 328 bp as presented in (Photo 1).

DISCUSSION

Antioxidants play an important role in animals as modulators of the immune system and protectors against oxidative damages and are important for the proper function of body enzymes [25]. The dietary and tissue balance of antioxidant nutrients is important in protecting tissues against free radical damage. The antioxidant function could, at least in part, enhance immunity by

maintaining the structural and functional integrity of the important immune cells. A compromised immune system will result in reduced animal production efficiency through increased susceptibility to diseases, thereby leading to increased animal morbidity and mortality [26]. Certain nutrients such as vitamin E, Se and Zn are common antioxidants normally included in animal diet that improve different immune functions exhibiting an important protective role in infections caused by bacteria, viruses or parasites [12, 27, 28]. In the present study, the difference in the site, type, healing of lesion and progression of disease was observed between different treated groups, healing of lesions was quiet prompt and fast among sheep of Groups: B and C which received antioxidants alone "B" or with symptomatic treatment "C". There was obvious clinical improvement of the general health condition and performance of the affected animals observed after supplementation with antioxidants, these clinical findings were in concurrence with those previously stated [18, 29].

Sheep are highly susceptible to virus infection via aerosol and can excrete airborne virus; it may play an important role in spreading of FMD virus by harboring acute infection without manifesting substantial clinical signs of disease [30]. In our work, relevant significant clinical signs of FMD infection were obvious with lesions' score of 1-3 and morbidity rate of 20%, some animals had only high fever (42-43°C) without developing any mouth or foot lesions. Between 1964 and 2005, only serotype "O" was reported in Egypt, with the exception of 1972 when type "A" was introduced from Sub-Saharan Africa. In 2006, a novel type "A" strain entered Egypt and rapidly spread throughout the ruminant population, causing severe losses [31]. However, serotype O has been the

predominant type where type A has been controlled by vaccination [32]. During 2012, there has been a dramatic upsurge in FMD SAT-2 outbreaks in Egypt. Cattle, water buffalo and small ruminants were affected with severe clinical signs particularly in young animals with a mortality rate of up to 50%, approximately 40,000 cattle and water buffaloes were affected and more than 4,600 animals were killed; only FMDV-SAT-2 was detected, with an overall detection rate of 80.3 % [33, 34].

The clinical disease varies with the species, breed of the animal affected and serotype and strain of FMDV [35] and different strains of FMDV might affect different species and might have different transmission characteristics [36], the severity of clinical signs which hadn't been recorded before in Egypt may be due to serotype SAT-2 which was isolated in the FMD outbreak during the course of this study, further investigation will be applied for typing and sequencing of FMD virus gene. Shedding of viral RNA was detected in the four groups for two weeks after the beginning of clinical symptoms and then it was not detected after three weeks. Further quantitative PCR investigation on different secretions and excretions of experimentally infected sheep with the same serotype should be applied because of differences in susceptibility between breeds of sheep as well as variation in pathogenicity of virus strains [36].

The detection of antibody to the nonstructural proteins (NSPs) of FMDV can be used to identify past or present infection regardless of serotype of the virus involved, whether or not the animal has also been vaccinated. Therefore the tests can be used to confirm suspected cases of FMD and to detect viral activity or to substantiate freedom from infection on a population basis [1, 37]. Antibodies to the polyproteins 3AB or 3ABC are generally considered to be the most reliable indicators of infection [8]. However, in this study the detection of antibody in sera collected during the outbreak indicated that the infection is recently occurred and there were no obvious differences between the four groups on the level of serum neutralizing antibody titers in infected sheep. Antibodies to the 3ABC antigens could not be detected earlier than 10 days post infection as previously reported [37, 38]. Antibody titer started to slightly decline after two months of infection, with the continuous detection of viral RNA in oral epithelial swabs, these results are in harmony with those previously recorded by Pirbright Laboratory [39].

Koller *et al.* and Hall *et al.* [40, 41] proved that supplementing Se through both routes, oral and parenteral, in sheep can modulate the immune response in a way

that reduces severity and/or improves recovery from a disease process. Besides, other studies on lambs experimentally challenged with Parainfluenza virus and supplemented with dietary Vit E and Se, proved enhancement of both humoral and cellular immunity especially serum IgM concentrations tended to be higher for Se-supplemented lambs [13]. On the basis of the present results, it can be concluded that organic multi nutrient-antioxidants (Zn- Met. and Vit E with Se enriched yeast) have potential for improvement of the general health condition, performance and healing of lesions with no obvious effect on humeral immune response nor virus shedding of sheep infected with FMDV.

ACKNOWLEDGMENT

This work was financially supported by National Research Center as a part of a project entitled: Improvement of general health condition and immune status of small ruminants using antioxidants (The 9th research plan, No. 9040203).

REFERENCES

1. OIE Terrestrial Manual, 2009. Chapter 2. 1. 5. Version adopted by the World Assembly of Delegates of the OIE in May 2009.
2. Barnett, P.V., P. Keel, S. Reid, R.M. Armstrong, R.J. Statham, C. Voyce, N. Aggarwal and S.J. Cox, 2004. Evidence that high potency of foot and mouth disease vaccine inhibits local virus replication and prevents the carrier state in sheep. *Vaccine*, 22: 1221-1232.
3. Kitching, R.P. and G.J. Hughes, 2002. Clinical variation in foot and mouth disease: sheep and goats. *Rev. sci. tech. Off. Int. Epiz.*, 21(3): 505-512.
4. Donaldson, A.I. and T.R. Doel, 1992. Foot-and-mouth disease: the risk for Great Britain after 1992. *Vet. Rec.* 131: 114-120.
5. Ferguson, N.M., C.A. Donnelly and R.M. Anderson, 2001. The foot-and-mouth epidemic in Great Britain: pattern of spread and impact of interventions. *Science*, 292: 1155-1160.
6. Kitching, R.P., 1996. A recent history of foot-and-mouth disease. *J. Comp. Pathol.*, 118: 89-108.
7. Taylor, M.N. and M. Tufan, 1996. Detailed investigations using farmer interviews to assess the losses caused by FMD outbreaks in Turkey. Report of Turkish-German Animal Health Information Project (GTZ), Ministry of Agriculture and Rural Affairs,

- Republic of Turkey. Deutsche Gesellschaft für Technische Zusammenarbeit (GTZ) GmbH-German Technical Cooperation, Eschborn, Germany.
8. Mackay, D.K.J., M.A. Forsyth, P.R. Davies, A. Berlinzani, G.J. Belsham, M. Flint and M.D. Ryan, 1997. Differentiating infection from vaccination in foot-and-mouth disease using a panel of recombinant, nonstructural proteins in ELISA. *Vaccine*, 16: 446-459.
 9. Patil, P.K., J. Bayry, C. Ramakrishna, B. Hugar, L.D. Misra, K. Prabhudas and C. Natarajan, 2002. Immune responses of sheep to quadrivalent double emulsion foot-and-mouth disease vaccines: rate of development of immunity and variations among other ruminants. *J. Clin Microbiol.*, 40(11): 4367-71.
 10. Shawky, M., M. Abd El-Aty, Hiam M. Fakry, Hind M. Daoud, I. Ehab El-Sayed, G. Wael Mossad, Sonia A. Rizk, H. Abu-Elnaga, A.A. Mohamed, A. Abd El-kreem and E.M. Farouk, 2013. Isolation and Molecular Characterization of Foot and Mouth Disease SAT2 Virus during Outbreak 2012 in Egypt. *J. Vet. Adv.*, 3(2): 60-68.
 11. FAO, 2012. Foot-and-mouth disease caused by serotype SAT2 in Egypt and Libya. *Empres watch*, Vol. 25 – March 2012.
 12. Carlson, B.A., M.H. Yoo, R.K. Shrimali, R. Irons, V.N. Gladyshev, D.L. Hatfield and J.M. Park, 2010. Role of selenium-containing proteins in T-cell and macrophage function. *Proc. Nutr. Soc.*, 69(3): 300-310.
 13. Reffett, J.K., J.W. Spears and Jr. T.T. Brown, 1988. Effect of Dietary Selenium and Vitamin E on the Primary and Secondary Immune Response in Lambs Challenged with Parainfluenza3 Virus. *J. Anim Sci.*, 66: 1520-1528.
 14. Puertollano, M.A., E. Puertollano, G.A. de Cienfuegos and M.A. de Pablo, 2011. Dietary antioxidants: immunity and host defense. *Curr. Top. Med. Chem.*, 11(14): 1752-66.
 15. Young, A.J. and G.M. Lowe, 2001. Mini review: Antioxidant and prooxidant properties of carotenoids. *Arch. Biochem. Biophys.*, 385: 20-27.
 16. Hamam, A.M. and H.A.A. Abou-Zeina, 2007. Effect of vitamin E and selenium supplements on the antioxidant markers and immune status in sheep. *J. Biol. Sci.*, 7: 870-878.
 17. Korniluk1, K., M. Gabryszuk, J. Kowalczyk1 and M. Czaudernal, 2008. Effect of diet supplementation with selenium, zinc and α -tocopherol on fatty acid composition in the liver and loin muscle of lambs. *Animal Science Papers and Reports*, 26(1): 59-70.
 18. Beck, M.A., 2000. Nutritionally induced oxidative stress. *American Journal of Clinical Nutrition*, 71: 1676s-1679s.
 19. Radostitis, O.M., D.C. Blood, C.C. Gay and K.W. Hinchcliff, 2000. *Veterinary Medicine: A textbook of the diseases of cattle, sheep, goats and horses*. 9th Ed. Bailliere Tindall, Philadelphia, USA, pp: 3-37.
 20. Eva Perez-Martin, Marcelo Weiss, Fayna Diaz-San Segundo, Juan M. Pacheco, Jonathan Arzt, Marvin J. Grubman and Teresa de los Santosa, 2012. Bovine Type III Interferon Significantly Delays and Reduces the Severity of Foot-and-Mouth Disease in Cattle. *J. Virol.*, 86(8): 4477.
 21. Edwards, S., S.B. Woods, D.G. Westcott, M. Emmerson, P.C. Jones and A.J. Phillips, 1986. An Evaluation of Five Serological Tests for the Detection of Antibody to Bovine Herpesvirus 1 in Vaccinated and Experimentally Infected Cattle. *Res. Vet. Sci.*, 41(3): 378-382.
 22. Kitching, R.P. and A.I. Donaldson, 1987. Collection and transportation of specimens for vesicular virus investigation. *Rev. sci. tech. Off. Int. Epiz.*, 6(1): 263-272.
 23. Reid, S.M., N.P. Ferris, G.H. Hutchings, A.R. Samuel and N.J. Knowles, 2000. Primary diagnosis of foot-and-mouth disease by reverse transcription polymerase chain reaction. *J. Virol. Methods* 89: 167-176.
 24. Ireland, D.C. and Y.S. Binopal, 1998. Improved detection of Capripoxvirus in biopsy samples by PCR. *J. Virol Methods*, 74: 1-7.
 25. Chew, B.P., 1995. Antioxidant vitamins affect food animal immunity and health. *J. Nutr.*, 125: 1804-1808.
 26. McDowell, L.R., 2002. Recent advances in minerals and vitamins on nutrition of lactating cows. *Pak. J. Nutr.*, 1: 8-19.
 27. McDowell, L.R., N. Wilkinson, R. Madison and T. Felix, 2007. Vitamins and minerals functioning as antioxidants with supplementation considerations. In the proceedings of the Florida Ruminant Nutrition Symposium. Best Western Gateway Grand. Gainesville, FL, 30-31 January.
 28. Tomlinson, D.J., M.T. Socha and J.M. DeFrain, 2008. Role of trace minerals in the immune system. pp: 39-52. In: *Proc. Penn State Dairy Cattle Nutrition Workshop*. Grantville, PA.
 29. Madhanmohan, M., S.B. Nagendrakumar and V.A. Villuppanoor Alwar Srinivasan, 2010. Protection against direct in-contact challenge

- following foot-and-mouth disease vaccination in sheep and goats: the effect on virus excretion and carrier status. *Vet. Res. Commun.*, 34: 285-299.
30. Donaldson, A.I. and R.F. Sellers, 2000. Foot-and-mouth disease, pp: 254-258. In W.B. Martin and I.D. Aitken (ed.), *Diseases of sheep*. Blackwell Science, Oxford, United Kingdom.
 31. Knowles, N.J., J. Wadsworth, S.M. Reid, K.G. Swabey, A.A. El-Kholy, A.O. Abd El-Rahman, H.M. Soliman, K. Ebert, N.P. Ferris, G.H. Hutchings, R.J. Statham, D.P. King and D.J. Paton, 2007. Foot-and-mouth disease virus serotype A in Egypt. *Emerg Infect Dis.*, 13: 1593-1596.
 32. Ghoneim, N.H., A.K. Abdel-Karim, L. El-Shehawy and K.A. Abdel-Moein, 2010. Foot and mouth disease in animals in Sharkia governorate-Egypt. *Transbound Emerg Dis.*, 57: 19-21.
 33. Ahmed, H.A., S.A.H. Salem, A.R. Habashi, A.A. Arafa, M.G.A. Aggour, G.H. Salem, A.S. Gaber, O. Selem, S.H. Abdelkader, N.J. Knowles, M. Madi, B. Valdazo-González, J. Wadsworth, G.H. Hutchings, V. Mioulet, J.M. Hammond and D.P. King, 2012. Emergence of Foot-and-Mouth Disease Virus SAT 2 in Egypt During 2012 Blackwell Verlag GmbH. *Transboundary and Emerging Diseases*, 59: 476-481.
 34. Kandeil, A., R. El-Shesheny, G. Kayali, M. Moatasim, O. Bagato, M. Darwish, A. Gaffar, A. Younes, T. Farag, M.A. Kutkat and M.A. Ali, 2013. Characterization of the recent outbreak of foot-and-mouth disease virus serotype SAT2 in Egypt. *Arch. Virol.*, 158(3): 619-627.
 35. Knowles, N.J. and A.R. Samuel, 2003. Molecular epidemiology of foot and- mouth disease virus. *Virus Res.*, 91: 65-80.
 36. Bravo de Rueda, C., Mart C.M. de Jong, Phaedra L. Eblél and Aldo Dekker, 2014. Estimation of the transmission of foot-and-mouth disease virus from infected sheep to cattle *Veterinary Research*, 45: 58.
 37. Bruderer, U., H. Swam, B. Haas, N. Visser, E. Brocchi, S. Grazioli, J.J. Esterhuysen, W. Vosloo, M. Forsyth, N. Aggarwal, S. Cox, R. Armstrong and J. Anderson, 2004. Differentiating infection from vaccination in foot-and-mouth-disease: evaluation of an ELISA based on recombinant 3ABC, *Veterinary Microbiology*, 101: 187-197.
 38. Chung, W.B., K.J. Sorensen, P.C. Liao and M.H. Jong, 2002. Differentiating FMDV infected pigs from vaccinated pigs by blocking ELISA using non-structural protein 3ABC as antigen and its application to an eradication program. *J. Cl. Micro.*, 40: 2843-2848.
 39. Pirbright Laboratory 5th June, 2003. Foot-and-mouth disease: scientific problems and recent progress 1st annual report (2003) prepared for DEFRA, Science Directorate.
 40. Koller, L.D., J.H. Exon, P.A. Talcott, C.A. Osborne and G.M. Henningsen, 1986. Immune responses in rats supplemented with selenium. *Clin. exp. Immunol.*, 63: 570-576.
 41. Hughes, G.J., V. Mioulet, R.P. Kitching, M.E. Woolhouse, S. Alexandersen and A.I. Donaldson, 2002. Foot-and-mouth disease virus infection of sheep: implications for diagnosis and control. *Vet. Rec.*, 150: 724-727.