

## A Comparative Study of Levofloxacin- and Gentamicin-Induced Nephrotoxicity in Rabbits

<sup>1</sup>Samah S. Oda, <sup>2</sup>Mohamed A. Hashem and <sup>1</sup>Dina R. Gad El-Karim

<sup>1</sup>Department of Pathology, Faculty of Veterinary Medicine, Alexandria University, Egypt

<sup>2</sup>Department of Clinical Pathology, Faculty of Veterinary Medicine, Zagazig University, Egypt

**Abstract:** The present investigation reports the nephrotoxic effect of levofloxacin and gentamicin in rabbits on the basis of pathological and clinicopathological alterations. Thirty rabbits were divided into 3 equal groups (n=10 in each group): control group; levofloxacin group: rabbits received 82 mg /kg bwt. Levofloxacin Hcl orally once daily for 4 weeks and gentamicin group: rabbits injected S/C with 40 mg /kg bwt. Gentamicin sulphate once daily for 4 weeks. Clinically, no mortalities were recorded in both treated groups. At the end of the experiment, both treated groups showed significant decrease in body weight. Non-significant changes were observed in hematological parameters except significant changes in total leucocytic count at the end of the 1<sup>st</sup> and 4<sup>th</sup> weeks of the experiment in both treated groups. Both antibiotics induced significant changes in serum hepatic and renal function parameters. These changes were marked at the end of the 4<sup>th</sup> week post treatment. The prominent histopathological lesions in levofloxacin group were typical of diffuse lymphocytic interstitial nephritis; while in gentamicin treated group were consisted of cortical tubulonecrosis with interstitial mononuclear infiltration and fibroplasia. The results indicated that both levofloxacin and to greater extent gentamicin induced nephrotoxic alterations in rabbits when applied at 4 times its therapeutic doses in time dependent manner.

**Key words:** Levofloxacin • Gentamicin • Nephrotoxicity • Histopathology • Rabbits

### INTRODUCTION

The kidney is a target organ for numerous environmental toxins and therapeutic agents such as antibiotics [1]. Although antibiotics have altered fundamentally the controlling of many diseases, they often have several side effects; one of the most important is the increased incidence of acute and/or chronic renal insufficiency after long term usage [2, 3]. Wide range of toxicity has been reported with commonly rates of 5-14% for nephrotoxicity [4].

Gentamicin (GM) is probably one of the most commonly used aminoglycoside antibiotics for the treatment of serious and life-threatening infections caused by Gram-negative bacteria [5]. In spite of its beneficial effects, low cost and low levels of resistance, serious complications like nephrotoxicity limit its use [6, 7]. Although several studies have been undertaken to investigate the mechanisms underlying these unwanted side effects, the mechanism of nephrotoxicity induced by GM is not completely known and remains to be studied

further [8]. However, the pathological mechanisms involved in GS induced nephrotoxicity include induction of oxidative stress, apoptosis, necrosis, up regulation of transforming growth factor B(TGF-B), elevation of endothelin I and increase of monocyte/macrophages infiltration [9- 11].

Fluoroquinolones comprise a relatively large, growing and most interesting group of antibiotics, which have made major impact in the field of antimicrobial chemotherapy [12]. These agents represent an improvement over their quinolone counterparts in many ways, including a wider spectrum of antimicrobial activity, improved pharmacokinetic properties, clinical efficacy against a wide range of diseases and fewer and less severe adverse effects. Levofloxacin belongs to the second generation of fluoroquinolones which has high activity against Gram-positive, Gram-negative and anaerobic bacteria [13]. The effects on the kidney that have been reported with quinolones and fluoroquinolones include mild interstitial nephritis, occult blood in urine, decreased renal function and crystalluria [14]. Therefore,

this study aimed to evaluate the nephrotoxic effect of the high doses of levofloxacin and gentamicin treatment in rabbits on the basis of pathological and clinicopathological alterations.

## MATERIALS AND METHODS

**Animals and Experimental Design:** Thirty male New Zealand rabbits of 2000 - 2400 g body weight were housed in cages under proper hygienic conditions and fed on pelleted commercial feed and water was supplied without restriction. Rabbits received human care in compliance with the animal care guidelines of the National Institute of Health and the local ethical committee approved this study. After 2 weeks of adaptation, rabbits were randomly divided into three groups of ten rabbits each: control group; levofloxacin group: rabbits received 82 mg /kg bwt. levofloxacin Hcl (Pharaonia Pharmaceuticals Co. Egypt) orally once daily for 4 weeks and gentamicin group: rabbits injected S/C with 40 mg /kg bwt. gentamicin sulphate (Garamicin, 40 %)® obtained from Memphis pharmaceutical company once daily for 4 weeks. The doses of levofloxacin and gentamicin represent four times the therapeutic doses of rabbit according to Paget & Barnes [15]. Blood samples were collected from jugular veins during slaughtering at the end of the 1<sup>st</sup> and 4<sup>th</sup> weeks post-treatment whereas five rabbits from each group were sacrificed. A part of blood samples were collected in tubes containing dipotassium salt of EDTA as anticoagulant and used for evaluation of hemogram. The other part was placed in plain centrifuge tubes, left to clot and centrifuged at 3000 rpm for 15 minutes for separation of serum. The clear serum was carefully separated and kept at -20°C for biochemical analysis.

**Hematological Examination:** The erythrocytic parameters of all collected blood samples red blood cells (RBCs) count, packed cell volume (PCV%) and hemoglobin (Hb) concentration were evaluated following the standard techniques described by Feldman *et al.* [16]. The erythrocytic indices (mean corpuscular volume (MCV), mean corpuscular hemoglobin (MCH), mean corpuscular hemoglobin concentration (MCHC) were calculated [17]. Total leukocytic count (TLC) was performed using the improved Neubauer hemocytometer, leukocytic pipette and Turkey's solution as diluting fluid. The differential leukocytic count was performed manually by microscopical examination of blood film after fixation with absolute methyl alcohol and stained by Wright's stain according to standard technique described by Tankeyul *et al.* [18].

**Serum Biochemical Parameters:** Serum biochemical parameters were evaluated using commercially available diagnostic kits (Diamond Co. Egypt). The serum activities of serum alanine aminotransferase (ALT) and aspartate aminotransferase (AST) were colorimetrically estimated according to Reitman and Frankel [19], alkaline phosphatase (ALP) using the colorimetric method of Belfield and Goldberry [20], as well as serum levels of total protein and albumin were colorimetrically determined according to the method described by Doumas *et al.* [21] and Drupt [22], respectively. Serum globulins level was calculated by subtracting the obtained albumin level from the obtained total protein level [23]. The concentration of blood urea was colorimetrically assayed according to the method described by Tabacco *et al.* [24] and creatinine was determined by colorimetric kinetic method according to Fabiny and Ertingshausen [25].

**Histopathological Studies:** After each sacrifice, small pieces of kidney were quickly collected, fixed in neutral buffered formalin (10%) and processed by paraffin embedding technique. Five micron thick sections were stained by hematoxylin and eosin (H&E) according to the method described by Bancroft and Stevens [26].

**Statistical Analysis:** Data were analyzed using the GLM procedure of the Statistical Analysis System Software [27]. The analysis model included the effects of group and period of measurement within group. Means were compared using the Least Squares Means (LSM) of the same program and the level of significance was 0.05.

## RESULTS

**Clinical Signs, Mortalities and Body Weight:** Clinically, no mortalities were recorded in rabbits of both treated groups. The animals of both of treated groups did not exhibit any clinical signs at the end of the first week of the treatment except for excessive salivation in levofloxacin treated group which started from first day of administration and continued to the end of the experiment. Two weeks post-treatment, animals of both of treated groups exhibited mild anorexia, fur loss and depression toward the end of the experiment. Moreover, all treated rabbits showed a significant weight loss in a time-dependent manner, in addition to turbidity of the urine was noticed after the first week of the treatment which was more obvious in levofloxacin treated group. Also, bloody urine was obvious in gentamicin treated group at day 18 post treatment. By the end of the experiment,

Table 1: Effect of levofloxacin and gentamicin treatments for 4 weeks on body weight and hematological parameters in rabbits.

Parameter	Period (week)	Group		
		Control	Levofloxacin	Gentamicin
Body weight, g	0 day	2050.0 ± 57.8 a	2090.0 ± 61.7 a	2085.0 ± 31.5 a
	1 <sup>st</sup>	2070.0 ± 57.7 a	2088.0 ± 57.4 a	2058.0 ± 26.3 a
	4 <sup>th</sup>	2116.7 ± 84.1 a	1880.0 ± 54.8 b*	1863.0 ± 35.5 b*
RBCs, 10 <sup>6</sup> /ml	1 <sup>st</sup>	5.88 ± 0.61 a	5.26 ± 0.55 a	5.56 ± 0.51 a
	4 <sup>th</sup>	6.04 ± 0.19 a	5.88 ± 0.61 a	5.90 ± 0.12 a
Hemoglobin, g/dl	1 <sup>st</sup>	12.87 ± 1.18 a	11.93 ± 1.07 a	12.13 ± 1.07 a
	4 <sup>th</sup>	13.38 ± 0.21 a	12.90 ± 0.66 a	12.88 ± 0.39 a
PCV, %	1 <sup>st</sup>	38.87 ± 3.43 a	38.94 ± 1.47 a	38.30 ± 1.43 a
	4 <sup>th</sup>	38.94 ± 2.39 a	38.97 ± 2.82 a	38.71 ± 0.86 a
MCV, fl	1 <sup>st</sup>	66.47± 1.95 a	65.92± 1.01 a	65.88± 1.07 a
	4 <sup>th</sup>	66.14± 1.15 a	66.58± 1.03 a	65.97± 0.70 a
MCH, pg	1 <sup>st</sup>	21.00± 0.55 a	20.94± 0.48 a	21.22± 0.63 a
	4 <sup>th</sup>	21.28± 0.34 a	21.03± 0.57 a	21.92± 0.65 a
MCHC, %	1 <sup>st</sup>	31.70± 0.25 a	31.67± 0.46 a	31.22± 0.41 a
	4 <sup>th</sup>	30.98± 0.15 a	30.96± 0.48 a	30.24± 0.39 a
WBCs, 10 <sup>3</sup> /ml	1 <sup>st</sup>	5.57 ± 0.52 b	7.97 ± 1.24 a	8.27 ± 1.87 a
	4 <sup>th</sup>	6.12 ± 0.56 b	9.86 ± 0.45 a*	9.99 ± 0.25 a*
Lymphocytes, %	1 <sup>st</sup>	50.33 ± 0.67 a	47.33 ± 2.19 b	47.00 ± 0.67 b
	4 <sup>th</sup>	50.60 ± 1.25 a	42.80 ± 1.85 b*	39.20 ± 0.87 c*
Neutrophils, %	1 <sup>st</sup>	34.33± 0.58 b	37.33± 0.88 a	36.00± 0.58 a
	4 <sup>th</sup>	35.00± 0.93 c	44.6± 1.09 b*	47.40± 1.86 a*
Eosinophils, %	1 <sup>st</sup>	2.33± 0.33 a	2.31± 0.46 a	2.15± 0.35 a
	4 <sup>th</sup>	2.24± 0.45 a	2.26± 0.40 a	2.20± 0.20 a
Basophils, %	1 <sup>st</sup>	6.33± 0.67 a	6.09± 0.34 a	6.35± 0.67 a
	4 <sup>th</sup>	6.00± 0.45 a	5.90± 0.51 a	5.88± 0.24 a
Monocytes, %	1 <sup>st</sup>	8.00± 0.54 a	8.33± 0.45 a	8.00± 0.50 a
	4 <sup>th</sup>	8.40± 0.51 a	8.80± 0.37 a	8.20± 0.92 a
Platelets count (×10 <sup>3</sup> /μl)	1 <sup>st</sup>	256.78± 1.97 a	256.76± 1.07 a	257.33± 1.22 a
	4 <sup>th</sup>	256.20± 1.76 a	256.60± 2.91 a	256.40± 2.05 a

Values are means ± standard errors.

WBCs, white blood cells count; RBCs, red blood corpuscles count; PCV, packed cell volume; MCV, mean corpuscular volume; MCH, mean corpuscular hemoglobin; MCHC, mean corpuscular hemoglobin concentration.

Means in the same row without a common letter differ significantly (P<0.05).

\* For body weight, means of 0 day and final weights differ significantly in the same group (P<0.05). For other parameters, \* means of the 1<sup>st</sup> and 4<sup>th</sup> weeks differ significantly (P<0.05) in the same group.

both treated groups showed significant reduction in body weights compared to the control group and their initial body weight (Table 1).

**Hematological Results:** As illustrated in Table (1), there were non-significant changes in RBCs count, PCV%, Hb, MCV, MCH and MCHC in both treated groups either at the end of the 1<sup>st</sup> and 4<sup>th</sup> weeks post-treatment as compared to control group. As well, levofloxacin and gentamicin treated groups showed a significant increase in TLC at the end of the 1<sup>st</sup> and 4<sup>th</sup> weeks of the experiment. The highest increase in TLC was observed at the end of the 4<sup>th</sup> week post-treatment and it was higher in levofloxacin treated rabbits than gentamicin treated one. The differential leukocytic counts showed a significant increase and

decrease in percentage of neutrophils and lymphocytes, respectively at the end of the 1<sup>st</sup> and 4<sup>th</sup> weeks post-treatment comparatively with the control group. These changes at the percentage of neutrophils and lymphocytes were marked at the end of the 4<sup>th</sup> week post-treatment, while other leukocytic count (eosinophils, basophils, monocytes and platelets) showed non-significant changes at any point of the experiment compared to the control group.

**Serum Biochemical Parameters:** As shown in Table (2). The serum AST and ALT activities showed a significant increase in both treated groups at the end of the 1<sup>st</sup> and 4<sup>th</sup> weeks of the treatment in a time dependent manner; however levofloxacin group showed highest

Table 2: Effect of levofloxacin and gentamicin treatments for 4 weeks on serum biochemical parameters in rabbits.

Parameter	Period (week)	Group		
		Control	Levofloxacin	Gentamicin
ALT, U/L	1 <sup>st</sup>	37.00 ± 3.21 c	63.33 ± 3.53 a	44.56 ± 2.35 b
	4 <sup>th</sup>	38.60 ± 1.72 c	116.00 ± 2.94 a*	92.80 ± 1.69 b*
AST, U/L	1 <sup>st</sup>	35.67 ± 1.20 b	51.00 ± 3.61 a	47.00 ± 3.77 a
	4 <sup>th</sup>	37.20 ± 2.10 c	113.00 ± 2.36 a*	83.80 ± 2.63 b*
ALP, U/L	1 <sup>st</sup>	131.67 ± 4.11 a	131.00 ± 3.64 a	131.00 ± 4.64 a
	4 <sup>th</sup>	132.80 ± 5.76 c	234.00 ± 3.32 a*	181.80 ± 2.22 b*
Total protein, g/dl	1 <sup>st</sup>	6.85 ± 0.43 a	6.69 ± 0.40 a	5.56 ± 0.40 b
	4 <sup>th</sup>	5.94 ± 0.55 a	3.66 ± 0.25 b*	3.97 ± 0.22 b*
Albumin, g/dl	1 <sup>st</sup>	3.38 ± 0.15 a	3.40 ± 0.20 a	2.06 ± 0.05 b
	4 <sup>th</sup>	3.40 ± 0.12 a	2.13 ± 0.03 b*	1.88 ± 0.03 c
Globulins, g/dl	1 <sup>st</sup>	3.47 ± 0.06 a	3.29 ± 0.10 a	3.50 ± 0.10 a
	4 <sup>th</sup>	2.54 ± 0.10 a*	1.53 ± 0.11 c*	2.09 ± 0.12 b*
Urea, mg/dl	1 <sup>st</sup>	52.76 ± 1.45 b	55.67 ± 4.06 ab	59.67 ± 3.06 a
	4 <sup>th</sup>	52.80 ± 2.63 c	85.60 ± 4.12 b*	104.60 ± 4.19 a*
Creatinine, mg/dl	1 <sup>st</sup>	1.52 ± 0.04 b	2.59 ± 0.09 a	2.97 ± 0.08 a
	4 <sup>th</sup>	1.63 ± 0.09 c	3.11 ± 0.06 b*	4.78 ± 0.12 a*

ALT, alanine aminotransferase; AST, aspartate aminotransferase; ALP, alkaline phosphatase.

Means in the same row without a common letter differ significantly (P<0.05).

\* means of the 1<sup>st</sup> and 4<sup>th</sup> weeks differ significantly (P<0.05) in the same group.

increase in these enzymes levels at both 1<sup>st</sup> and 4<sup>th</sup> weeks of the treatment than gentamicin group. The serum ALP activity was increased significantly in levofloxacin and gentamicin-treated groups when compared with the control group at the end of the fourth week of the treatment only. The highest increase was in levofloxacin treated group in comparison with gentamicin treated group. The serum total protein level showed a significant decrease only in gentamicin treated rabbits when compared with the control group at the end of the 1<sup>st</sup> week post-treatment, however a highly significant decrease was observed at the end of the 4<sup>th</sup> week post-treatment in both treated groups. Moreover, serum albumin level was decreased in levofloxacin group only at the end of the 4<sup>th</sup> week post-treatment but it was decreased at the end of the 1<sup>st</sup> and 4<sup>th</sup> weeks in gentamicin group if compared with the control group. Serum globulins level was significantly decreased in levofloxacin and gentamicin treated groups only at the end of the 4<sup>th</sup> week of the treatment, however, it revealed non-significant changes at the end of the 1<sup>st</sup> week post-treatment when compared with control group. Also, Table (2) shows daily administration of high doses of levofloxacin and gentamicin to rabbits for 1 and 4 weeks provoked a significant increase in serum concentration of urea and creatinine in time dependent manner, in comparison with the control group. However, marked increase in these enzymes levels was observed in gentamicin treated group.

**Histopathological Findings:** Kidneys of the control group at the end of the both 1<sup>st</sup> and 4<sup>th</sup> weeks of the experiment had normal morphology of the renal parenchyma with well-defined glomeruli and tubules (Fig. 1A). Kidneys of levofloxacin-treated group during the 1<sup>st</sup> week of the experiment showed multifocal interstitial nephritis that characterized by mononuclear cells infiltration, mainly lymphocytes. In addition, tubular necrosis was evident and necrotic tubular epithelial cells showed pyknotic nuclei and hypereosinophilia of its cytoplasm (Fig. 1B). Some cortical renal tubules showed cytoplasmic vacuolation and presence of eosinophilic material inside their lumina. The intertubular blood vessels were congested and surrounded by mononuclear cells infiltrates. During the 4<sup>th</sup> week of the experiment, the microscopic renal pictures were similar to those previously described during the 1<sup>st</sup> week, but it was more severe in the intensity and distribution. The prominent lesion was diffuse lymphocytic interstitial nephritis (Fig. 1C). Kidneys of gentamicin-treated rabbits during the 1<sup>st</sup> week of the experiment exhibited vacuolar degeneration of the lining epithelium of proximal convoluted tubules with multifocal tubular necrosis. The necrotic tubular epithelium was detached and desquamated in the tubular lumina (Fig. 2A). Some necrotic renal tubules were hyalinized. In addition to the above mentioned lesions, the interstitial tissues exhibited multifocal monocular cells infiltrates, particularly lymphocytes (Fig. 2B). Congestion

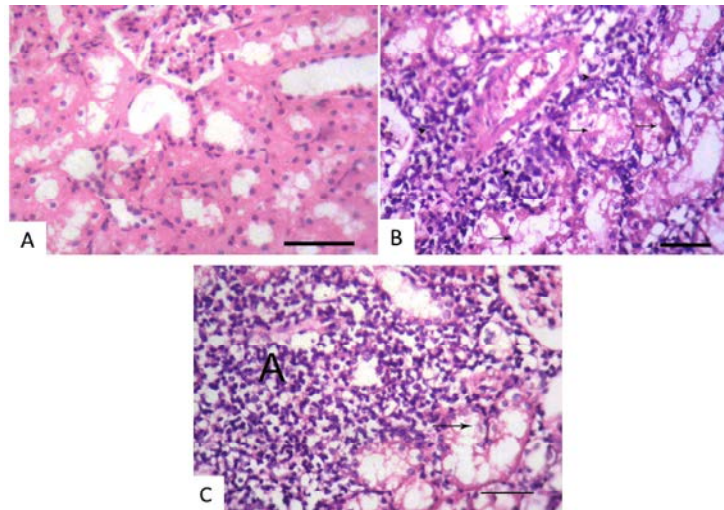


Fig. 1: Kidney of a rabbit stained by HE (Bar=50 $\mu$ m). (A) Normal morphology of the renal parenchyma with well-defined glomeruli and tubules. (B) Necrotic cortical renal tubules (arrows), accompanied by mononuclear cell infiltrates (arrowheads) in a levofloxacin-treated rabbit during first week of treatment. (C) Diffuse lymphocytic interstitial nephritis (A) and tubulonecrosis (arrow) in a levofloxacin-treated rabbit for four weeks.

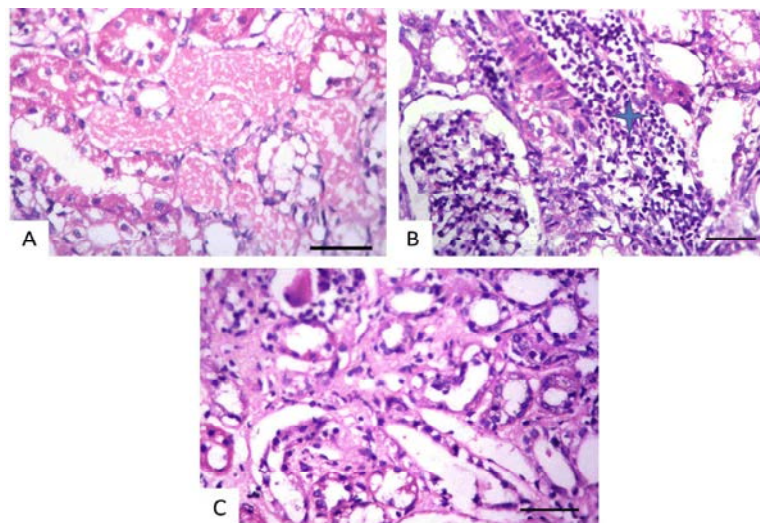


Fig. 2: Kidney of a gentamicin-treated rabbit stained by HE (Bar=50 $\mu$ m). During first week of treatment: (A) Detached and desquamated necrotic tubular epithelium in the tubular lumina, (B) Multifocal lymphocytic cell infiltrates (asterisk). (C) Four weeks of treatment: Prominent interstitial fibroplasia.

of the intertubular blood vessels was evident. During the 4<sup>th</sup> week of the experiment, renal lesions were similar to those previously described during the 1<sup>st</sup> week of the experiment. Besides, there was prominent fibroplasia as the interstitial tissues were markedly thickened by fibrous connective tissue (Fig. 2C) and mononuclear cells infiltrates. As well as, cortical tubular epithelium was suffered from severe cytoplasmic vacuolation and necrosis. The intertubular blood vessels were severely congested.

## DISCUSSION

This study was conducted to evaluate the nephrotoxic effect of the high doses of levofloxacin and gentamicin treatment in rabbits on the basis of pathological and clinicopathological alterations. Results of this study revealed clinical signs of depression, anorexia, roughness of body coat and fur loss in animals of both treated groups after the 1<sup>st</sup> week of treatment. At the end of the experiment, both treated groups showed

significant decrease in body weights compared to the control group. Roy *et al.* [28] reported suppressed feed intake and decreased weight gain in rats dosed with besifloxacin as a result of direct irritation of the intubated fluoroquinolones on the gastrointestinal mucosa. Saleem *et al.* [29] recorded a significant decrease in body weight and food consumption of birds received gentamicin at a dose levels of 60, 70, 80 and 90 mg/kg B.Wt. started from first week of the experiment and continued till the end of the experiment while the body weight loss and decreased food consumption of birds received gentamicin as dose level of 40 mg/kg B.Wt. started from second week of the experiment and continued till the end of the experiment at 5 weeks. Concerning hematological results of levofloxacin group at both 1<sup>st</sup> and 4<sup>th</sup> weeks revealed non-significant changes except for increased total leukocytic count with a significant increase and decrease in neutrophils and lymphocytes percent respectively. This neutrophilic leukocytosis may be attributed to the immune mediated response against the precipitation of foreign complexes of the agent [30]. These results were in agreement with Escobar and Grindem, [31]. Also, hemogram results of gentamicin group, there were no significant changes in hematological parameters at the end of both 1<sup>st</sup> and 4<sup>th</sup> weeks post-treatment except for leukocytosis with neutrophilia and lymphopenia. These results agree with Fadel and Larkin [32]. Regarding the biochemical results in our experiment a significant increase in serum AST and ALT activities was observed at 1<sup>st</sup> and 4<sup>th</sup> weeks and a significant increase in serum activity of ALP only at the end of 4<sup>th</sup> week of treatment in both levofloxacin and gentamicin treated groups. These results are compatible with those recorded by Rashmi *et al.* [12], Roy *et al.* [33] and Saleemi *et al.* [29], Alarifi *et al.* [34], respectively. Levofloxacin group showed marked increase in these enzymes levels at both 1<sup>st</sup> and 4<sup>th</sup> weeks of the treatment than those of gentamicin group. Hypoproteinemia and hypoalbuminemia were evident in levofloxacin treated group at 4<sup>th</sup> week post-treatment; however, in gentamicin treated group at the end of both 1<sup>st</sup> and 4<sup>th</sup> weeks post-treatment. Such results may be attributed to liver damage and nephrotoxic effect induced by both levofloxacin [12, 33] and gentamicin [35, 36] treatment causing severe reduction in protein synthesis by liver and also increases protein loss in urine by the kidney. Serum urea and creatinine levels are the most sensitive parameters in diagnosis of renal disease [37]. Therefore, serum urea and creatinine levels were significantly increased in levofloxacin treated group at both 1<sup>st</sup> and 4<sup>th</sup> weeks post-treatment. These results could be attributed to severe tubulointerstitial nephritis [12].

Concerning gentamicin group, our study revealed a significant increase in serum levels of urea and creatinine at 1<sup>st</sup> and 4<sup>th</sup> weeks. These results agree with Alarifi *et al.* [34], Dinevet *et al.* [38] and Christo *et al.* [39]. It may be due to tissue spilling and cellular residues inside the tubular lumen due to tubular destruction induced by gentamicin which partially or totally obstructs the tubules and reduces or even voids the excretory function of the affected nephron, in addition, it increases the hydrostatic pressure inside tubules and in Bowman's capsules which reduces filtration pressure gradient and consequently the glomerular filtration rate [40]. However, marked increase in these enzymes levels were observed in gentamicin treated group. The encountered renal lesions which were noticed in levofloxacin-treated group at 1<sup>st</sup> and 4<sup>th</sup> weeks of the experiment were typical of tubulointerstitial nephritis. Fluoroquinolones administration is believed to have an immunological basis as drug derived antigen can mimic an antigen normally present within tubular basement membrane encouraging an immune response against this antigen resulting in attraction of inflammatory cells as T-lymphocytes and mononuclear cells [41]. The interstitial nephritis of the present work was characterized by tubulonecrosis and intense infiltration of lymphocytes in the intertubular tissue. These results are well-matched with those of Hung *et al.* [42] and Walker *et al.* [43]. Kidney specimens of gentamicin-treated group revealed tubular necrosis, multifocal interstitial nephritis and congestion of the intertubular blood vessels at 1<sup>st</sup> and 4<sup>th</sup> weeks of the experiment with thickening and fibrosis of interstitial tissues at the end of the 4<sup>th</sup> week of the experiment. These results are parallel with those recorded by Rouaset *et al.* [44] and Rehman *et al.* [45]. These lesions may be resulted from the accumulation of gentamicin in proximal renal tubules which enhance the generation of reactive oxygen metabolites (ROS) which produce cellular injury and necrosis [35].

In conclusion, levofloxacin and to greater extent gentamicin induced nephrotoxic alterations in rabbits when applied at 4 times its therapeutic doses in time dependent manner.

## REFERENCES

1. Solhaug, M.J., P.M. Bolger and P.A. Jose, 2004. The developing kidney and environmental toxins. *Pediatrics*, 113: 1084-1091.
2. Manian, F.A., W.J. Stone and R.H. Alford, 1990. Adverse antibiotic effects associated with renal insufficiency. *Reviews of Infectious Diseases*, 12: 236-249.

3. Parlakpinar, H., M. Koc, A. Polat, N. Vardi, M.K. Ozer, Y. Turkoz and A. Acet, 2004. Protective effect of aminoguanidine against nephrotoxicity induced by amikacin in rats. *Urological Research*, 32: 278-282.
4. Baykal, A., F. Sariguli, G. Suleymanlar, P.I. Moreira, G. Perry, M.A. Smith and Y. Aliciguzel, 2005. Ciprofloxacin does not exert nephrotoxicity in rats. *American Journal of Infectious Diseases*, 1: 145-148.
5. Negrette-Guzman, M., S. Huerta-Yopez, O.N. Medina-Campos, Z.L. Zatarain-Barrón, *et al.*, 2013. Sulforaphane attenuates gentamicin-induced nephrotoxicity: role of mitochondrial protection. *Evidence-Based Complementary and Alternative Medicine*, <http://dx.doi.org/10.1155/2013/135314>.
6. Ali, B.H., M.A. Zaabi, G. Blunden and A. Nemmar, 2011. Experimental gentamicin nephrotoxicity and agents that modify it: a mini-review of recent research. *Basic & Clinical Pharmacology & Toxicology*, 109: 225-232.
7. Sun, X., B. Zhang, X. Hong, X. Zhang, X. Kong, 2013. Histone deacetylase inhibitor, sodium butyrate, attenuates gentamicin-induced nephrotoxicity by increasing prohibitin protein expression in rats. *European Journal of Pharmacology*, 707: 147-154.
8. Sahu, B., S. Tatireddy, M. Koneru, R. Borkar, J. Kumar, M. Kuncha, R. Srinivas, R. Sunder and R. Sistla, 2014. Naringin ameliorates gentamicin-induced nephrotoxicity and associated mitochondrial dysfunction, apoptosis and inflammation in rats: Possible mechanism of nephroprotection. *Toxicology and Applied Pharmacology*, <http://dx.doi.org/10.1016/j.taap.2014.02.022>
9. Geleilate, T.J., G.C. Melo, R.S. Costa, R.A. Volpini, T.J. Soares and T.M. Coimbra, 2002. Role of myofibroblasts, macrophages, transforming growth factor-beta endothelin, angiotensin-II and fibronectin in the progression of tubulointerstitial nephritis induced by gentamicin. *Journal of Nephrology*, 15: 633-642.
10. Bledsoe, G., S. Crickman, J. Mao, C.F. Xia, H. Murakami and L. Chao, 2006. Kallikrein/kinin protects against gentamicin-induced nephrotoxicity by inhibition of inflammation and apoptosis. *Nephrology Dialysis Transplantation*, 21: 624-633.
11. Balakumara, P., A. Rohillab and A. Thangathirupathi, 2010. Gentamicin-induced nephrotoxicity: do we have a promising therapeutic approach to blunt it? *Pharmacological Research*, 63: 179-186.
12. Rashmi, R., K. Jayakumar, H.D. Swamy and M.D. Bayer, 2012. Organ directed toxicity of norfloxacin in repeated dose 28-days oral toxicity study in female rats. *International Journal of Pharma and Bio Sciences*, 3: 88-97.
13. Davis, R. and H.M. Bryson, 1994. Levofloxacin. A review of its antibacterial activity, pharmacokinetics and therapeutic efficacy. *Drugs*, 38: 677-700.
14. Patterson, D.R., 1991. Quinolones toxicity: Methods of assessment. *The American Journal of Medicine*, 91: 35-37.
15. Paget, G.E. and J.M. Barnes, 1964. Evaluation of drug activities and toxicity tests *Pharmacometrics*. Academic Press, London. New York.
16. Feldman, B.F., J.G. Zinkle, N.C. Jain and S. Schalm, 2000. *Veterinary hematology*. 5th Ed. Philadelphia: Williams and Wilkins, pp: 21-100.
17. Coles, E.H., 1986. "Veterinary Clinical Pathology" 4<sup>th</sup> Ed. W. B. Saunders Company, West Washington Square, Philadelphia, Toronto.
18. Tankeyul, B., C. Lamon, S. Kuptamethi and K. Choopanya, 1987. The reliability of field's stain as a hematological staining. *Journal of the Medical Association of Thailand*, 70: 136-141.
19. Reitman, S. and S. Frankel, 1957. A coloremtric method for determination of oxaloacetic transaminase and serum glutamic pyruvic transaminase. *American Journal of Clinical Pathology*, 28: 56-63.
20. Belfield, A. and D.M. Goldbery, 1971. A colorimetric determination of alkaline phosphatase activity. *Clinical Chemistry*, 12: 261.
21. Dumas, B.T., D.D. Bayso, R.J. Caster, T. Leters and R. Schaffer, 1981. Determination of serum total protein. *Clinical Chemistry*, 27: 1642.
22. Drupt, F., 1974. Dosage del albumin serque part vert de bromocresol. *Pharmaceutical Biology*, 111: 77.
23. Watson, D., 1965. Albumin and "total globulin" fraction of blood. In: *Advances in Clinical Chemistry*. (Stobotka, H. Stewart, C.P. eds.) Academic Press Inc. New York, 8: 238 - 249.
24. Tabacco, A., F. Meiattini, E. Moda and E. Tarli, 1979. Simplified enzymatic/colorimetric serum urea nitrogen determination. *Clinical Chemistry*, 25: 336-337.
25. Fabiny, D.L. and G. Ertingshausen, 1971. Automated reaction-rate method for determination of serum creatinine with certificated chemicals. *Clinical Chemistry*, 17: 696-700.

26. Bancroft, J.D. and A. Stevens, 1996. Theory and practice of histological technique. 4th Ed. Churchill, Livingstone, New York, London, San Francisco, Tokyo.
27. SAS, 2002. Statistical Analysis System. Version 9, SAS Institute Inc. Cary NC, USA.
28. Roy, B., U. Nondi, A. Das and T.K. Pal, 2011. Acute and twenty-eight days repeated oral dose toxicity study of besifloxacin in wistar albino rats. *Environmental Toxicology and Pharmacology*, 32: 82-101.
29. Saleemi, M.K., M.Z. Khan, I. Javed and A. Khan, 2009. Pathological effect of gentamicin administered intramuscularly to day-old broiler chicks. *Experimental and Toxicologic Pathology*, 61: 425-432.
30. Lovasti, M., C. Manzoni, M. Daldossi, S. Spotts and C. Svton, 1996. Effects of subchronic exposure of SO<sub>2</sub> on lipid and carbohydrate metabolism in rats. *Archives of Toxicology*, 70: 164-173.
31. Escobar, C. and C.B. Grindem, 2010. What is your diagnosis? Urine crystals in a dog. *Veterinary Clinical Pathology*, 39: 513-514.
32. Fadel, A.A. and H.A. Larkin, 1996. Gentamicin-induced nephrotoxicosis in lambs. *Research in Veterinary Science*, 61: 187-192.
33. Roy, B., A.K. Sarkar, P. Sengupta, G. Dey, A. Das and T.K. Pal, 2010. Twenty-eight days repeated oral dose toxicity study of gemifloxacin in wister albino rats. *Regulatory Toxicology and Pharmacology*, 58: 196-207.
34. Alarifī, S., A. Doaiss, S. Alkahatani, S.A. Alfarraj, A.M. Saad, B. Al-Dahmash, H. Al-Yahya and M. Mubarak, 2012. Blood biochemical changes and renal histological alterations induced by gentamicin in rats. *Saudi Journal of Biological Sciences*, 19: 103-110.
35. Khan, M.R., I. Badar and A. Seddiqah, 2011. Prevention of hepatorenal toxicity with sonchusasper in gentamicin treated rats. *BMC Complementary and Alternative Medicine*, 11: 113-121.
36. Bhusan, S.H., S.S. Ranjan, N. Sbhanganekar, S. Rakesh and B. Amrita, 2012. Nephroprotective activity of ethanolic extract of *Elephantopus Scaber* leaves on albino rats. *International Research Journal of Pharmacy*, 3: 246-250.
37. Latimer, K.S., E.A. Mahaffey and K.W. Prasse, 2003. *Veterinary Laboratory Medicine, Clinical Pathology*. 4<sup>th</sup> Ed. Iowa State Press.
38. Dinev, T., D. Zapryanova and L. Lashev, 2007. Some blood biochemical parameters in goats after aminoglycosides and aminocyclitol treatment at therapeutic doses. *Turkish Journal of Veterinary and Animal Sciences*, 31: 174-188.
39. Christo, J.S., A.M. Rodrigues, M.G. Mouro, M.A. Cenedez, M.D. Simoes, N. Schor and E.M. Higa, 2011. Nitric oxide is associated with gentamicin nephrotoxicity and the renal function recovery after suspension of gentamicin treatment in rats. *Nitric Oxide*, 24: 77-83.
40. Lopez-Novoa, J.M., Y. Quiros, L. Vicente, A.I. Morales and F.G. Lopez-Hernandez, 2011. New insight into the mechanism of aminoglycosides nephrotoxicity: an integrative point of view. *Kidney International*, 79: 33-45.
41. Ulinski, T., A. Sellier-Leclerc, E. Tudorache, A. Bensman and B. Aoun, 2011. Acute tubulointerstitial nephritis. *Pediatric Nephrology*, 80: 177-185.
42. Hung, C., M. Kuo, J. Chang and A. Chen, 2006. Fluoroquinolones-induced acute interstitial nephritis in immunocompromised patients: Two case reports. *Nephrology Dialysis Transplantation*, 21: 237-238.
43. Walker, R., S. Giguere, J. Prescott, J. Baggot and P. Dowling, 2007. *Antimicrobial therapy in veterinary medicine* 4<sup>th</sup> Ed. Blackwell publishing. pp: 263-284.
44. Rouas, C., J. Stefani, S. Grison, L. Grandcolas, C. Baudelin, I. Dublineau, M. Pallardy and Y. Gueguen, 2011. Effect of nephrotoxic treatment with gentamicin on rats chronically exposed to uranium. *Toxicology*, 279: 27-35.
45. Rehman, K., U. Saleem, B. Ahmed, G. Murtaza and M.S. Hamid Akash, 2012. Nephrocurative and nephroprotective effects of *Nigella Sativa* oil in combination with vitamin-C in gentamicin induced renal toxicity. *Indian Journal of Pharmaceutical Science & Research*, 2: 25-32.