Global Veterinaria 12 (5): 682-686, 2014
ISSN 1992-6197

DOI: 10.5829/idosi.gv.2014.12.05.8387

Diagnostic Investigations for Fatty Liver Syndrome in Egyptian Buffaloes

[1]*Hayam Ahmed Hussein,* [2]*Abdel Khalek Ramadan El-sheikh,*
[1,3]*Nabila Shaker Degheidy and* [2,4]*Mohamed Tharwat*

[1]Department of Parasitology and Animal Diseases,
Veterinary Research Division, National Research Center, Cairo, Egypt
[2]Department of Animal Medicine, Faculty of Veterinary Medicine,
Zagazig University, Zagazig, Egypt
[3]Department of Biology, Science Collage, Taif University, KSA
[4]Department of Veterinary Medicine, College of Agriculture
and Veterinary Medicine, Qassim University, KSA

Abstract: One hundred non pregnant female buffaloes (*Bubalus bubalis*), aged 4-8 years, were examined. Thirty healthy animals served as controls and 70 animals were diagnosed with fatty liver syndrome according to the clinical examination, liver ultrasonography, histopathological examination, blood contents and serum analysis. The clinical symptoms were anorexia, decrease in milk production, decrease in ruminal movement and rectal temperature. Moderate and severe hyperechogenicity of the hepatic parenchyma were clear in cases of moderate and severe fatty liver respectively after ultrasonographic examination. Post-mortem examination revealed enlarged pale yellow livers with rounded edges and presence of small droplets of fat. Microscopically, the hepatocytes showed diffuse fatty infiltration which had signet rings appearance due to the presence of intracellular droplets of triglycerides in liver cells. Blood picture showed a significant decrease in hemoglobin, RBCs and WBCs and significant increase in PCV ($p<0.05$). Serum analysis showed a significant decrease ($p<0.05$) in TP, albumin, ALT, TG and a significant increase ($p<0.05$) in GGT, globulin and AST. It was concluded that the ultrasonography, histopathology and clinical examination as well as blood picture and serum analysis support the diagnosis of fatty liver in non-pregnant buffaloes.

Key words: Buffaloes · Liver · Clinical · Ultrasonography · Histopathology

INTRODUCTION

Liver is considered the most important body organ for metabolism and mobilization of body fat and carbohydrates. Therefore, liver affections have been linked to major health problems in large ruminants and correlated with high incidence of liver condemnations in slaughter houses [1, 2]. Bobe *et al*. [3] stated that fatty liver syndrome is a major metabolic disorder in dairy cows in early lactation due to an insufficient nutrient uptake resulting in a negative energy balance and hormonal changes. The fatty liver syndrome has been associated with greater incidence of diseases, infections and inflammation. Therefore, El-sheikh *et al*. [4] defined the fat cow syndrome as a multifactoral condition occurring in dairy cows and characterized by anorexia, depression, weight loss, weakness, decreased ruminal motility and reduction of milk production as well as other signs of related diseases such as displaced abomasums, metritis, mastitis, parturient paresis and retained placenta.

Most of the blood and serum laboratory tests were found to be poor indicators of fatty liver syndrome in large ruminants [5]. In addition, Radostits *et al*. [1] stated that most cases with fat cow syndrome had no specific clinical signs such as depression, weight loss and decreased milk production and may have other clinical signs of related diseases such as metritis, retained placenta, milk fever and displaced abomasum. Among

Corresponding Author: Hayam Ahmed Hussein, Department of Parasitology and Animal Diseases,
Veterinary Research Division, National Research Center, El Buhouth St., Dokki,Cairo 12311, Egypt.

domestic farm animals, water Buffaloes ((*Bubalus bubalis*), have a great importance in the Egyptian agricultural system as they serve as the major source of milk and dairy products, besides providing meat and hides [6]. Ultrasonography has been extensively used as a diagnostic aid and to evaluate the liver in dairy cows [7-10] and recently in water buffaloes [11, 12]. Interestingly, Braun *et al*. [9] reported an increase in the number and intensity of the internal echoes in diffuse fatty liver disease in cattle. Similar findings have been reported by Tharwat [13] in buffaloes with fatty liver infiltration as liver ultrasonography has been initially validated for the diagnosis and prognosis of such affection in buffaloes. This work aimed to investigate the effect of fatty liver on general health condition, some blood constituents as well as to evaluate such cases in buffaloes using ultrasonographic and histopathological examinations.

MATERIALS AND METHODS

Animals: A total number of 100 non pregnant female Egyptian buffaloes, aged 4-8 years old, free from external and internal parasites were examined in this study. Animals were relevant to Zagazig Veterinary Teaching Hospital and Animal Production Research Institute, Ministry of Agriculture, BeniSuef Governorate, Egypt. Animals were classified according to the clinical, ultrasonography, post-mortem and histopathological examinations into two groups: control group; included 30 healthy animals and fatty liver group; included 70 animals suffering from fatty liver infiltration.

Sampling: *Blood samples:* Two blood samples were taken from each animal for hematological examination and separation of clear sera for colorimetric assay of alkaline phosphatase (ALP), aspartate aminotransferase (AST), L-alanine aminotransferase (ALT), triglycerides (TG), serum total proteins (TP), serum albumin, globulin and gamma glutamyltransferase (GGT). Fecal samples: fecal samples were also obtained for physical and parasitological examinations of faecesfor each animal according to the method described by Kelly [14].

Ultrasonographic Examination: The ultrasonographic examination was done according to the method described by Braun [15] using an ultrasound scanner (Pie-medical 240 Parus-Switzerland) connected to 3.5 - 5 MHz convex sector transducer or (Echo-son ultrasound) connected to a 5 MHz annular phased array transducer. The images were printed using Sony up-885 MD printer. Ultrasonographic coupling gel (SGMOSCAN, SGMO Chemical Industry, Egypt) was applied to the examined area of the skin to ensure that there is no air between the probe and animal skin. The hair was clipped between the sixth intercostals space to a hand's breadth behind the last rib and the skin was cleaned with alcohol to remove the fat debris. After application of transmission gel to the transducer, the buffalo cows were examined from the last right intercostals space cranially to the 6thintercostals space in the standing position. Each intercostals space was examined from dorsal to ventral with the transducer held parallel to the ribs. The texture of the visceral and diaphragmatic surfaces of the liver was scanned and the diameter and depth of the portal vein and caudal vena cava were measured.

Histopathological Examination: Liver specimens were obtained from 20 slaughtered animals, preserved in 10% neutral buffered formalin, processed through the conventional paraffin embedded technique, dehydrated through ascending grades of ethyl alcohol, cleared in different changes of xylene and embedded in paraffin wax at 60°C. Paraffin blocks were cut into sections of 4-6 microns thickness. The paraffin sections were stained by H&E. Histopathological examination was carried out according to the method described by Bancroft and Stevens [16].

Statistical Analysis: Data of the two buffalo groups was analyzed for the means and standard deviations using SPSS Statistical Software [17] and was compared using Student's t-test for normally distributed data and Mann-Whitney U test for skewed data. The significance was determined when $P<0.05$.

RESULTS AND DISCUSSION

Clinical Signs: The diseased buffaloes showed varying degree of slight increase in respiratory and pulse rate, decrease of ruminal movement and rectal temperature. Anorexia, loss of body weight, depression and decrease in milk production were observed in some cases as well (Table 1). The high variability found among animals interfered with detecting significant differences between the two examined groups. These findings have been previously attributed by Radostits *et al*. [1] to the mobilization of the body reserve to support high milk production soon post-partum and also to the decrease of ruminal and intestinal fill. However, similar non-specific

Table 1: Clinical signs of examined buffaloes.

Group	Respiratory rate/ minute	Pulse rate/ minute	Ruminal movement/ 2 minutes	Rectal Temperature °C	Mucous membrane	General appearance
Control	20-25	55-60	2	38.2-38.9	Slight rosy red	Animals appeared with good appetite, good body condition, normal hair & skin, without external parasites
Fatty liver	28-33	70-85	1-stasis	38-38.5	Slight rosy red	Depression, anorexia, weight loss and decrease in milk production.

Table 2: Haematoligical picture in examined buffaloes

Group	Hb g/dl	PCV%	RBCs million/ cu mm	WBCs thousands/cu mm
Control	11.00±0.03[a]	34.00±0.11[a]	8.00±0.12[a]	9.00±0.30[a]
Fatty liver	10.10±0.02[b]	38.10±0.03[b]	7.0±0.14[b]	8.00±0.04[b]

Means with different superscripts in the same column are significant different at least at P<0.05

Table 3: Biochemical analysis of the examined buffaloes

Group	AST U/L	ALT U/L	GGT U/L	ALP U/L	TG mg/dl	TP g/dl	Albumin g/dl	Globulin g/dl
Control	44.65±0.29[a]	12.03±0.01[a]	19.96±0.03[a]	25.03±0.10[a]	12.50±0.04[a]	8.98±0.03[a]	5.04±0.01[a]	3.94±0.03[a]
Fatty liver	79.98±0.23[b]	11.08±0.23[b]	39.43±0.26[b]	22.03±0.12[b]	3.93±0.26[b]	8.86±0.03[b]	4.56±0.01[b]	4.30±0.02[b]

Means with different superscripts in the same column are significant different at least at P<0.05

clinical signs and decline in the general health were frequently reported in buffaloes suffering from liver diseases other than fatty liver syndrome such as liver flukes [18].

Haematological Examination: There was a significant decrease (p<0.05) in the mean values of Hb and RBCs with a significant increase of PCV (p<0.05) in the affected buffaloes (Table 2). These findings may be attributed to cobalt and vitamin B_{12} deficiency that resulted in macrocytic normochromic anaemia and appeared in agreements with the findings of Andrews *et al*. [19]. The general suppression of total leucocytic count which caused by the significant decrease of WBCs (p<0.05) may be attributed to the disturbed carbohydrate/lipid metabolism as concluded by Reid *et al*. [20], or due to the increased prevalence of endometritis which is associated with high fat content of the liver as reported by Ahmed [21].

Biochemical Analyses: Serum analyses of affected buffaloes suffering from fatty liver infiltration showed a significant decrease (p<0.05) in total protein, albumin, ALT, TG and significant increase (p<0.05) of GGT, globulin and AST when compared to the analyses of control group (Table 3). The increase of AST level in fatty liver syndrome was attributed to the severe muscles and hepatic damage due to the lipid infiltration present in muscles and liver [18]. The significant decrease in the mean level of ALT (p<0.05) was in agreements with the findings of Sevinc *et al*. [22]. Furthermore, Stojevic*et al*. mentioned that the ALT activity in serum significantly decreased during early lactation [23]. A significant increase (p<0.05) in the mean value of GGT as well as significant decrease (p<0.05) in the mean value of ALP and TG were observed in buffaloes suffering from fatty liver infiltration. Similar results were reported by Smith [5], Nakagawa *et al*. [24] and Sevinc *et al*. [25]. Furthermore, the low levels of serum triglycerides were attributed by Sevinc*et al*. to the influx of free fatty acids from adipose tissues near the time of parturition and low output of lipoprotein by the liver [25]. The significant decrease (p<0.05) in the total serum protein and albumin and the significant increase (p<0.05) in serum globulins in animals suffering from fatty liver infiltration came in agreement with the findings reported by Sevinc *et al*. [26]. The authors attributed these findings to the loss of albumin fractions in such inflammatory toxic conditions and/or the increase of serum globulins as a response of antibody producing mechanism.

Ultrasonographic Examination: Ultrasonographic examination of fatty liver group revealed varying degrees of fatty infiltration. Livers with moderate fatty infiltration showed moderate hyperechogenicity of the hepatic parenchyma within which the portal and hepatic veins were moderately visible (Fig. 1). While livers with severe fatty infiltration showed severe isoechoichyper echogenicity of the hepatic parenchyma and the portal and hepatic veins could not be imaged at all (Fig. 2). Similar results were found by Acorda *et al*. [27] and Braun *et al*. [9], they attributed this to the swollen hepatic tissue that was compressing the blood vessels and to the increase in the scattered echoes in the hyperechoic areas

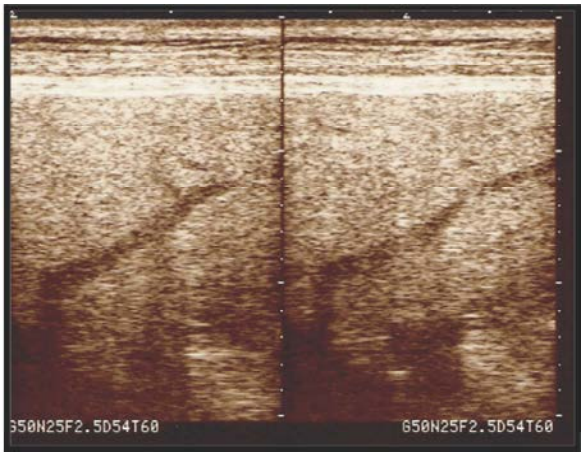

Fig. 1: Ultrasonogram of the liver in a buffalo cow with moderate fatty liver taking from the right 11th ICS with a 5 MHz convex transducer showing moderate hyperechogenicity of the hepatic parenchyma where the portal and hepatic veins are moderately visible.

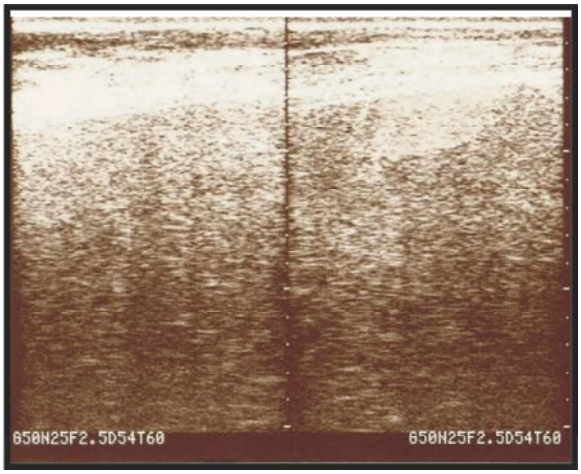

Fig. 2: Ultrasonogram of the liver in a buffalo cow with severe fatty liver taking from the right 11th ICS with a 5 MHz convex transducer showing severe isoechoichyper echogenicity of the hepatic parenchyma where the portal and hepatic veins could not be imaged at all.

of the diseased liver, these echoes projected onto the vessels resulting in deteriorating of the contrast between the hepatic parenchyma and hepatic vessels. Moreover, the ultrasonographic features of normal and fatty infiltrated livers in buffaloes were similar to those illustrated by Constante and Acorda [11] and Tharwat [13] and provided further validation for the use of liver ultrasonography as an accurate and semi-quantitative diagnostic aid of that syndrome in buffaloes.

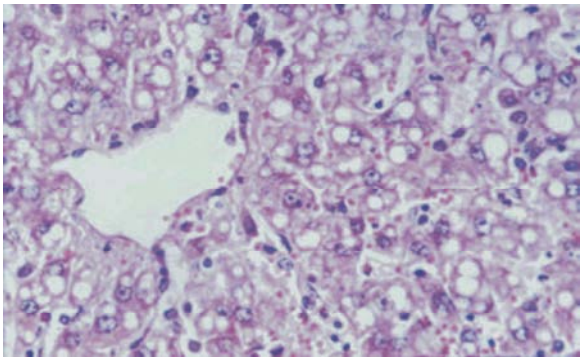

Fig. 3: Liver of buffaloes showing diffuse fatty infiltration with signet rings appearance. (H&E X200).

Gross and Histopathological Examination: Post-mortem examination of some livers within the fatty liver group showed enlarged and pale yellow livers with rounded edges. Small droplets of fat in the periportal and Juxasinusoidal position were also found. Microscopically, intracellular droplets of triglycerides were found in liver cells (Fig. 3), the hepatocytes showed diffuse fatty infiltration which had signet rings appearance. These findings were in agreements to the gross and histopathological findings reported in cattle [19] and buffaloes [13] with fatty liver syndrome.

CONCLUSION

In conclusions, the findings of this study emphasize the need for ultrasonography and/or histopathology as diagnostic aids in association with the clinical, haematological and biochemical examinations for diagnosis of fatty liver syndrome in buffalo cows.

ACKNOLEDGMENTS

Thanks to Dr. Sherein Saied Abd El-Gayed, Assistant Professor of Animal Pathology, Faculty of Veterinary Medicine, Cairo University, who provided help in the histopathological examination.

REFERENCES

1. Radostits, O.M., C.C. Gayand K.W. Hinchcliff, 2007. Veterinary medicine: A textbook of the diseases of cattle, horses, sheep, pigs and goats. Elsevier Science Health Science Div., London.
2. Nagaraja, T.G. and M.M. Chengappa, 1998. Liver abscess in feedlot cattle: A review. J. Anim. Sci., 76: 287-298.

3. Bobe, G., J.W. Young and D.C. Beitz, 2004. Invited review; Pathology, etiology, prevention and treatment of fatty liver in dairy cows. J. Dairy Sci., 87: 3105-3124.
4. El-Sheikh, A.R., H. Attia and H. Selim, 2004. Textbook of Veterinary Internal Medicine, Shahwan Office, Zagazig, Egypt.
5. Smith, B.P., 2008. Large animal internal medicine.4th Ed., Mosby, London.
6. General Organisation for Veterinary Services (GOVS), Technical Veterinary Report 2005, Cairo, Egypt.
7. Braun, U., A. Pospischil, N. Pusterla and C. Winder, 1995a. Ultrasonographic findings in cows with cholestasis. The Vet. Rec., 137: 537-543.
8. Braun, U., N. Pusterla and K. Wild, 1995. Ultrasonographic findings in 11 cows with a hepatic abscess. The Vet. Rec., 137: 284-290.
9. Braun, U., N. Pusterla and K. Wild, 1996. Ultrsonographic examination of the liver and gallbladder in cows; abnormal findings. The Compendium, 18(11): 1255-1269.
10. Braun, U., K. Nuss, G. Soldati and P. Ossent, 2005. Clinical and ultrasonographic findings in four cows with liver tumors. The Vet. Rec., 157: 482-484.
11. Constante J.L. and J.A. Acorda, 2012. Ultrasound features of the spleen, liver and kidney of Bulgarian Murrah buffaloes (Bubalus bubalis L.) at different stages of lactation. Philipp J. Vet. Anim. Sci., 38(1): 73-84.
12. Tharwat, M., 2012. Ultrasonographic findings in cattle and buffaloes with chronic hepatic fascioliosis. Tropical Animal Health and Production, 44(7): 1555-60.
13. Tharwat, M., 2012. Ultrasonography as a diagnostic and prognostic approach in cattle and buffaloes with fatty infiltration of the liver. Polish Journal of Veterinary Sciences, 15(1): 83-93.
14. Kelly, W.R., 1974. Veterinary Clinical Diagnosis. 2nd Ed., BailliereTindall, London.
15. Braun, U., 2009. Ultrasonography of the liver in cattle. VFP Veterinary Clinics of North America: Food Animal Practice, 25(3): 591-609.
16. Bancroft, J.D. and A. Stevens, 1996. Theory and practice of histological technique. 4th Ed., Churchill Livingstone, London.
17. SPSS, 2007. Statistical Package for Social Sciences, SPSS Inc., Chicago, IL, USA Copyright© for Windows, version 16.0.
18. El-Khadrawy, H.H., W.M. Ahmed, F.M. ElMoghazy and M.M. Abd El Aziz, 2008. Field investigation on the correlation between ovarian activity and fascioliosis in buffalo-cows. Am.Eurasian J. Agric. Environ. Sci., 3(4): 539-546.
19. Andrews, A.H., R.W. Blowey, H. Boyd and R.G. Eddy, 2004. Bovine medicine, diseases and husbandry of cattle. 2nd Ed., Blackwell, Oxford.
20. Reid, I.M., G.J. Rowlands, A.M. Dew, R.A. Collins, C.J. Roberts and R. Manston, 1983. The relationship between post-parturient fatty liver and blood composition in dairy cows. J. Agri. Sci. Camb., 10: 104-110.
21. Ahmed, M.I., 2004. Examination of different diagnostic methods and significance of fatty liver at clinically diseased dairy cows and its relation to hypophosphatemia. PhD thesis, Clinic of cattle, faculty of Vet. Med., Free University Berlin.
22. Sevinc, M., I. Oztok, M. Sandikc and F. Birdane, 1998. The clinical chemical parameters, serum lipoproteins and fatty infiltration of the liver in ketotic cows. Tr. J. Vet. Anim. Sci., 22: 443-447.
23. Stojevic, Z., J. Pirsljin, M. Suzana and B. Blarka, 2005. Activities of AST, ALT and GGT in clinically healthy dairy cows during lactation and in the dry period. Veterinarski Arhiv, 75(1): 67-73.
24. Nakagawa, H., O. Yamamoto, S. Oikawa, H. Higuchi, A. Watanabe and N. Katoh, 1997. Detection of serum haptoglobin by enzyme-linked immunosorbent assay in cows with fatty liver. Research in Veterinary Science, 62: 137-141.
25. Sevinc, M., A. Basoglu, H. Guzelbektas and M. Boydak, 2003. Lipid and lipoprotein levels in dairy cows with fatty liver. Turk. J. Vet. Anim. Sci., 27: 295-299.
26. Sevinc, M., A. Basoglu, F.M. Birdane and M. Boydak, 2001. Liver function in dairy cows with fatty liver. Revue Med. Vet., 152(4): 297-300.
27. Acorda, J.A., M.H. Yamada and S.M. Ghamsari, 1994. Evaluation of fatty infiltration of the liver in dairy cattle through digital analysis of hepatic ultrasonograms. Vet. Radiol. & ultrasound, 35: 120-123.