

Comparative Study of Anatomy of Renal Artery in Correlation with the Computed Tomography Angiogram

¹P. Sasikala, ¹S. Sulochana, ¹T. Rajan, ²J. Mohan and ³S. Melani Rajendran

¹Department of Anatomy, Arupadaivedu Medical College and Hospital, Kirmapakkam, Puducherry, India

²Department of Pharmacology, Arupadaivedu Medical College and Hospital, Kirmapakkam, Puducherry, India

³Department of Anatomy, Sri Ramachandra Medical College And Research Institute,
Sri Ramachandra University, Chennai, India

Abstract: The variations in origin of renal arteries are very common. The present study was focused to study renal artery and accessory renal artery in correlation with CT Angiography which provides the incidence and characteristics of variations of the renal arteries in cadavers and in patients who underwent angiography for donor nephrectomy. The origin and termination of the renal artery along with incidence, origin, course and termination of accessory renal arteries were studied in detail by dissection and CT angiography. Axial images alone are not sufficient for the evaluation of renal artery because they often have a tortuous and variable course. Additional views provided by CT angiography allow for display of the renal arteries in multiple planes and projections.

Key words: Renal Artery • Accessory Renal Artery • Ct Angiography • Renal Vein

INTRODUCTION

Number of renal transplantation is increasing rapidly over the last three decades. Anatomy of the renal arteries and its variations, the presence of accessory renal arteries has become a topic of interest for both anatomists and clinicians in the recent past, especially with the advent of renal transplantation, urological, vascular and oncological surgeries and also important in the treatment of renal trauma and renovascular hypertension. A thorough knowledge of the renal arteries is helpful for the smooth conduct and interpretation of interventional radiological procedures and can avoid unexpected complications during surgery. Several studies have been conducted over the last few years correlating the CT Angiography, MR Angiography and conventional angiographic anatomy with the surgical findings, the cadaveric studies have shown vivid type of patterns. Although a number of studies were carried out in relation to the renal artery, to add more information, the present study was focused to study renal artery and accessory renal artery in correlation with CT Angiography which will help the surgeons by

providing the incidence and characteristics of variations of the renal arteries in cadavers and in patients who underwent angiography for donor nephrectomy.

MATERIALS AND METHODS

The present study was carried out in the departments of Anatomy and Radiology and Imaging Sciences of Sri Ramachandra Medical College and Research Institute, Sri Ramachandra University, Chennai between the year 2006 and 2008; 25 dissected cadavers (19 males and 6 females) were used for research. In the Department of Radiology, a prospective non-randomized study involving 25 patients who came for renal angiography during the above period. The age was in between 25-62 years (16 males and 9 females). Detailed angiographic procedure and probable complications were explained and the informed consent was received from all without additional interventions on the patients.

The following patients were included for the study - the patients had undergone angiography for the following reasons

- Willing for donor nephrectomy
- Aneurysm of the abdominal aorta
- Suspicion of renovascular hypertension

Methods

Routine Dissection of the Cadavers: During routine dissection of the cadavers, the kidney was approached through the anterior abdominal wall. Peritoneal cavity was entered after reflecting the muscles and parietal peritoneum. The following organs, the stomach, small intestine, liver, pancreas and spleen were removed. The fat and the fascia over the anterior surface of the kidneys, abdominal aorta and inferior vena cava were cleaned. The right and the left renal veins from the hilum to inferior vena cava were traced. The origin of renal artery from the abdominal aorta was traced and its vertebral level of origin was noted. Then it was traced to its termination to find out whether it enters the hilum or gives early branching before entering the hilum. Accessory renal artery if any was traced from its origin. Its vertebral level of origin, side, course, termination and its association with congenital anomalies were noted. All the main renal arteries, accessory renal arteries and renal veins were painted with red and blue acrylic paint and photographed.

CT Angiographic Study: 64 Slice VCT xt High Speed advantage scanner, Helical computed tomography [General Electric Medical Systems, Milwaukee, USA] consists of slice thickness (5mm); slice interval (5mm); KVP(120); MA(Auto MA); smart preparation location (Abdominal aorta above the celiac arteries); monitor location (point of start of kidneys); Enhancement threshold (150 Hu); Contrast - 80 ml of Iodine [Inj. Iomeron 400] were used.

Procedure: All studies were performed at VCT xt 64 slice scanners. The study was performed after 4 hours fasting in all patients and reviewing their basic reports especially renal function test. Venous access was obtained in the preparation room using an 18G intravenous catheter in the antecubital vein. The subjects were trained to hold their breath with special attention to avoid diaphragmatic motion. Patient was placed in supine position. A plain topogram of the abdomen was first obtained in antero - posterior view and lateral scout from T11 to pubic symphysis. On a frontal scout view was performed using 5mm section thickness, 120 KVP, auto MA, 0.8 S Scan time and image acquisition at 5mm intervals from

diaphragm to pubic symphysis during a single breath hold. Using these images, the scanning range was determined from the coeliac axis to aortic bifurcation, including the entire kidneys bilaterally. The cursor was placed at a predetermined location in the abdominal aorta. The scan was started and an angiographic phase was obtained at the time of peak density due to contrast. This was assessed by using an automated bolus tracking software. 80ml of Inj. Iomeron 400 was injected at a rate of 4.5 ml/sec with a power injector. Helical CT scan was performed for arterial phase after 18-22 sec at 5mm slices, pitch 0.935 and venous phase after 45-50 seconds. The images were then reconstructed at 5mm intervals with segmented interpolation yielding 180-240 images which was sent to the workstation on the network. After 2.5 minutes delayed phase was taken to assess the collecting system and the ureters.

CT Interpretation and 3D Processing: The unenhanced' the contrast-enhanced axial images were first viewed using cine paging for the arterial anatomical variants. The data was loaded for 3-D processing, surface shaded display and maximum intensity projection images were then generated.

The following parameters were assessed as in the cadaver:

- Origin of renal artery and its vertebral level
- Mode of termination of the renal artery
- Incidence of accessory renal artery
- Origin of accessory renal artery and its vertebral level
- Course of the accessory renal artery
- Mode of termination of the accessory renal artery
- Association of accessory renal artery with congenital anomalies.

Observations: The observations of the renal arteries of 25 cadavers and 25 angiographic studies were statistically analyzed.

Origin of Renal Artery and its Vertebral Level: The renal artery originated from the abdominal aorta in all the cadavers and CT angiograms (Fig.1) except for one with pelvic kidney which arise from right common iliac artery (Fig.2). The vertebral level of origin was most commonly at the level of L1-L2 vertebra in 40% on both sides, L1 vertebra in 34% on right side and 26% on left side, L2 vertebra in 22% on right side and 34% on left side, L2-L3 in 2% and L4-L5 in 2% (Fig.3 and 4) on right side only.

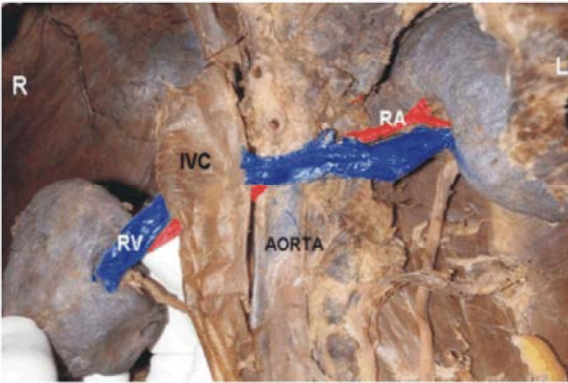


Fig. 1: Cadaveric image showing normal renal arterial pattern

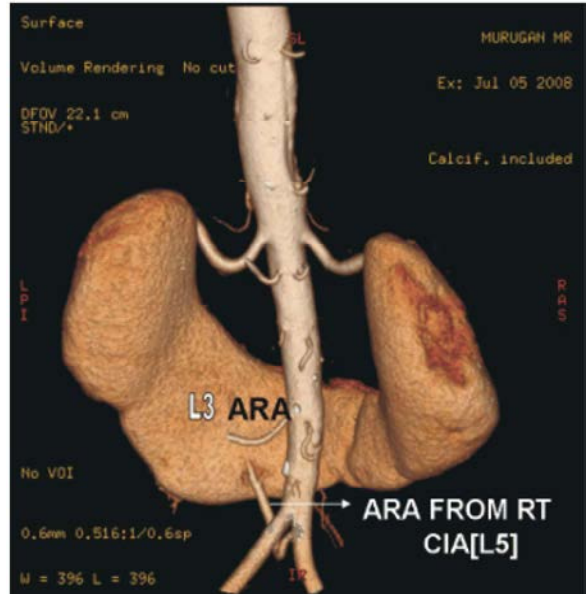


Fig. 4: CTAngiogram showing right pelvic kidney with Accessory renal artery on both sides, right arising from right common iliac artery

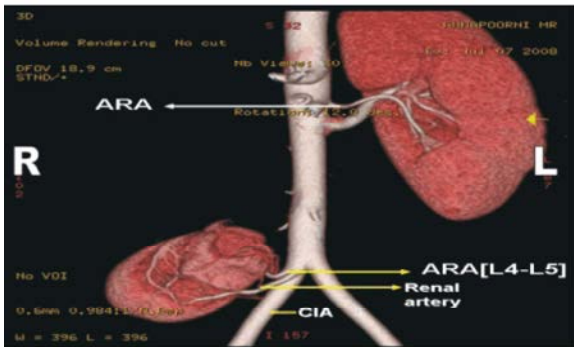


Fig. 2: CTAngiogram showing right pelvic kidney with Accessory renal artery on both sides, right arising from right common iliac artery

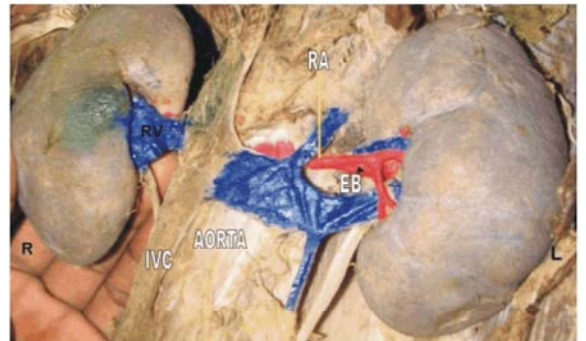


Fig. 5: Normal renal arterial pattern on right side with early branching on left side

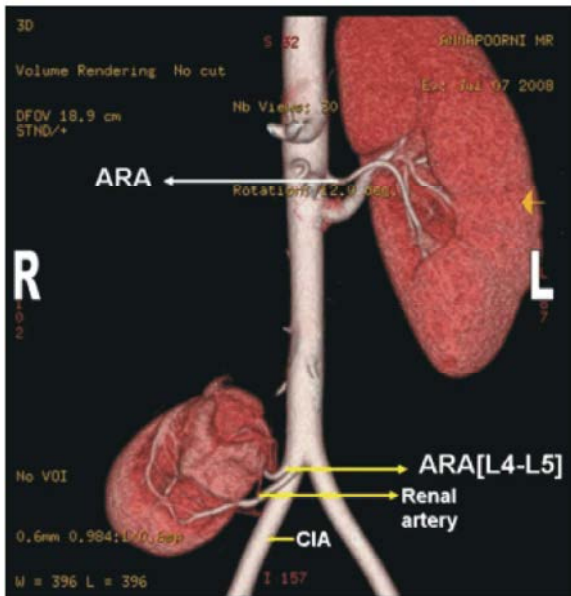


Fig. 3: CTAngiogram-- horse shoe kidney with 2 accessory renal artery – posterior view

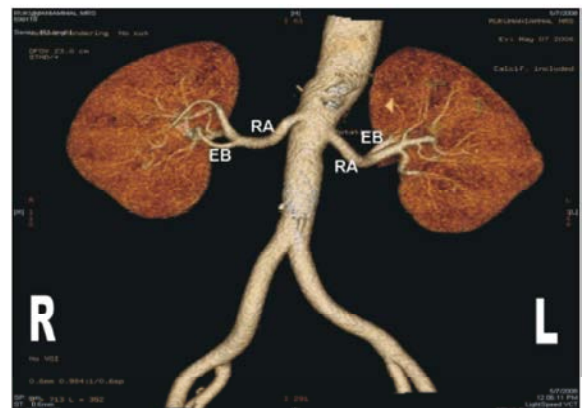


Fig. 6: CTAngiographic image showing early branching pattern of renal artery

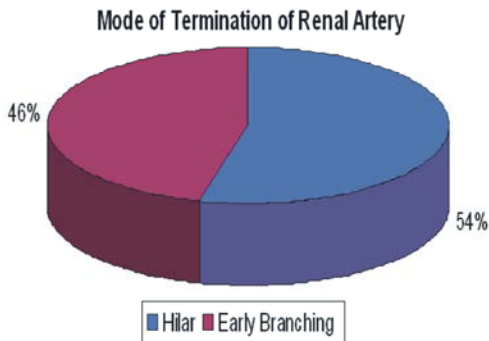


Chart 1:

Table 1: Mode of termination of the renal artery

	Cadaveric	Angiographic	%
Hilar	28	26	54%
Early branching	22	24	46%

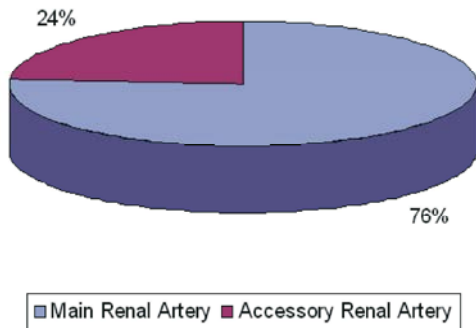


Chart 2:

Table 2: Incidence of accessory renal artery(2)

	Number of subjects	(%)
Main renal artery	38	76
Accessory renal artery	12	24

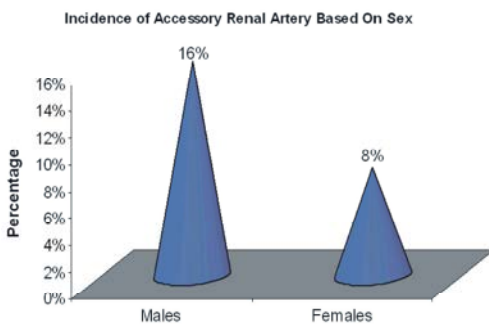


Chart 3:

Table 3: Accessory renal artery based on sex

	Males	Females
Cadaveric	3	1
Angiographic	5	3
Percentage (%)	16	8

Chart : 5 Incidence of Accessory Renal Artery Based on Side

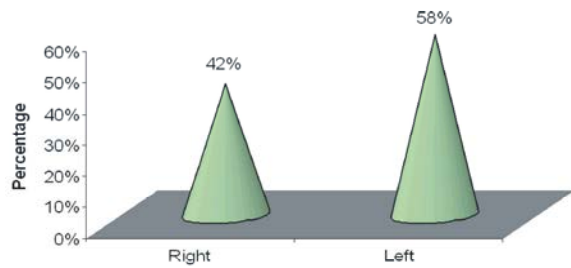


Chart 4:

Table 4: Based on side accessory renal arteries

Side	Cadaveric		Angiographic		Total(%)
	Number	%	Number	%	
Right	2	50%	3	37.5%	41.7%
Left	2	50%	5	62.5%	58.3%

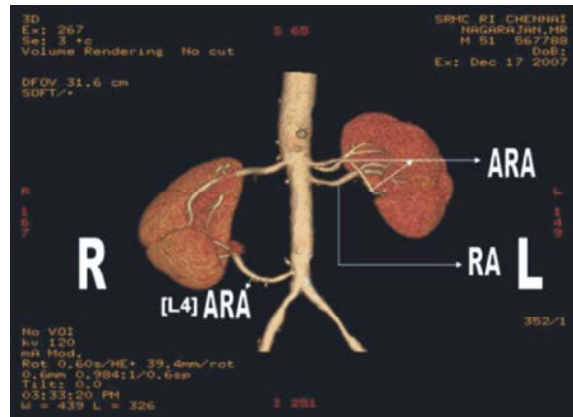


Fig. 7: CT Angiogram showing triple renal artery on left and double on right to hilum

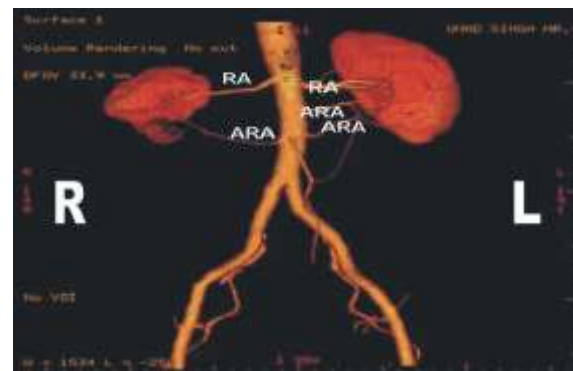

Fig. 8: CT angiographic image showing triple renal arteries on left side and double on right side

Mode of Termination of the Renal Artery:
The termination of the renal artery into segmental branches more proximally than the renal hilar level, called

early division found in 46% (Fig.5 and 6) and renal arteries entered the hilum before its division in 54% (Table 1 and Chart.1).

Incidence of Accessory Renal Artery: The presence of accessory renal artery was observed in 12 subjects out of 50. The percentage of renal artery was observed in 76% and accessory renal artery was found in 24% (Table 2 and Chart.2).

Based on Sex: The accessory renal artery was found more in males (16%) than in females (8%) (Table no.3 and Chart 3).

Based on Side: Accessory renal arteries were found on the right side in 41.7%, on the left side in 58.3% (Figs.7 and 8) (Table no. 4 and Chart.4).

DISCUSSION

Knowledge of the Embryology of the renal vasculature and structural development of the kidney is essential for the understanding of the multitude of anomalies that may occur. The anatomical variations of the renal artery will have a lot of clinical importance in the cases of renal transplantation, which was studied in the cadavers and CT angiograms in a study group of 50 subjects. The study reports were compared with the previous studies.

Origin of the Renal Artery and its Vertebral Level: Keith L. Moore and Arthur F. Dalley [1] stated that the renal artery generally originates from the abdominal aorta, just below the superior mesenteric artery at the level of L1- L2 vertebrae. Ozkan *et al.* [2] in a study found that 98% of the main renal artery originated between the upper margin of L1 and the lower margin of L2 vertebrae. In the present study, the main renal artery originated from the abdominal aorta just below the superior mesenteric artery at the level of L1 and L2 vertebra in 40% cases on both sides, L1 vertebra in 34% on right side and 26% on left side, L2 vertebra in 22 % on right side 34% on left side, which correlates with the statement of Keith L. Moore and Ozkan.

Mode of Termination of Renal Artery: Sampaio and Passos [3], stated that 53.3% of single hilar renal artery and 14.3% of single hilar artery with one superior pole extra hilar branch. Ozkan *et al.* [2] observed early division of renal artery in 8% of the cases. But in our study, single hilar artery in 56% cases and early branching in 44% cases,

which shows a higher rate of early branching than earlier studies.

Incidence of Accessory Renal Artery: Sykes [4] and Williams [5], stated that average rate of occurrence of accessory renal arteries is approximately 30%. Keith L. Moore and Arthur F. Dalley [1] described that variations in the number and position of the accessory renal vessels occur in approximately 25% of people. Troppmann [6] in a study noted multiple renal arteries in 21 (27%) of all kidneys. In the present study, accessory renal artery was observed in 24% of cases which almost correlates with the previous studies.

Based on Sex: Satyapal *et al.*, stated that sex incidence of accessory renal artery was 33.1% in males and 20.2% in females. In the present study, sex incidence of accessory renal artery was 16% in males and 8% in females which is not so dissimilar from the previous study.

Based on the Side: G. Singh and B.H. Bay [7], observed that the accessory renal arteries are found frequently on the left side and occurring in as high as 30-35%. Satyapal *et al.* [8] showed the incidence of additional renal arteries was 27.7% and occurred more frequently on the left (left-32%) than on the right (right-23.3%). In our study, the incidence of accessory renal artery shows the presence more predominantly on the left side 42% and right 58% which correlates more or less with the previous studies.

CONCLUSION

Advances in surgical and uro-radiological techniques dictate a reappraisal and definition of renal artery variations. In the present study, the origin and termination of the renal artery along with incidence, origin, course and termination of accessory renal arteries were studied in detail by dissection and CT angiography. Axial images alone are not sufficient for the evaluation of renal artery because they often have a tortuous and variable course. Additional views provided by CT angiography allow for display of the renal arteries in multiple planes and projections. This information is exceedingly important to the surgeons in planning treatment strategies.

REFERENCES

1. Keith, L. Moore and A.F. Dalley, 1999. in: Clinical oriented Anatomy, 4thed; Lippincott Williams and Wilkins company, pp: 286-288.

2. Ozkan, U., L. Oğuzkurt, F. Tercan, O. Kızılkılıç, Z. Koç and N. Koca, 2006. Renal artery origins and variations: angiographic evaluation of 855 consecutive patients. *Diagn Interv Radiol.*, 12: 183-186.
3. Sampaio, F.J. and M.A. Passos, 1992. Renal arteries: Anatomic study for Surgical and Radiological practice. *Surg Radiol Anat.*, 14(2): 113-7.
4. Sykes, D., 1963. The Arterial supply of Human kidney with special reference to accessory renal arteries, *British Journal of Surgery*, 50: 368-74.
5. Williams, 2005. in: *Gray's Anatomy-The Anatomical Basis of Clinical Practice*, 39th edition, Churchill Living stone, pp: 1044-1274.
6. Troppmann, C., 2001. Increased transplantation of kidneys with multiple renal arteries in the laproscopic live donor nephrectomy era, Surgical technique, surgical And non surgical donor and recipient outcomes, *Archsurge*, 136(8): 897-907.
7. Singh, G. and B.H. Bay, 1998. Bilateral accessory renal arteries associated with some anomalies of the ovarian arteries:a case study, *Clin Anat.*, 11: 417-20.
8. Satyapal, K.S., A.A. Haffejee and B. Singh, 2001. Additional renal arteries incidence and morphometry. *Surg Radiol Anat.*, 23(1): 33-38.