

Effect of Ethanol Extract of *Ruspolia hypocrateriformis* Leaf on Haematological Parameters in Lead Poisoned Albino Rats

¹O.U. Orji, ¹U.A. Ibiam, ¹P.M. Aja, ²O.D. Obasi,
¹N. Ezeani, ³C. Alope, ¹S. Anayo and O.R. Inya-Agha

¹Department of Biochemistry, Ebonyi State University, Abakalik, Nigeria

²Department of Medical Laboratory Science, Ebonyi State University, Abakalik, Nigeria

³Department of Medical Biochemistry, Federal University, Ndufu-Alike Ikwo, Ebonyi State, Nigeria

Abstract: This study evaluated the effect of ethanol extract of *Ruspolia hypocrateriformis* leaf on haematological parameters of albino rats poisoned with lead acetate. The haematological parameters were determined by automated haematological analyzer (Mindray-DC-2800). Twenty four albino rats were used for the investigations. The rats were randomly assigned to four experimental groups A, B, C and D, with six rats in each group. Group A were administered distilled water and served as positive control. Group B were treated with lead acetate (75mg/kg) alone. Group C were treated with ethanol extract of *Ruspolia hypocrateriformis* leaves at a dose of 250mg/kg and lead acetate as in B, while group D was treated with ethanol extract of *Ruspolia hypocrateriformis* leaves at a dose of 500mg/kg and lead acetate. The result shows that lead acetate caused significant ($P < 0.05$) increase in Platelet counts. It reveals further that the lead acetate produced significant ($P < 0.05$) decrease in the level of HB, PCV, WBC, RBC, MCV, MCH, MCHC, Neutrophil, Basophil, Eosinophil, Lymphocyte and Monocyte. The co-administration of the lead acetate and ethanol extract of *Ruspolia hypocrateriformis* leaves caused significant increase of the parameters showing a near reversal; hence supplementation of *Ruspolia hypocrateriformis* at 250mg/kg and 500mg/kg daily may help in management of lead poisoning.

Key words: *Ruspolia hypocrateriformis* • Lead poisoning • Haematological parameters

INTRODUCTION

Lead poisoning (also known as plumbism, colica pictorum, saturnism, devon colic, or painter's colic) is a type of metal poisoning and a medical condition in humans and other vertebrates caused by increased levels of the heavy metal lead in the body [1]. Lead poisoning is a medical condition that occurs when people are exposed to lead compounds through inhalation, swallowing and rarely, through the skin and it usually starts with repeated exposure to small amounts of lead [2]. Indeed lead is a highly toxic substance, exposure to which can produce a wide range of adverse health effects [3]. It interferes with a variety of body processes and is toxic to many organs and tissues including the heart, bones, intestines, kidneys and reproductive and nervous systems. It also interferes with the development of the nervous system and is therefore particularly toxic to children, causing potentially

permanent learning and behavior disorders. Symptoms include abdominal pain, confusion, headache, anemia, irritability and in severe cases seizures, coma and death. Childhood lead poisoning is a preventable environmental health problem. All children between six months and three years of age should be screened for lead poisoning [4].

Both adults and children can suffer from the effects of lead poisoning, but childhood lead poisoning is much more frequent [4]. Over the years since the knowledge about the hazards of lead came to limelight, tens of millions of children have suffered its health effects. Even today, in 2008, there are still an estimated 310, 000 children under the age of six who have too much lead in their blood [5].

Generally, the alterations in haematological parameters serve as the earliest indicators of the effect of toxins on tissues. Blood is the most important tissue, in which changes in metabolic processes are reflected,

therefore, abnormal alteration in blood parameters are one of the reliable indicator of toxic effects of drugs, chemicals and diseases on the body system. Herbal medicine involves the use of herbs and plant parts (roots, stems, leaves, barks, or even fruits) to promote and improve health [6]. Use of plant and plant products in traditional medicinal practices on the African continent and beyond dates as far back as 6000 years probably since the first man on earth and were the sole medical systems for health care before the introduction of orthodox medical system. Plants and their products even serve as one of the basic raw material for the development of modern drugs. Thus medicinal plants have been used in many years in daily life to treat diseases all over the world [7].

Ruspolia hypocrateriformis belongs to the family Acanthaceae. A straggling shrub, about 1m high found in the savanna and secondary and deciduous forest areas from Senegal to West Cameroon and dispersed to Uganda, Kenya and Transvaal [8]. The plant is distinctly ornamental. The flowers are borne in showy terminal inflorescences with coral-red tubular flowers 3.75 cm long. A cultivar grown in America is predominantly yellow with lobes crimson on the outer side [9].

It is rare small shrub from tropical and southern Africa with 1 inch tubular red flowers in spikes. It blooms over many months in summer [10], will grow to 3 feet high and wide in bright shade with rich, moist soil. *Ruspolia hypocrateriformis* has smooth leaves with angled stems, compared to the slightly hairy leaves and round stems of *Ruspolia seticalyx*. *Ruspolia hypocrateriformis* is also a more robust plant. Otherwise, they are very similar and easily misidentified [11].

MATERIALS AND METHODS

Ethical Clearance: The method of the experiment was approved by the Institutional Animal Ethical Committee according to guidelines given by the Committee for the Purpose of Control and Supervision of Experiments on Animals (CPCSEA).

Biological Materials: *Ruspolia hypocrateriformis* leaves and twenty four albino rats were used for the study.

Chemicals and Reagents: All the chemicals and reagents used were of analytical grade.

Collection and Authentication of the Plant: Fresh samples of *Ruspolia hypocrateriformis* leaves were collected from a garden at senior staff quarters, Udensi, Abakaliki

Local Government area of Ebonyi State, south eastern Nigeria from September 2015 - November 2015 and were identified by Mr. Ozioko a taxonomist of the International Bio-resources and Research Center, Nsukka, Nigeria.

Preparation of *Ruspolia hypocrateriformis* Leaf Sample:

Sample of *Ruspolia hypocrateriformis* leaves collected were washed and shade dried under room temperature. The dried leaves were then pulverized into fine granules using manual grinder and sieved using 0.25mm sieve. The powdered leaves weighing 100g were soaked in 500ml of ethanol at room temperature for 24hours. After 24hours, the extract obtained was filtered using sieve cloth. The filtrates were pooled and evaporated at 40°C. The ethanol extract weighing 5g was subsequently dissolved in distilled water of volume 10ml to obtain the stock solution of 0.5g/ml.

Preparation of Lead Acetate: Lead acetate was gotten from biochemistry laboratory, Ebonyi State University Abakaliki, Ebonyi state. 5g of lead acetate was weighed out and dissolved in 50ml of distilled water.

Animals Handling and Experimental Design: Twenty four (24) adult albino rats weighing between 70- 175g (8-12 weeks old) were purchased from a farm at Awka in Anambra State, Nigeria and housed at the animal farm of the Department of Biochemistry, Ebonyi State University, Abakaliki. They were randomly distributed into four (4) groups (A-D) of six (6) animals each identified with permanent markers of different colours. The animals were acclimatized for two weeks (21 days) on a regular feed (grower mash – Guinea feed), clean water was provided daily and access was free. Proper sanitation was maintained in the animal house to ensure healthy and clean environment. The animals were administered different doses of the extract for fourteen (21days) base on varying individual body weight. Illustrated further as;

Group A: Control (Normal, Untreated), received distilled water without any treatment.

Group B: Lead acetate treated group, received freshly prepared 75mg/kg body weight for 21 days.

Group C: Received 250mg/kg of *Ruspolia hypocrateriformis* extract + lead acetate as in group B.

Group D: Received 500mg/kg of *Ruspolia hypocrateriformis* extract + lead acetate as in group B.

In this study, all the animal experimentations were strictly carried out following the guidelines for the care and use of laboratory animals obtained from the Institutional Animal Ethics Committee of Ebonyi State University.

Collection of Blood Sample: The blood samples were collected through cardiac puncture into EDTA bottles after mild anesthesia using diethyl ether and were used for the measurement of the haematological parameters.

Haematological Analysis: Full blood counts including Red Blood Cells (RBC), Packed Cell Volume (PCV), haemoglobin (Hb), White Blood Cells (WBC), platelet count, differential WBC (including lymphocytes, neutrophils, monocytes and eosinophils) and red cell indices, including Mean Corpuscular Volume (MCV), Mean Corpuscular Haemoglobin (MCH), Mean Cell Haemoglobin Concentration (MCHC), were estimated using the Mindray hematological automatic Analyzing machine, DC-2800.

RESULTS

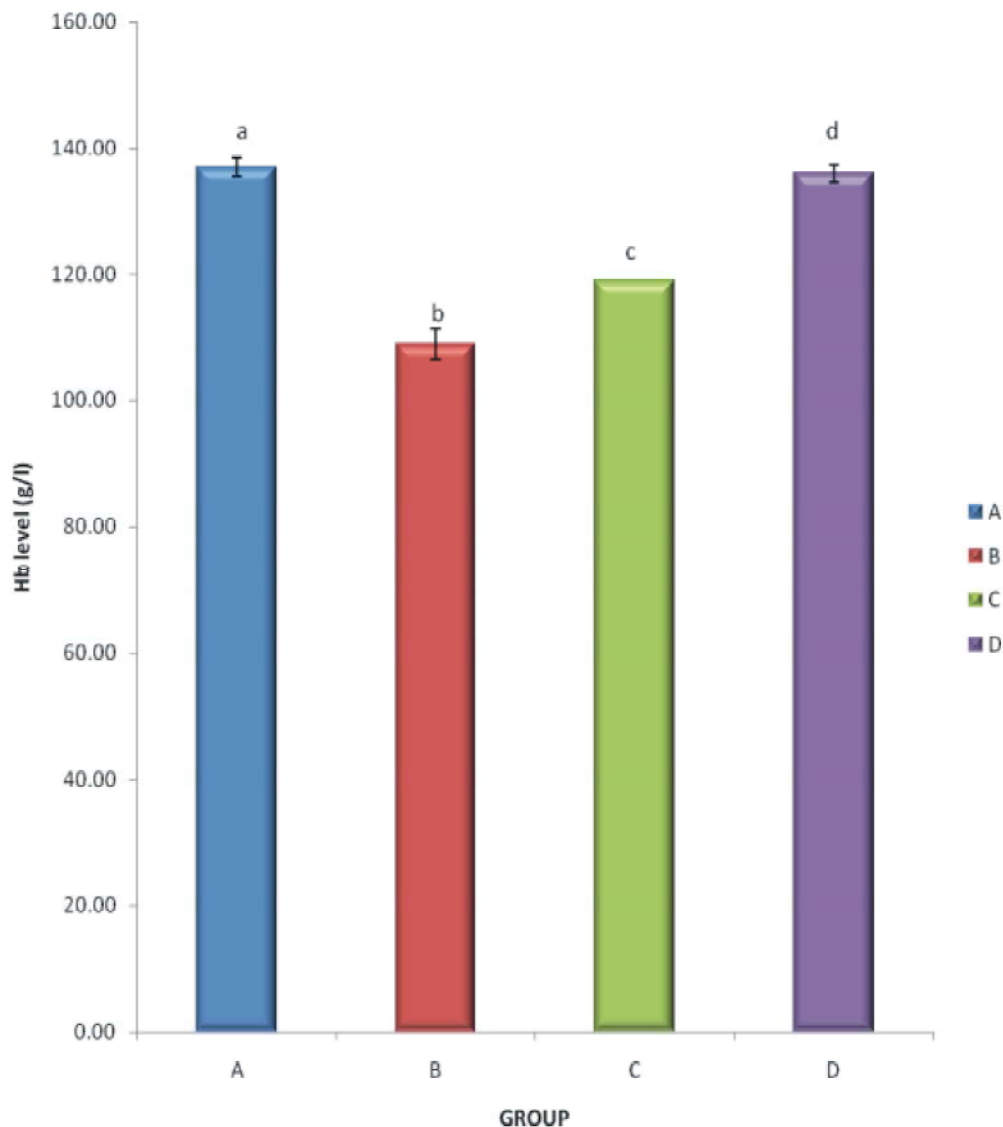


Fig. 1: Effect of ethanol leaf extract of *Ruspolia hypocrateriformis* on haemoglobin level of rat treated with lead acetate. Data are presented as mean \pm SD of six rats. Bars with different letter differed significantly ($P < 0.05$)

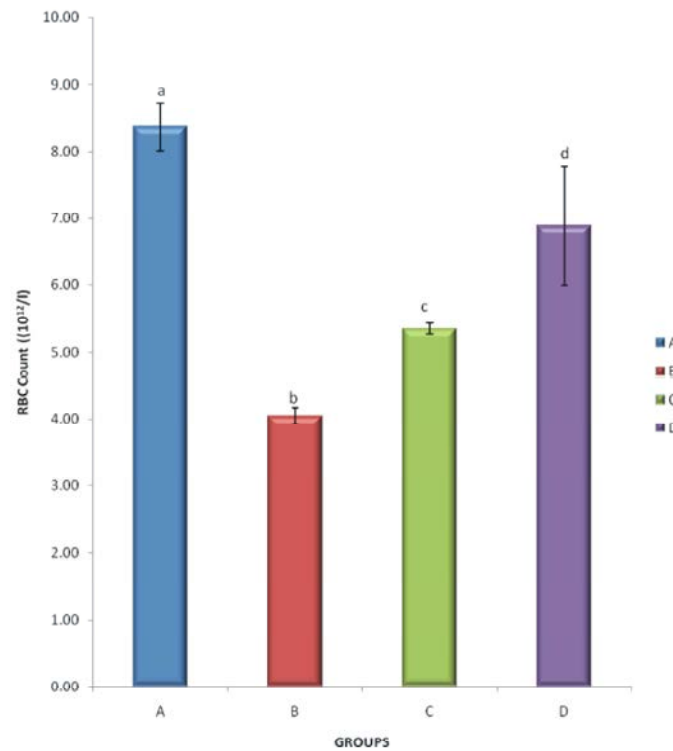


Fig. 2: Effect of ethanol leaf extract of *Ruspolia hypocrateriformis* on RBC count of rat treated with lead acetate. Data are presented as mean \pm SD of six rats. Bars with different letter differed significantly ($P < 0.05$)

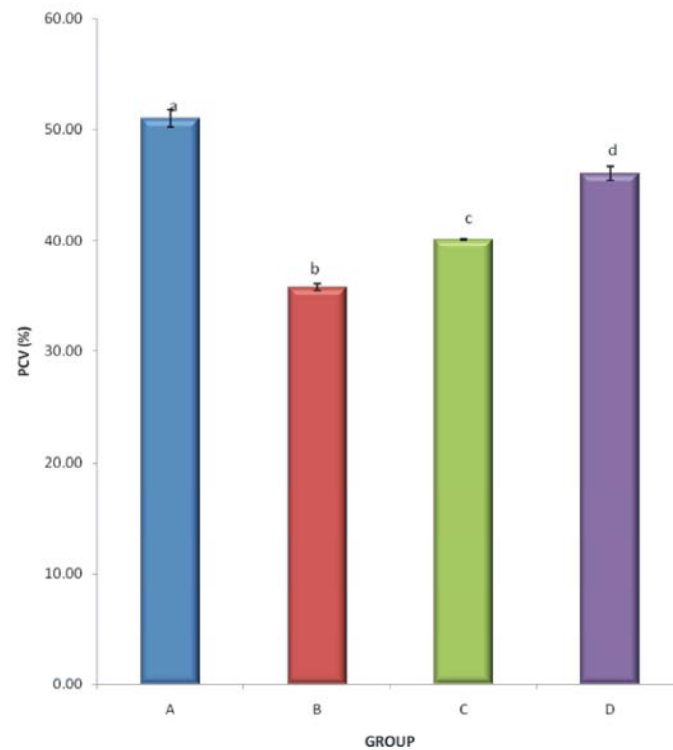


Fig. 3: Effect of ethanol leaf extract of *Ruspolia hypocrateriformis* on PCV of rat treated with lead acetate. Data are presented as mean \pm SD of four rats. Bars with different letter differed significantly ($P < 0.05$)

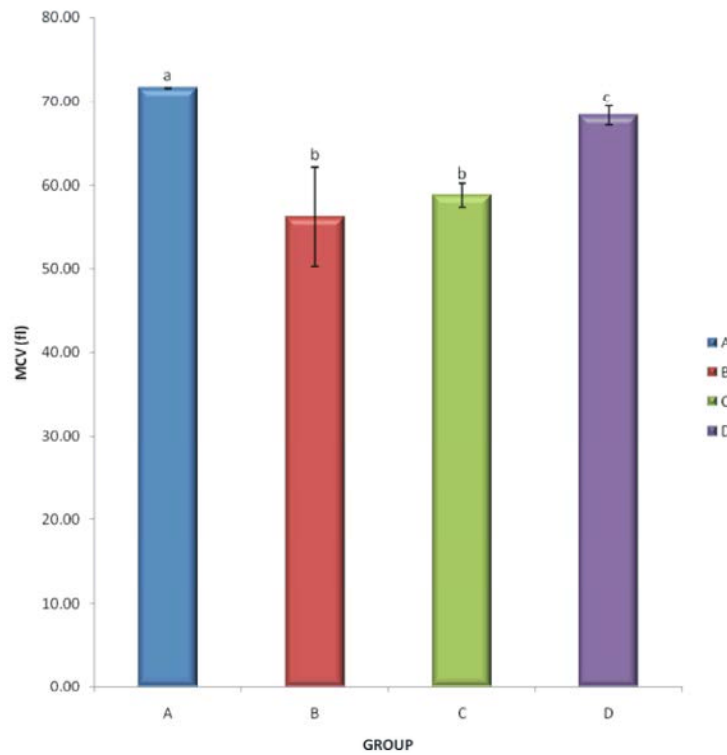


Fig. 4: Effect of ethanol leaf extract of *Ruspolia hypocrateriformis* on MCV level of rat treated with lead acetate. Data are presented as mean \pm SD of six rats. Bars with different letter differed significantly ($P < 0.05$)

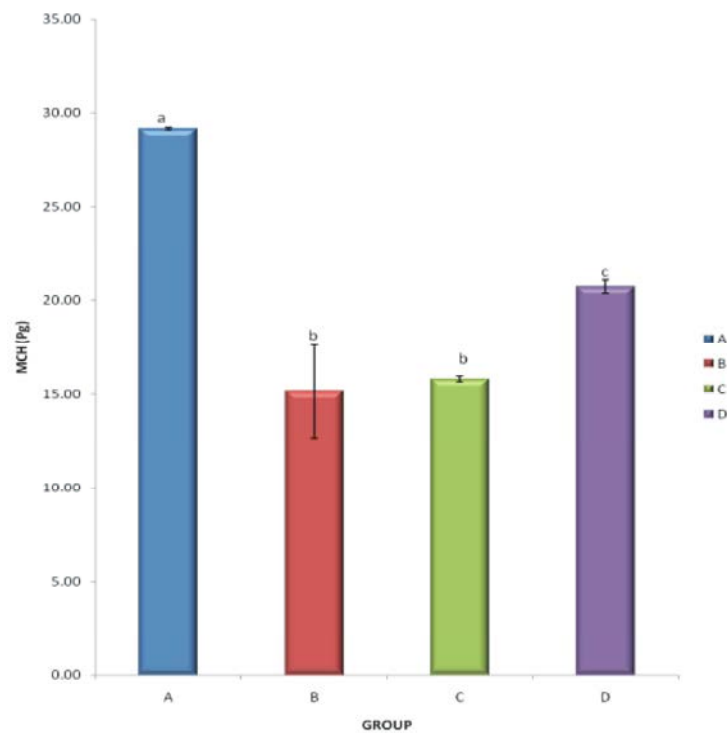


Fig. 5: Effect of ethanol leaf extract of *Ruspolia hypocrateriformis* on MCH level of rat treated with lead acetate. Data are presented as mean \pm SD of six rats. Bars with different letter differed significantly ($P < 0.05$)

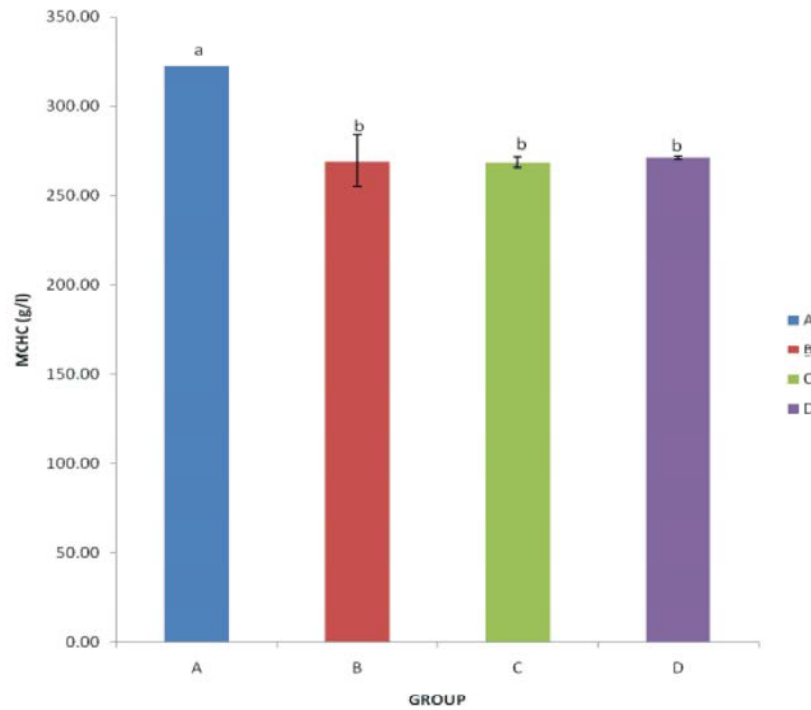


Fig. 6: Effect of ethanol leaf extract of *Ruspolia hypocrateriformis* on MCHC level of rat treated with lead acetate. Data are presented as mean \pm SD of six rats. Bars with different letter differed significantly ($P < 0.05$)

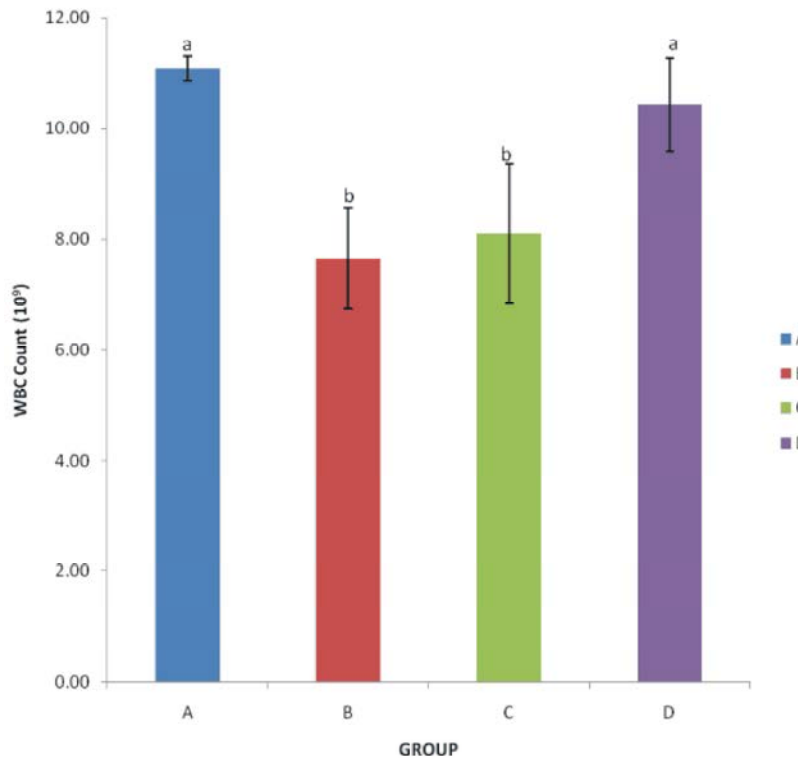


Fig. 7: Effect of ethanol leaf extract of *Ruspolia hypocrateriformis* on WBC count of rat treated with lead acetate. Data are presented as mean \pm SD of six rats. Bars with different letter differed significantly ($P < 0.05$)

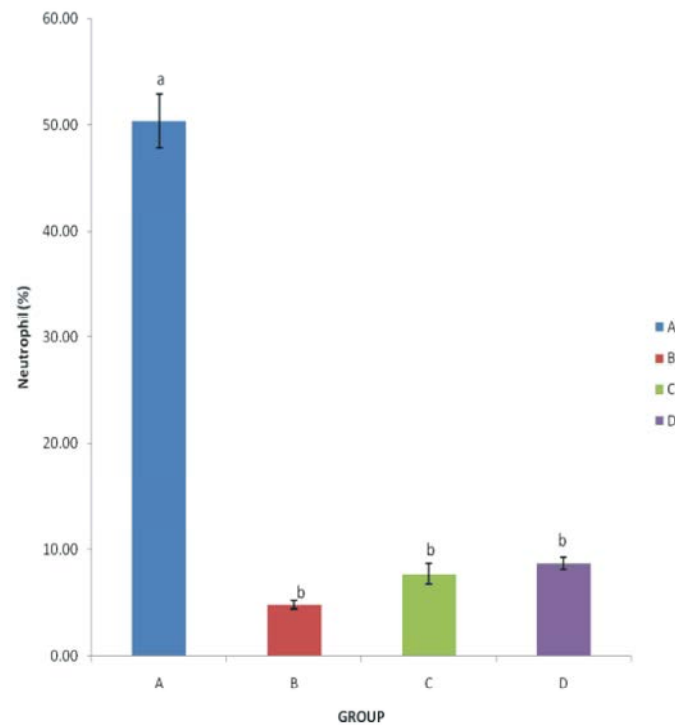


Fig. 8: Effect of ethanol leaf extract of *Ruspolia hypocrateriformis* on neutrophil count of rat treated with lead acetate. Data are presented as mean \pm SD of six rats. Bars with different letter differed significantly ($P < 0.05$)

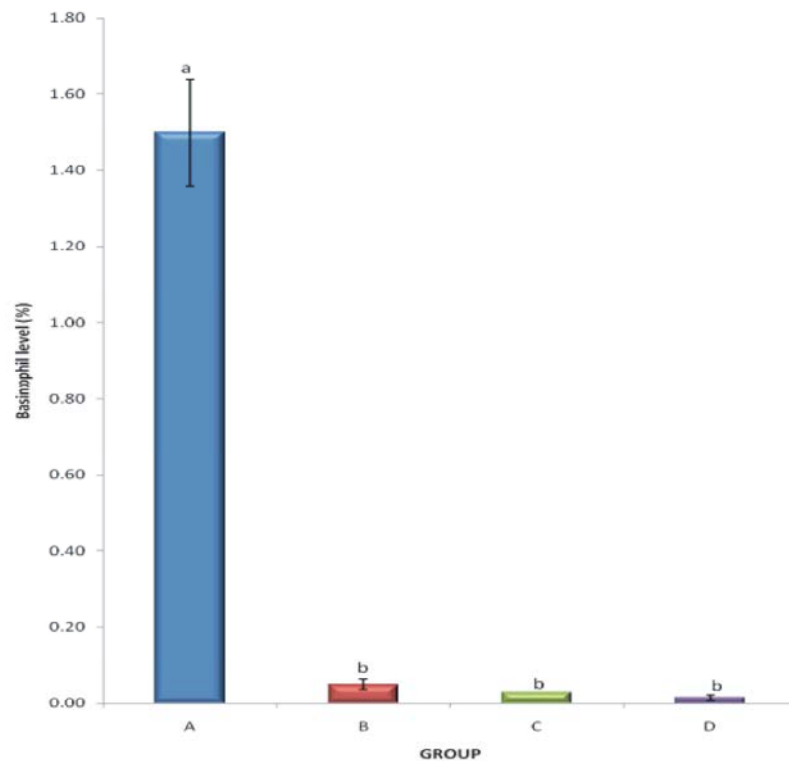


Fig. 9: Effect of ethanol leaf extract of *Ruspolia hypocrateriformis* on Basophil count of rat treated with lead acetate. Data are presented as mean \pm SD of six rats. Bars with different letter differed significantly ($P < 0.05$)

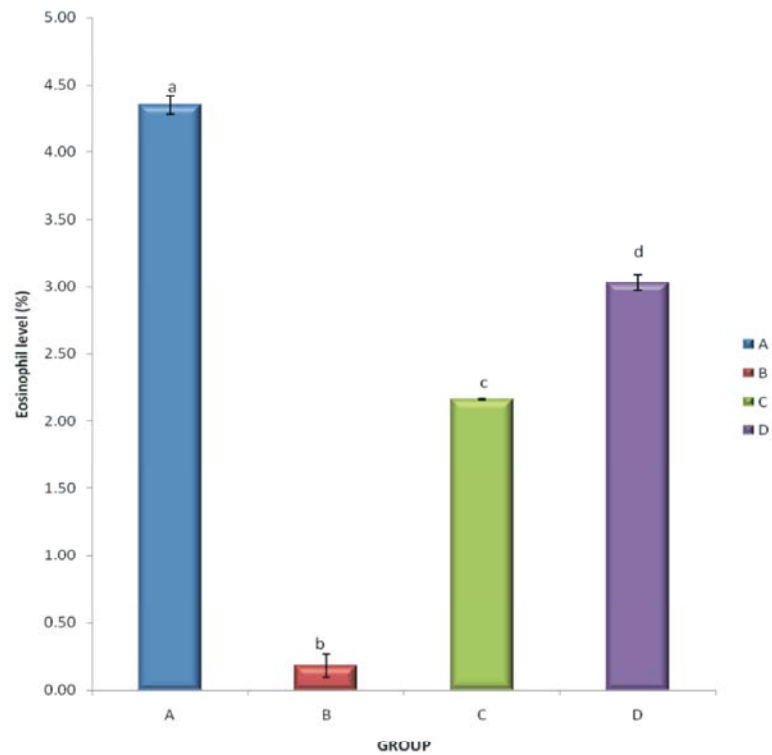


Fig. 10: Effect of ethanol leaf extract of *Ruspolia hypocrateriformis* on eosinophil count of rat treated with lead acetate. Data are presented as mean \pm SD of six rats. Bars with different letter differed significantly ($P < 0.05$)

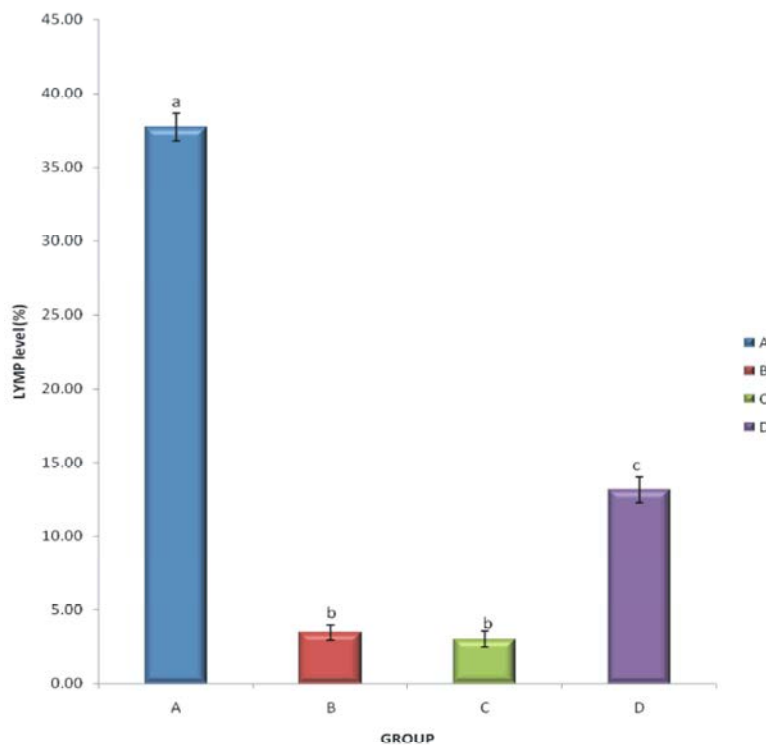


Fig. 11: Effect of ethanol leaf extract of *Ruspolia hypocrateriformis* on Lymphocyte count of rat treated with lead acetate. Data are presented as mean \pm SD of six rats. Bars with different letter differed significantly ($P < 0.05$)

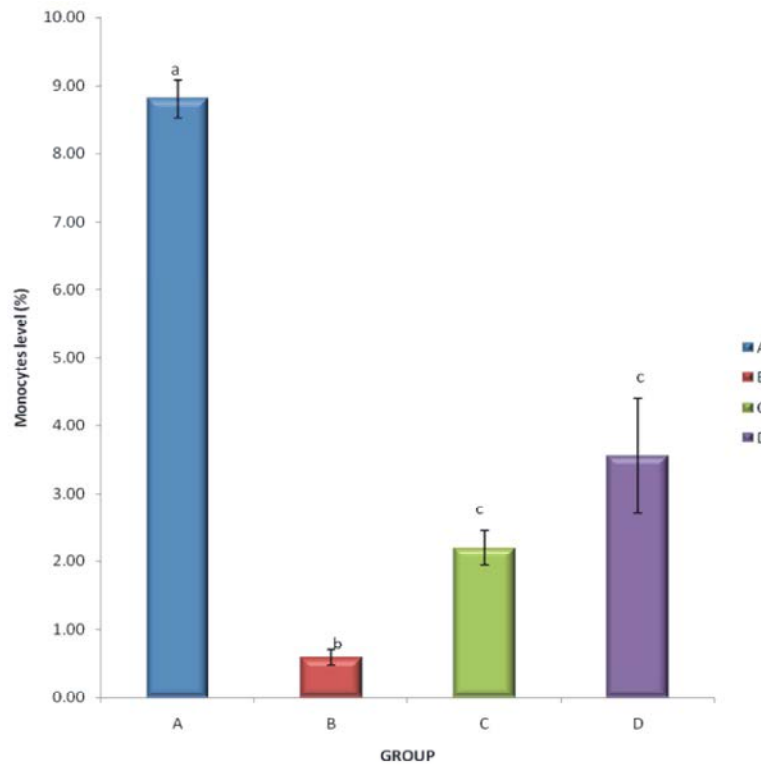


Fig. 12: Effect of ethanol leaf extract of *Ruspolia hypocrateriformis* on monocyte count of rat treated with lead acetate. Data are presented as mean \pm SD of six rats. Bars with different letter differed significantly ($P < 0.05$)

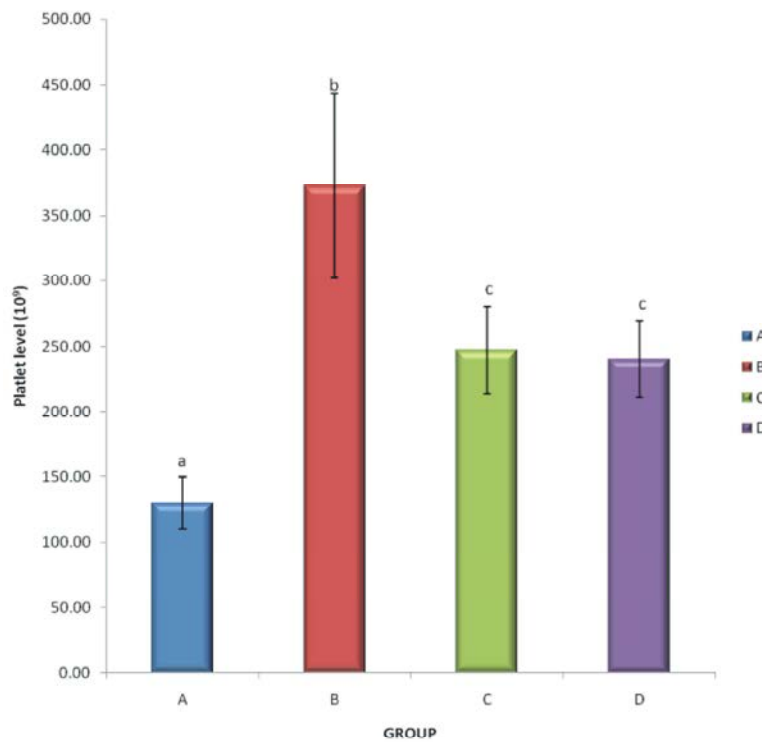


Fig. 13: Effect of ethanol leaf extract of *Ruspolia hypocrateriformis* on platelet count of rat treated with lead acetate. Data are presented as mean \pm SD of six rats. Bars with different letter differed significantly ($P < 0.05$)

DISCUSSION AND CONCLUSION

Haematological profile is known to provide important information about the internal environment of a given organism. Several factors, including nutritional and environmental, have been reported to pose a variety of adverse effects on the haematological profile of most organisms. Nutritional factors include folic acid or Vitamin B12 deficiency [12], while the environmental factors could be exposure to solvents generating environmental pollutants, such as lead poisoning, gasoline, benzene, toluene, hexane, carbon disulphide, insecticides and pesticides such as malathion, methyl parathion, phosphomidon, monocrotophos and fenvalerate, among others.

The results showed significant reduction ($P<0.05$) in the total red blood cell count (TEC) following treatment with lead acetate. It was also observed profound decrease ($p<0.05$) in the levels of haemoglobin (Hb) and packed cell volume (PCV). MCV, MCH and MCHC were also significantly reduced in treated rats. Our results are similar to those reported by [7], [9], [10], [11] and [13]. The reduction of haematological values might be attributed to binding of lead to red blood cells which increase membrane fragility and RBCs destruction [9], generation of reactive oxygen species (ROS) and inhibition of some enzymatic activities such as aminolevulinic acid dehydratase that play vital role in heme biosynthesis [6] and other erythrocyte enzymes e.g GA3PD and G6PD [8] or all in concert. The significant decline in hemoglobin, coupled with a decrease in MCHC signals a predisposition to macrocytosis and hypochromia hematopoiesis in the liver. The MCHC is a good indicator of red blood cell swelling or shrinkage [10]. The decrease in the MCHC values in the lead acetate treated rats is thus probably an indication of swelling of the red blood cells and/or a decrease in haemoglobin synthesis. The decreased Hb content may also be attributed to decreased erythropoiesis and haemoglobin synthesis which, in turn, explains a decreased MCHC.

Leucocytes or white blood cells (WBCs) are the defence cells of the body which provide protection to the organism against environmental as well as anthropogenic stress. Total number of leucocytes per cubic millimeter (TLC) is a diagnostic feature of many diseases. Total leukocyte count (TLC) was significantly decreased in all groups which were administrated lead acetate relative to the control. The significant decrease ($p<0.05$) in WBC

count could be the result of the inactivation of the immune system in the presence of lead acetate [7]. These low values of WBC are related to the toxic action of lead which can induce leukopenia and thrombo-cytopenia in cases of severe liver dysfunction [12]. [11] and [12] however, reported elevated level of white blood cell count which they attributed to lead induced inflammation.

Platelets count revealed significant increase ($p<0.05$) in intoxicated animals compared to the control [13], observed significant reduction on Hb, but increase on the TLC following lead acetate administration at different doses. This may be due to thrombocytopenia after lead intoxication [7] followed by thrombocytosis [13].

Monocytosis (increased number of monocytes) and monocytopenia (decreased number of monocytes) are the pathological condition generally observed as a reflection of stress caused by xenobiotics. Significant reduction in the number of monocytes was observed in rats after treatment with lead acetate which may be the result of elevated phagocytic activity in affected tissues, such as liver and kidneys which were damaged. Disagreements exist concerning monocytes; as in some studies lead-induced monocytopenia [3] and in others significant increases in monocyte count have been reported by [4]. The explanation for such disparity is perhaps due to the extent of lead-induced inflammation. In tandem with other reports acute eosinopenia were observed by [7].

This study also demonstrated that co-administration of ethanol extract of *Ruspolia hypocrateriformis* leaves to the lead treated rats exerts an obvious ameliorating effects. This improvement might be linked to its haemoprotective, immune stimulatory, anti inflammatory effect and antioxidant property. This plant is rich in phenol, flavonoids and vitamin C.

In conclusion, the results from the study have shown that administration of lead acetate produced hemolytic anemia, suppressed the immune system and increased platelet counts of albino rats. Supplementation with the ethanol extract of *Ruspolia hypoteriformis* leaves ameliorated the negative impact of lead poisoning. This metal known for its effects that are acutely risky to human health, are found in the air, soil, water and in foods eaten by humans. Monitoring of this pollutant is necessary for a sustainable environment and people prone to exposure of this metal should be advised to eat this plant.

Competing Interests: There is no competing interests.

REFERENCES

1. Akpanabiatu, M.I., I.B. Umoh, E.U. Eyong and F.V. Udoh, 2005. Influenced of *Nauclea intifolia* leaf Extract on some Hepatic Enzymes of Rats Fed on coconut oil and Non-coconut oil meals. *Pharmacological Biology*, 43(2): 153-157.
2. Akah, K. and S. Okafor, 2004. The Effect of Oral Administration of *Allium sativum* Extracts on Lead Nitrate Induced Toxicity in Male Mice. *Chemical Toxicology*, 48: 928-936.
3. Agbor, G.A., D. Kuate and J.E. Oben, 2007. Medicinal plants can be good sources of antioxidants: case study in Cameroon. *Pakistan Journal of Biological Sciences*, 10(4): 537-544.
4. Tanko, Y., G.S. Uthman, M.A. Mabrouk, A.B. Adelaye, M.Y. Fatihu and K.Y. Musa, 2011. Antidiabetic and some hematological effect of ethyl acetate and n-butanol fraction of *Indigofera pulchra* extract on alloxan-induced diabetic wistar rats. *Journal of Diabetes and Endocrinology*, 2(1): 1-7.
5. Abbiw, O.U. and H.J. Ajali, 2005. Dialuric Acid Autoxidation. Effects of Heavy Metals on the Reaction Rate and on the regeneration of Reactive Oxygen Species. *Journal of Biochemical Pharmacology*, 37: 409- 413.
6. Akinyemi, K.O., O. Oladapo, C.E. Okwara, C.C. Ibe, and K.A. Fasare, 2005. Screening of crude extracts of six medicinal plants used in South-West Nigeria unorthodox medicine anti-methicilin resistant *Staphylococcus aureus* activity. *BMC Complement. Alternative Medicine*, 5(6): 1-7.
7. Akah, P.A., J.A. Alemji, O.A. Salawu, T.C. Okoye, and N.V. Offiah, 2009. Effects of *Vernonia amygdalina* on Biochemical and Hematological parameters in Diabetic rats. *Asian Journal of Medical Sciences*, 1(3): 108-113.
8. Amarnath, V., D.C. Anothony, W.M. Valentine and D.G. Graham, 1991. The molecular mechanism of the carbon disulphide mediated cross-linking of proteins. *Chemical Research of Toxicology*, 4: 148-150.
9. Burkill, H.M., 1985. The useful plants of West Tropical Africa. 2nd Edition. Volume 1, Families A-D. Royal Botanic Gardens, Kew, Richmond, United Kingdom, pp: 960.
10. Jee, L.H., F. Masroor and J.C. Kang, 2005. Responses of cypermethrin-induced stress in haematological parameters of Korean rockfish, *Sebastes schlegeli* (Hilgendorf) *Aquaculture Research*, 36: 898-905.
11. Murray, R.K., D.K. Granner, P.A. Mayes and V.W. Rodwell, 2007. Harper's Illustrated Biochemistry. 26th Edn. McGraw-Hill Companies, Asia, pp: 46-47.
12. Neuwinger, H.D., 2000. African traditional medicine: a dictionary of plant use and applications. Medpharm Scientific, Stuttgart, Germany, pp: 589.
13. Savithri, Y., P.R. Sekhar and P.J. Doss, 2010. Changes in hematological profiles of albino rats under chlorpyrifos toxicity. *International Journal of Pharmacological and Biological Science*, 1: 1-7.