

Organ Preservation Methods in Head and Neck Tumors

¹Cuneyt Ulutin, ¹H. Bakkal, ²S. Ataergin and ³S. Karahatay

¹Department of Radiation Oncology,

²Division of Medical Oncology,

³Department of Otolaryngology,

Gülhane Medical School, Ankara, Türkiye

Abstract: Most frequently seen cell type for the head and neck tumors is squamous cell carcinoma. Generally surgery alone is sufficient treatment method for this disease. Unfortunately, advanced stage disease required adjuvant therapies. Radical surgery also has disadvantage of bad cosmesis and loss of organ function (e.g. Speech). Combination therapies, especially chemoradiotherapy can provide similar survival rates with organ preservation.

Key words: Radiotherapy • head and neck cancer • chemotherapy

INTRODUCTION

Squamous cell carcinomas constitute more than 90% of head and neck cancers (H&NC). H&NC were 2-3% of all cancers and 1-2% of cancer deaths in 2004 in the USA. Most of the patients have metastasis to regional nodes (43%) and distant organs (10%) at diagnosis. Secondary malignancies may develop in 3-7% of patients with H&NC and 50-70% of these secondary malignancies arise from upper aero-digestive system and lungs. Most of the patients are diagnosed in advanced stage. Five-year survival rates of locally advanced H&NC are not perfect as the rates for stage III and IV are 30-50% and 20-40%, respectively. Standard therapeutic approach for resectable tumors is surgery and postoperative radiation therapy (RT). Stage III and IV cancers usually necessitate radical surgery that causes function loss. The problems with radical surgery are loss of speaking and swallowing and cosmesis. Feeding disorder, loss of personal hygiene, loss of social activities and depression cause decrease in the quality of life [1].

For this reason other treatment options such as chemotherapy (CT) should be taken into consideration since H&NC are partly chemo-sensitive. Most of the randomized studies showed no advantage with induction chemotherapy before surgery on survey of 1970's [2, 3]. However successful results were obtained with implementation of cisplatin and its combination with 5-Fluorouracil (5-FU). Thus important steps on organ and function preservation were initiated in 1990's [4, 5]. First, department of Veteran's Affairs (VA) Cooperative Studies Group, later European Organization for Research and Treatment of Cancer (EORTC) started trials about the role of combination treatment modalities on organ preservation for the patients with locally advanced

larynx and hypopharynx cancers [6, 7]. In these randomized studies, the results with chemoradiation therapy (CRT) in patients with larynx and hypopharynx cancer were similar to those with radical surgery and postoperative RT. Due to results of these studies, organ preservation approach was suggested an alternative to urgent radical surgery.

Evaluation of neoadjuvant CT in organ preservation: Neoadjuvant CT becomes an important approach in treatment of H&NC after usage of cisplatin as an active chemotherapeutic agent. Rates of total and complete response become 85 and 35-55% with combination of 5-FU and continue infusion of cisplatin respectively. Combination studies showed that patients who had pathologic complete response had better survival than the ones who did not response [8, 9]. On the other hand, some randomized studies showed no advantage on locoregional control and disease-free survival with neoadjuvant cisplatin + 5-FU followed by surgery [10]. However reduction of tumor volume at least 50% after cisplatin based CT regimens increases the response to RT and this shows that chemosensitive tumors are also radiosensitive. Although CT did not have an advantage on survival, it became an important approach for organ preservation in selected patients.

The opinion of selecting patients for organ preservation according to their response to neoadjuvant CT was pointed out in phase II trials. Thirty patients with advanced stage resectable H&NC were treated with 3 cycles cisplatin + 5-FU in a pilot study. RT was applied to the patients, who had pathologic complete response to CT and 40% patients did not necessitate surgery. Survival of patients treated with CT and RT was similar with the control group treated with surgery alone [11]. In another study RT was applied to patients who had complete

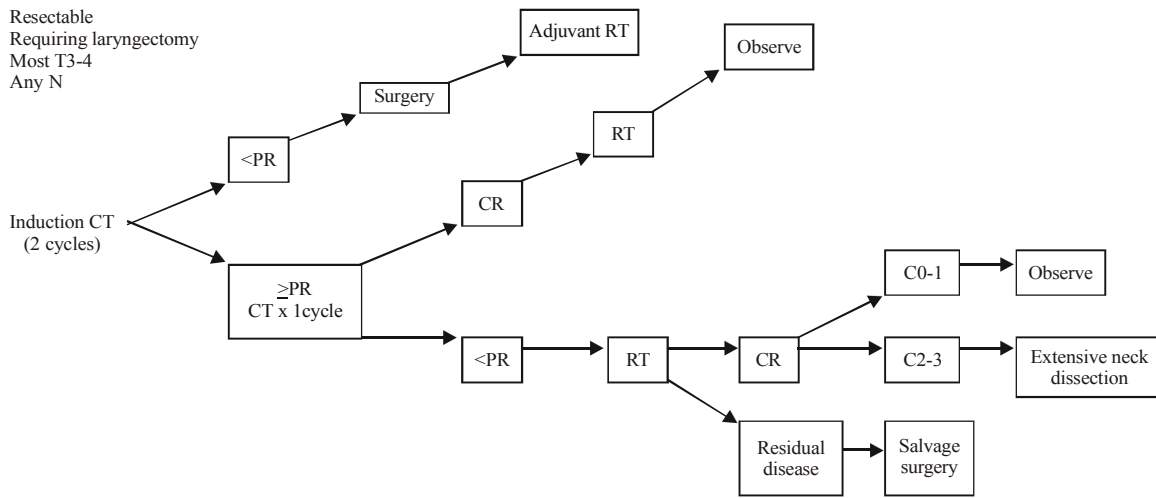


Fig. 1A: Induction chemotherapy approach in glottic larynx carcinoma

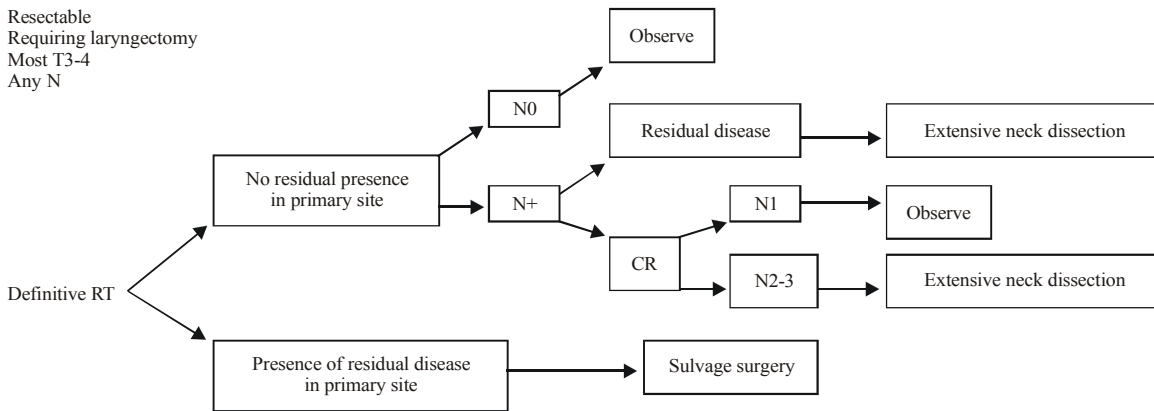


Fig. 1B: Radiotherapy approach in glottic larynx carcinoma

PR: Partial response, CR: Complete response, RT: Radiotherapy, N: Nodal stage

or partial response to CT and total response was 70% (45/64). Complete clinical response rates after RT were 88, 83 and 50% in larynx, hypopharynx and oropharynx cancers, respectively [5]. Karp *et al.* [4] evaluated patients with stage III-IV larynx and hypopharynx cancer who were treated with neoadjuvant CT and reported 77% survival rate. All of the patients were applied RT. Local control in 2-years was achieved in 52% of patients and larynx was preserved in 33 of 35 (94%). The patients who had complete response to CT had better survival than who had not (48 vs 14 months). The results of these studies need further confirmation with randomized studies [12].

Treatment algorithm of larynx and hypopharynx cancer aimed at organ preservation: Association of 17 cancer centers in USA formed National Comprehensive Cancer Network (NCCN) in 1995. The aim of this association was standardization of treatment of cancer patients. Results of

phase-II trials were used in order to constitute treatment guidelines. Standard treatment approach for patients with locally advanced laryngeal (T3, T4) and hypopharyngeal (T2, T3, T4) cancers were total laryngectomy + neck dissection and post-operative RT before the guideline. Unfortunately some patients had problems like hoarseness, swallowing dysfunction and reduction in quality of life (feeding, social activity and personal hygiene) after these procedures. Organ preservation methods include CT followed by RT for the patients with CT response or only RT and, in the case of failure salvage surgery. Three modalities were determined by NCCN can be applied to patients diagnosed as advanced resectable laryngeal and hypopharyngeal cancer. Some factors like performance status, tumor localization and stage are important to give a decision. Laryngeal preservation techniques can be used for advanced (some of T2, T3 and T4) resectable larynx and hypopharynx cancers.

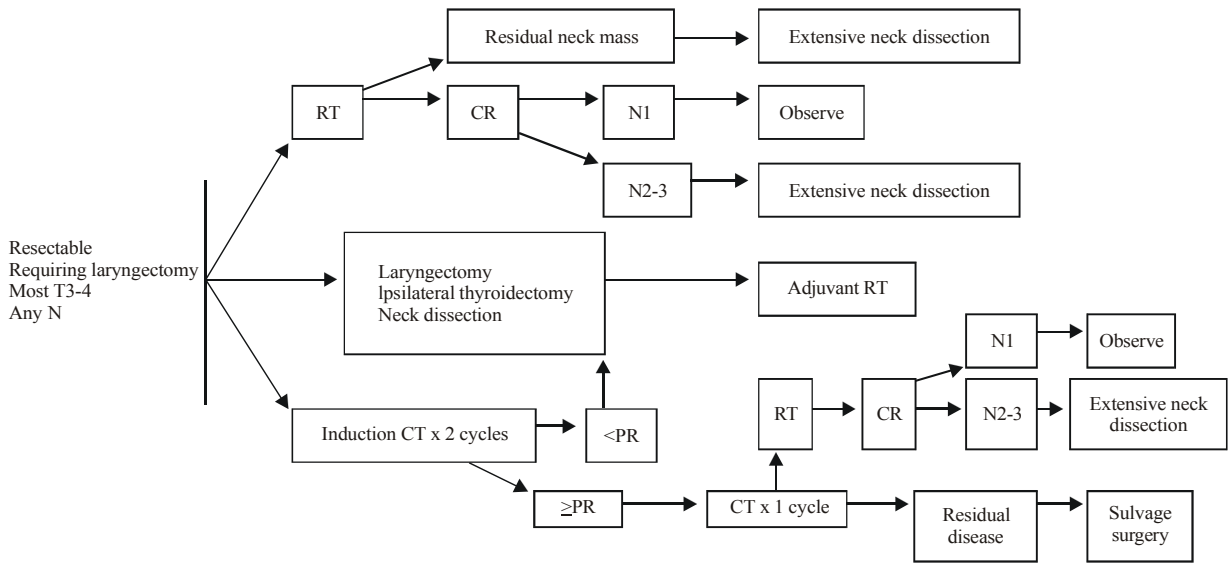


Fig. 2A: Treatment approach in supraglottic larynx carcinoma

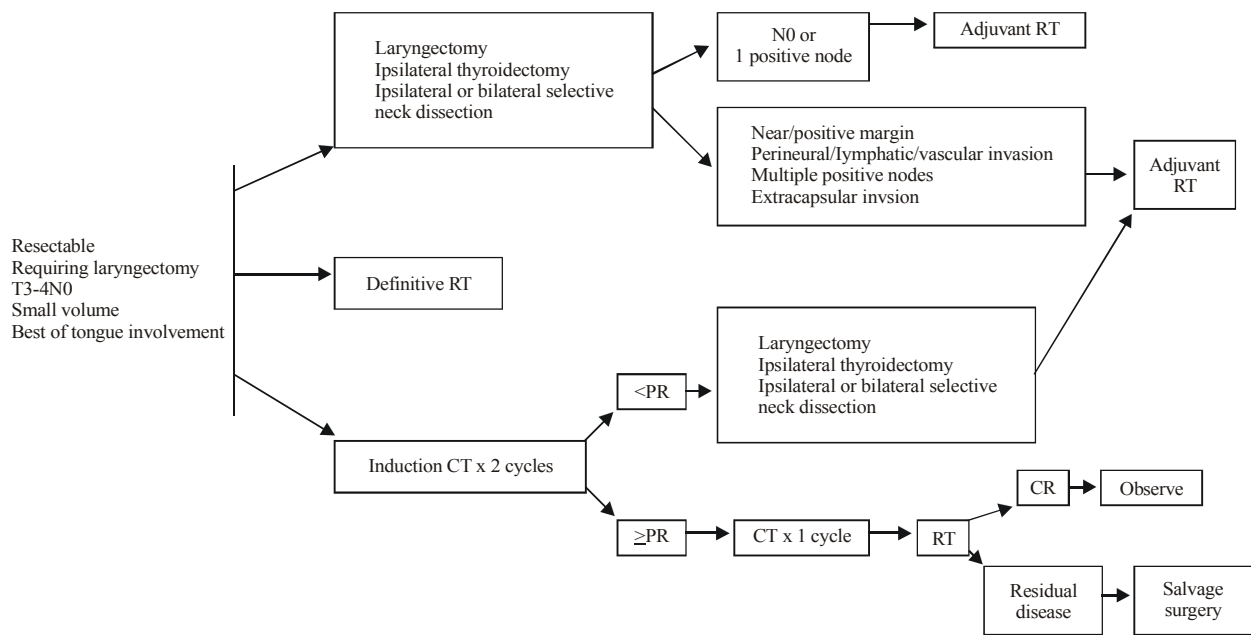


Fig. 2B: Treatment approach in supraglottic larynx carcinoma

Larynx is divided into 3 anatomic regions as supraglottic, glottic and subglottic. Behavior of tumor changes according to the localization. Supraglottic larynx begins from the upper side of true vocal cords and consists of epiglottis, aryepiglottic fold, arytenoids and false cords. True vocal cords constitute glottic larynx. Supraglottic larynx has a wide lymphatic drainage and most of the patients present with advanced stage (T3-T4) node positive disease. Patients usually complain about hoarseness, dysphagia and pain. Despite this, glottic carcinomas can be

diagnosed in an early stage because since it's lesser lymphatic drainage is less and hoarseness is an alarming finding. However hypopharynx cancers usually do not have any symptom till advanced stage. They are diagnosed after the appearance of dysphagia and neck mass and usually spread to oropharynx, nasopharynx and prevertebral region. Nodal metastasis rate is about 60%-80%.

Organ preservation algorithms of NCCN are summarized in Fig. 1A-B, 2A-B and 3A-B [13].

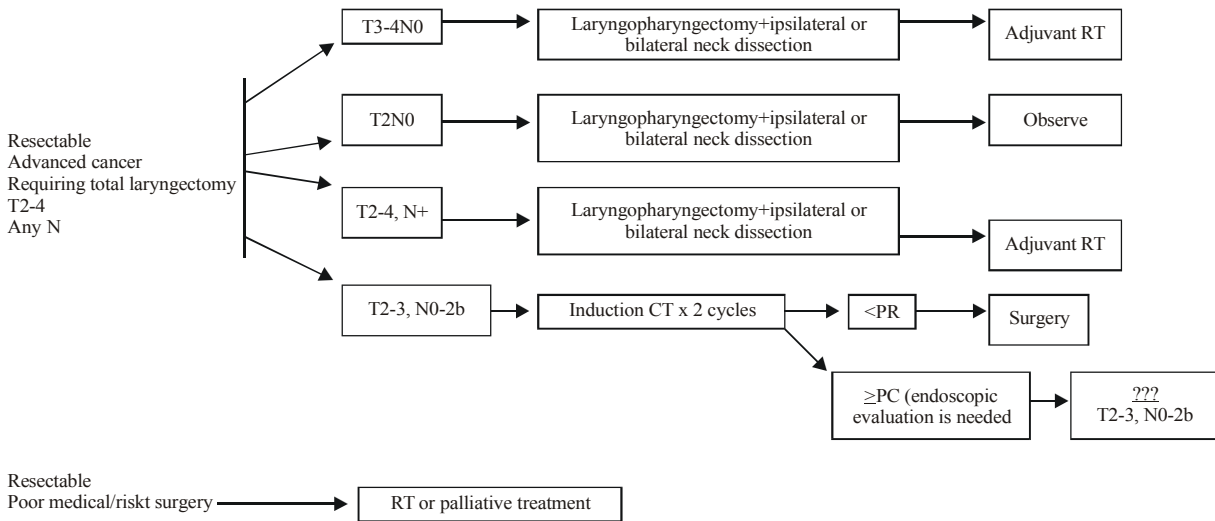


Fig. 3A: Treatment approach in hypopharynx carcinoma

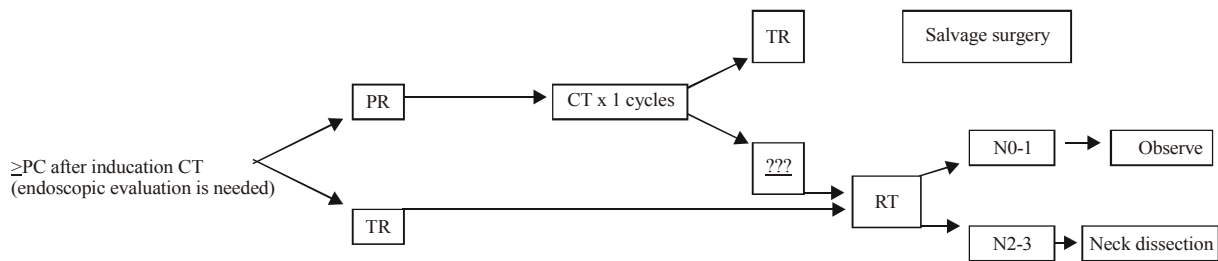


Fig. 3B: Treatment approach in hypopharynx carcinoma

Organ preservation with primer RT: Effect of the tumor volume, calculated by computerized tomography, on RT was investigated in a study from University of Florida. Seventy-five patients with previously untreated T3 glottic larynx carcinoma were treated with curative intent with radiotherapy alone or followed by a neck dissection. The volume of the primary tumor (which was calculated on pretreatment computed tomographic scans) was inversely related to local control with larynx preservation: 87% in tumors $\leq 3.5 \text{ cm}^3$ versus 29% in tumors greater than 3.5 cm^3 . As RT had a relation with tumor volume, an improved local control may be obtained with induction CT in tumors that becomes smaller with RT but CT response is related with tumor load. Increase of T and N stage decreases the response to CT. The 5-year local control and ultimate local control rates were 63 and 86% and 5-year absolute and cause-specific survival rates were 54 and 78%, respectively [14].

According to NCCN's consensus primary RT is controversial in T4 supraglottic cancers with cartilage invasion, soft tissue invasion or invasion of basis of tongue more than 1 cm (Fig. 2B). Some of the centers that use primary RT for

laryngeal preservation approach apply salvage surgery in case of RT insufficiency and/ or recurrence. Organ preservation with RT in subglottic cancer patients is one of the treatment options in Princess Margaret Hospital [15].

Locoregional control in node positive T4 patients is not well (15%) and 5-year disease free survival rate is approximately 25%. This data show that laryngeal preservation can be attained successfully in T3 or T4N0 glottic or supraglottic cancers with primary RT. However, the protocol of NCCN shown in Fig. 1B is not consistent with this approach.

In a study done in Princess Margaret Hospital 410 patients with supraglottic cancer were treated with primary RT. T1-T2 and T3-4 tumors constituted 47 and 53% and N0 and N (+) constituted 65 and 35% of patients, respectively. Recurrence-free survival was 70% in T1-2N0 and 50% in T3-4N0 patients. 5-year laryngeal preservation was managed in 60% for T1-2N0 and 64% for T3-4N0 patients. Presence or absence of nodal disease had a major impact on survival, 5-year laryngeal preservation rate was only 39% in the patients with advanced nodal disease [16].

Treatment with primary RT had been also applied to patients with hypopharynx cancer. In the present study, 98 of 141 patients with hypopharynx cancer was treated with primary RT, 69% of them were node positive and 75% had locally advanced (>T2) disease. 5-year locoregional control was 35% for RT alone arm and 41% for patients undergone salvage surgery. Survival rates were related with nodal stage. 5-year survival rates of T1-2N0 and T3-4N0 were similar (33 vs 36%). 5-year overall survival rate for N0 patients was 53% and 16 of 19 patients had functional larynx for 5 years [17]. However as most of hypopharynx cancers had advanced nodal disease, NCCN guideline does not suggest primary RT (Fig. 3A).

Randomized trials on organ preservation with CT-RT combinations:

In VA Group study 166 patients were randomized to primary surgery (laryngectomy) and RT and 166 to induction CT and RT. RT was applied to patients who had at least a partial response to 2-3 cycles cisplatin + 5-FU. Total laryngectomy was reserved as a salvage therapy to patients who had stable or progressive disease after CT or who had persistent or recurrent disease after RT. This approach was similar with NCCN's treatment algorithm (Fig. 1A, B and 2A, B). Thirty-one percent of patients in the organ preservation arm were alive with functional larynx. Laryngeal preservation was 62% in patients who had taken CT initially. Recurrence patterns were significantly different between 2 groups. While local recurrence was frequent in CT arm (12 vs 2%), distant metastasis was more in surgery arm (11 vs 17%). Furthermore survival rate of patients who necessitated salvage surgery was not different from the patients who had primary surgery. Patients in CT arm who had T4 or N2-3 disease required more salvage laryngectomy or lymph node dissection than the patients who had smaller tumor volumes (56 vs 29%). The results point out that RT can be safely applicable to responders to CT. VA study life quality measurements showed that patients with organ preservation had a better speech and communication in 2 years after treatment. Results revealed that only relatively small percentages of total laryngectomy patients (6%) had usable esophageal speech or remained nonvocal (8%) and that a majority of patients ended up as users of artificial electrolarynx (55%) or tracheoesophageal (31%) speech [6].

Two clinical trials were conducted sequentially at the University of Michigan to determine a treatment strategy for organ preservation in advanced disease larynx carcinomas. Fifty-two patients enrolled in the first study and were treated with 3 cycles of carboplatin and 5-FU. While the patients who achieved at least 50% reduction in the size of the primary tumor received definitive RT, patients with minimal response or progression had immediate salvage surgery. Thirty-seven patients enrolled in the second trial, in which the CT consisted

of carboplatin, 5-FU and leukovorin. Responders were treated with accelerated RT. Toxicity and response were similar in both trials. Response to CT was complete in 48% and partial response in 34%. Initial organ preservation at individual tumor sites were 58 and 59%, for oropharynx and hypopharynx, respectively. Median survival was 28 months and survival at 3 and 5 years for all locations were 40 and 24%, respectively [18].

Clayman *et al.* [19] obtained 67% larynx preservation in stage III-IV larynx and hypopharynx cancer patients with induction CT followed by RT. Survival rates of patients treated with induction CT and primary surgery were similar. Local recurrences were more frequent among the laryngeal preservation group, whereas distant metastasis was more frequent among controls [19].

Groupe d'Etude des Tumeurs de la Tete du cou (GETTEC) randomized 68 patients with T3 larynx carcinoma into induction CT + RT group and total laryngectomy + postoperative RT group. RT was delivered to 13 patients (39%) whose tumor regressed 80%. Overall and disease-free survival rates were better in surgery arm with a median 8.3-years follow-up. Fifteen patients in CT arm (41%) were spared from laryngectomy. As the patient selection was not proportional, the results should be evaluated with caution [10].

Ahmed *et al.* [20] studied efficacy of concomitant CRT and surgical salvage for N3 nodal disease in H&NC patients. Patients received cisplatin and concomitant RT and were reevaluated 2 months later. If there was any residual disease they underwent salvage neck dissections. Among the 31 patients who were assessed for response at the nodal site, 4 (13%) had complete response, 21 (68%) had partial response and 1 (3%) had no response. Nineteen patients subsequently underwent neck dissection and 5 patients had histological evidence of residual disease. With a median follow-up of 15 months, the 3-year overall and disease-specific survival rates were 41 and 43%, respectively. It was mentioned that targeted CRT followed by surgical salvage was an effective approach for regional control of patients with N3 nodal disease [20].

Pennsylvania Cancer Center Clinical Trials Group started a phase II trial for advanced resectable oropharyngeal carcinoma and evaluated efficacy, toxicity and quality of life for organ preservation. Induction CT consisted of carboplatin and paclitaxel for two cycles, followed by reevaluation. Patients with 50% or more response continued to CRT. None-responders underwent radical surgery and postoperative RT. Fifty-three patients enrolled and most of them (89%) responded. Thirteen percent of them had complete response while the others were partial. Fifty patients underwent CRT and complete response was 90%. Thirty-one of 24 patients

(77%) with N2-3 disease who underwent neck dissection after treatment had no residual disease at neck region. The 2 and 3-year survival rates were 75 and 70%, respectively. Most of the deaths (12/17) were because of the oropharyngeal recurrence. T stage was found to be important on survival. Overall survival for T2-3 tumors was 83% while 46% for T4. Distant metastasis in 2 and 3 years were 16 and 19%, respectively and all of them were node positive. Most of the patients tolerated the therapy well. Organ preservation was achieved in 77% of all patients. Functional pharyngolarynx was attained 70% of all patients. Permanent PEG was needed in 4 patients. Feeding and speech-comprehensibility scores were almost the same with the ones before the treatment [21].

Adelstein *et al.* [22] applied hyperfractionated RT and concurrent CT to 41 patients with stage IV squamous cell H&NC. Primary-site resection was reserved for residual or recurrent primary site disease after CRT. Neck dissection was considered for N2 or greater disease, irrespective of clinical response and for residual or recurrent neck disease after nonoperative treatment. Toxicity was significant, with grade 3 to 4 mucositis, dysphagia, skin reaction and neutropenic fever requiring hospitalization in 51%. The 3-year overall survival was 59%. Survival and organ preservation were excellent for this poor-prognosis patient cohort [22].

Wolf *et al.* [23] treated 53 patients with stage III/IV supraglottic or glottic larynx cancer. After one cycle of induction CT the responders were treated with concurrent CRT followed by adjuvant CT. Organ preservation was managed in 35 patients (66%). Only 4 patients required late salvage surgery; one for chondroradionecrosis and three for local recurrence. Fourteen patients had less than 50% response and underwent laryngectomy. Overall survival rate was 88% with a median 2 year follow-up [23].

Tschudi *et al.* [24] evaluated quality of life after different treatment modalities for carcinoma of the oropharynx. Of 99 patients, 31 were treated with surgery alone, 19 with RT alone and 49 with surgery followed by postoperative RT. Patient response to EORTC quality of life core questionnaire QLQ-C30 and EORTC quality of life core head and neck cancer module QLQ-H&N35 questionnaires were applied. Median follow-up for the entire study group was 71 months. Physical, role, emotional, cognitive and social functioning reflected in the functional scale scores of the global EORTC QLQ-C30 were generally good and showed no significant differences for the different treatment modalities. Comparison of the head and neck specific EORTC QLQ-H&N35 scores revealed significantly less troubles with swallowing, social eating and social contact, dry mouth, sticky saliva and mouth opening in non-irradiated patients versus those treated with any either primary or postoperative RT. Patients undergoing surgery (with and

without postoperative RT) had less pain, less problems with social eating and less restricted mouth opening than the nonsurgically treated patients. Also their need for feeding support and feeding tube were less. As 53% of patients had their primary cancer in tonsillary fossa the outcome might be resulted in surgery's favour. [24].

Licitra *et al.* [25] constituted 2 arms as CT and surgery for 195 patients with resectable oral cavity in their study. No significant difference in overall survival was found. Five-year overall survival was, for both arms, 55% [25].

Rosen *et al.* [25] applied concomitant CRT to patients with local advanced H&NC for organ preservation in a multi-institutional randomized phase II trial. A total of 90 patients with locally advanced H&NC were treated on a regimen of paclitaxel, 5-FU, hydroxyurea and RT. Evaluable response was obtained in 78 patients; 87% were complete, 10% were partial and 3% were progression. At median follow-up of 40 months, 3-year progression-free survival was 62% and overall survival was 59%. Eleven of the survivors (22%) had feeding tube [26].

Forastiere *et al.* [27] compared induction CT followed by RT and concurrent CRT used for organ preservation in advanced laryngeal cancer. Patients with locally advanced cancer of the larynx were assigned to one of three treatments: induction cisplatin + 5-FU followed by RT, CRT, or RT alone. A total of 547 patients were followed for a median period of 3.8 years. At 2 years, the proportion of the patients who had an intact larynx after RT with concurrent CT (88%) differed significantly from the proportions in the groups given induction CT followed by RT (75%) or RT alone (70%). The rate of locoregional control was also significantly better with RT and concurrent CT (78 vs. 61% with induction CT followed by RT and 56% with RT alone). The rate of high-grade toxic effects was greater with the CT-based regimens (81% with induction CT followed by RT and 82% with RT with concurrent CT, vs. 61% with RT alone). CRT was superior to other 2 groups for laryngeal preservation and locoregional control. Concurrent CRT became the organ preservation approach in larynx cancer in USA after this study [27].

Vokes *et al.* [28] evaluated organ preservation, locoregional control and quality of life in 69 advanced H&NC patients treated with induction CT followed by concomitant CRT. Response to induction chemotherapy was partial in 52% and complete in 35%, 2 patients were stable and 2 had progressive disease. The rate of complete response, partial response and progression were 82, 5 and 3%, respectively. The overall 3-year progression-free survival was 80% and the 2 and 3-year overall survival rates were 77 and 70%, respectively. Two-years local and distant control rates were 94 and 93%, respectively. Change in quality of life in preinduction and postinduction period

was as following; pain 33 to 4%, dysphagia 33 to 7%, hoarseness 24 to 2%, respectively. Rate of xerostomia increased at 12 months compared with the beginning. Fourteen of 57 patients alive at 12 months and 5 patients were completely feeding-tube dependent [28].

Hanna *et al.* [29] evaluated organ preservation and toxicity of intensive CRT in 127 patients with advanced epidermoid H&NC. Median follow-up was 36 months. Primary CRT achieved complete response at the primary tumor site in 109 patients (86%). Patients with partial response, stable or progressive disease, or recurrence at the primary site underwent salvage surgery. At mean follow-up of 3 years, local disease control was achieved in 113 patients (89%) and organ preservation was possible in 102 patients (80%). Two thirds of all patients (n: 83) had clinical N (+) disease. Complete clinical response to CRT in the neck was achieved in 69% of these patients. However, complete response to CRT was 93, 62 and 47% for N1, N2 and N3 disease, respectively. Patients achieving less than complete clinical response underwent salvage neck dissection. Overall, at an average follow-up of 36 months, regional disease control was achieved in 76 (92%) of the 83 patients with neck metastasis. Despite this high locoregional control rate, distant metastasis occurred in 14% of patients. At 3-years mean follow-up, disease-specific and overall survival were 72 and 57%, respectively [29].

Brokstein *et al.* [30] assessed 337 patients with stage IV H&NC treated with concomitant CRT in a multi-institutional phase II trial. Two different treatment strategies: Intensive induction CT followed by split-course CRT (type 1, n: 127) and intensified, split-course, hyperfractionated multiagent CRT alone (type 2, n: 210) were compared in the study. Combined 5-year overall survival was 47% and progression-free survival was 60%. 5-year locoregional failure was 31 and 17% for study types 1 and 2, respectively [30].

Psiyri *et al.* [31] conducted a phase II study of induction CT followed by concurrent CRT for organ preservation in 42 stage III-IV resectable squamous H&NC and nasopharyngeal cancer patients. Response to induction CT included partial response rate of 52% and complete response rate of 24%. After CRT the complete response rate was 67%. At a median follow-up of 71.5 months, 43% of the patients were still alive and disease-free. The 5-year progression-free survival rate was 60% and the 2- and 5-year overall survival rates were 67 and 52%, respectively. The treatment approach was well tolerated and was found to be feasible for organ preservation [31].

Rivera *et al.* [32] evaluated long-term results of a phase II trial of induction CT followed by concomitant CRT for resectable locally advanced larynx and hypopharynx in 37 patients. Median follow-up was 62 months. Complete and

partial response to induction CT was 54 and 32%, respectively. Ten patients needed surgery while remainders underwent RT or CRT. Twenty-seven patients (69%) had CRT after induction CT. Actuarial 5-year overall survival was 57%, 5-year survival with primary site preservation was 37% [32].

Kotz *et al.* [33] evaluated swallowing dysfunction after CRT for advanced H&NC. Twelve patients with stage III/IV squamous cell H&NC were performed videofluorographic-swallowing studies before and after initiation of CRT. Changes in swallowing physiology after treatment included decreased contact of base of tongue to posterior pharyngeal wall and reduced pharyngeal contraction, resulted impaired bolus transport through the pharynx. In addition, decreased laryngeal elevation, decreased laryngeal vestibule closure and laryngeal penetration were present. It was mentioned that organ preservation treatment impaired movement of structures essential for normal swallowing and prophylactic swallowing exercises may be beneficial for these patients [33].

In a study from Medical University of South Carolina, Gillespie *et al.* [34] tried to determine swallowing outcome after treatment in 40 patients with stage III-IV squamous cell carcinoma of H&NC. Eighteen patients underwent CRT while 22 underwent surgery and postoperative RT. Outcome measures included a dysphagia risk factor survey, the MD Anderson Dysphagia Inventory (MDADI) and the Short-Form 36 (SF-36) (questionary for quality of life). Patients who received CRT for oropharyngeal primaries demonstrated significantly better scores on the emotional and functional subscales of the MDADI than patients who underwent surgery followed by RT. Risk factors for posttreatment dysphagia included prolonged (>2 weeks) nothing by mouth (NPO) status and low SF-36 Mental Health Subscale score [34].

Altundag *et al.* [35] evaluated 45 patients with locoregionally advanced resectable larynx and hypopharynx cancer in their study for organ preservation. The patients were treated with two cycles of induction CT. Patients who had a complete response to CT were treated with definitive RT and the ones who had a partial response to CT were treated with CRT. Patients who had no response or progressive disease underwent surgery with postoperative RT. Patients with N2 or N3 positive lymph nodes underwent neck dissection after the treatment. The overall response rate to induction CT was 71.1%, with a 17.8% complete and 53.3% partial response rate. With a median follow-up of 13.7 months, 23 (51.1%) of all patients and 63.3% of surviving patients have had a preservation of the larynx or hypopharynx [35].

Southwest Oncology Group (SWOG) applied induction CT followed by CRT for responders with base of tongue or hypopharyngeal cancer in a phase II study and evaluated the complete histologic response rate, organ preservation and

necessity of salvage surgery. Induction CT included 2 cycles of cisplatin and 5-FU for 5 days. Patients who had a greater than 50% response at the primary site were treated with 72 Gy RT and concurrent cisplatin for 3 cycles. Patients with less than partial response at the primary had salvage surgery. Forty-five patients (76%) had a greater than 50% response at the primary after induction CT; 43 went on to receive definitive RT. Thirty-two patients (54%) achieved a histologic complete response at the primary site and 9 patients had a complete clinical response, but biopsy was not performed. Seventy-five percent of patients did not require surgery at the primary tumor site. The 3-year overall and 3-year progression-free survival with organ preservation was 64 and 52%, respectively. It was determined that patients with base of tongue or hypopharyngeal cancer treated with this regimen had a better rate of organ preservation without compromise of survival [36].

Rischin *et al.* [37] randomized 121 previously untreated patients with stage III/IV H&NC into 2 arms in a phase II study; 1) Tirapazamine, Capsulation(TPZ/CIS) and RT versus 2) 5-FU, Cisplatin and RT (chemoboost). Treatment was completed without neck dissection in 71 and 66% patients in TPZ/CIS and chemoboost groups, respectively. Complete response rates were 81% in TPZ/CIS and 72% in chemoboost group. Three-year locoregional failure-free rate was 84% in the TPZ/CIS arm and 66% in the chemoboost arm. Three-year failure-free survival rate was 55% with TPZ/CIS and 44% with chemoboost [37].

CONCLUSIONS

Prognosis in advanced H&NC is not satisfactory with surgery alone. Better results can be achieved with organ preservation strategies using CRT. Because of toxicity, follow-up and supportive care should be managed carefully. Furthermore patients' choice for functioning larynx should be taken into consideration for the selection of treatment type.

REFERENCES

1. Ridge, J.A., B. Glisson and E. Horwitz *et al.*, 2002. Head and neck tumors. Cancer Management: Multidisciplinary approach, 6th Edn., Melville-USA., pp: 36-39.
2. Blaha, K., O. Sibl and P. Jirko *et al.*, 1977. Combination therapy using cytostatics and radiotherapy in carcinoma of the larynx. *Cesk Otolaryngol.*, 26: 6-10.
3. Nahum, A.M., 1975. Overview of chemotherapy of cancer of the larynx. *Can. J. Otolaryngol.*, 4: 4-11.
4. Karp, D.D., C.W. Vaughan and R. Carter *et al.*, 1991. Larynx preservation using induction chemotherapy plus radiation therapy as an alternative to laryngectomy in advanced head and neck cancer. A long-term follow-up report. *Am. J. Clin. Oncol.*, 14: 273-279.
5. Shirinian, M.H., R.S. Weber and S.M. Lippman *et al.*, 1994. Laryngeal preservation by induction chemotherapy plus radiotherapy in locally advanced head and neck cancer: The M. D. Anderson Cancer Center experience. *Head Neck*, 16: 39-44.
6. Hillman, R.E., M.J. Walsh and G.T. Wolf *et al.*, 1998. Functional outcomes following treatment for advanced laryngeal cancer. Part I-Voice preservation in advanced laryngeal cancer. Part II-Laryngectomy rehabilitation: The state of the art in the VA System. Research Speech-Language Pathologists. Department of Veterans Affairs Laryngeal Cancer Study Group. *Ann. Otol. Rhinol. Laryngol.*, 172: 1-27.
7. Lefebvre, J.L., D. Chevalier and B. Lubinski *et al.*, 1996. Larynx preservation in pyriform sinus cancer: Preliminary results of a European Organization for Research and Treatment of Cancer phase III trial. EORTC Head and Neck Cancer Cooperative Group. *J. Natl. Cancer Inst.*, 88: 890-899.
8. Spaulding, M.B., S.G. Fischer and G.T. Wolf, 1994. Tumor response, toxicity and survival after neoadjuvant organ-preserving chemotherapy for advanced laryngeal carcinoma. The Department of Veterans Affairs Cooperative Laryngeal Cancer Study Group. *J. Clin. Oncol.*, 12: 1592-1599.
9. Zidan, J., A. Kuten and E. Rosenblatt *et al.*, 1997. Intensive chemotherapy using cisplatin and fluorouracil followed by radiotherapy in advanced head and neck cancer. *Oral Oncol.*, 33: 129-135.
10. Richard, J.M., H. Sancho-Garnier and J.J. Pessey *et al.*, 1998. Randomized trial of induction chemotherapy in larynx carcinoma. *Oral Oncol.*, 34: 224-228.
11. Jacobs, C., D.R. Goffinet and L. Goffinet *et al.*, 1987. Chemotherapy as a substitute for surgery in the treatment advanced resectable head and neck cancer. A report from the Northern California Oncology Group, 60: 1178-1183.
12. Engin, K. and L. Erisen, 2003. Bas boyun kanserleri. Nobel tip kitabevi, Bursa, pp: 402-404.
13. Gillison, M.L. and A.A. Forastiere, 1999. Larynx preservation in head and neck cancers. A discussion of the National Comprehensive Cancer Network Practice Guidelines. *Hematol. Oncol. Clin. North Am.*, 13: 699-718.
14. Mendenhall, W.M., J.T. Parsons and A.A. Mancuso *et al.*, 1997. Definitive radiotherapy for T3 squamous cell carcinoma of the glottic larynx. *J. Clin. Oncol.*, 15: 2394-2402.
15. Paisley, S., P.R. Warde and B. O'Sullivan *et al.*, 2002. Results of radiotherapy for primary subglottic squamous cell carcinoma. *Intl. J. Radiat. Oncol. Biol. Phys.*, 52: 1245-1250.

16. Harwood, A.R., F.A. Beale and B.J. Cummings *et al.*, 1983. Supraglottic laryngeal carcinoma: An analysis of dose-time-volume factors in 410 patients. *Intl. J. Radiat. Oncol. Biol. Phys.*, 9: 311-319.
17. Keane, T.J., N.V. Hawkins and F.A. Beale *et al.*, 1983. Carcinoma of the hypopharynx results of primary radical radiation therapy. *Intl. J. Radiat. Oncol. Biol. Phys.*, 9: 659-664.
18. Urba, S., G. Wolf and C. Bradford *et al.*, 2000. Neoadjuvant therapy for organ preservation in head and neck cancer. *Laryngoscope*, 110: 2074-2080.
19. Clayman, G.L., R.S. Weber and O. Guillaumondegui *et al.*, 1995. Laryngeal preservation for advanced laryngeal and hypopharyngeal cancers. *Arch Otolaryngol Head Neck Surgery*, 121: 219-223.
20. Ahmed, K.A., K. Robbins and F. Wong *et al.*, 2000. Efficacy of concomitant chemoradiation and surgical salvage for N3 nodal disease associated with upper aerodigestive tract carcinoma. *Laryngoscope*, 110: 1789-1793.
21. Machtay, M., D. Rosenthal and D. Hershock *et al.*, 2002. Organ preservation therapy using induction plus concurrent chemoradiation for advanced resectable oropharyngeal carcinoma: a University of Pennsylvania Phase II Trial. *J. Clin. Oncol.*, 20: 3964-3971.
22. Adelstein, D., J.P. Saxton and P. Lavertu *et al.*, 2002. Maximizing local control and organ preservation in stage IV squamous cell head and neck cancer with hyperfractionated radiation and concurrent chemotherapy. *J. Clin. Oncol.*, 20: 1405-1410.
23. Wolf, G., C. Bradford and S. Urba *et al.*, 2000. Immune reactivity does not predict chemotherapy response, organ preservation, or survival in advanced laryngeal cancer. *Laryngoscope*, 112: 1351-1356.
24. Tschudi, S. Stoeckli and S. Schmid, 2003. Quality of life after different treatment modalities for carcinoma of the oropharynx. *Laryngoscope*, 113: 1949-1954.
25. Licitra, L., C. Grandi and M. Guzzo *et al.*, 2003. Primary chemotherapy in resectable oral cavity squamous cell cancer: A randomized controlled trial. *J. Clin. Oncol.*, 21: 327-333.
26. Rosen, F.R., D. Haraf and M. Kies *et al.*, 2003. Multicenter randomized phase II study of paclitaxel (1 h infusion), fluorouracil, hydroxyurea and concomitant twice daily radiation with or without erythropoietin for advanced head and neck cancer. *Clin. Cancer Res.*, 9: 1689-1697.
27. Forastiere, A.A., H. Goepfert and M. Maor *et al.*, 2003. Concurrent chemotherapy and radiotherapy for organ preservation in advanced laryngeal cancer. *New Eng. J. Med.*, 27: 2087-2089.
28. Vokes, E., K. Stenson and F. Rosen *et al.*, 2003. Weekly carboplatin and paclitaxel followed by concomitant paclitaxel, fluorouracil and hydroxyurea chemoradiotherapy: Curative and organ-preserving therapy for advanced head and neck cancer. *J. Clin. Oncol.*, 21: 320-326.
29. Hanna, E., M. Alexiou and J. Morgan *et al.*, 2004. Intensive chemoradiotherapy as a primary treatment for organ preservation in patients with advanced cancer of the head and neck: efficacy, toxic effects and limitations. *Arch Otolaryngol Head Neck Surgery*, 130: 861-867.
30. Brockstein, B., D.J. Haraf and W.A. Rademaker *et al.*, 2004. Patterns of failure, prognostic factors and survival in locoregionally advanced head and neck cancer treated with concomitant chemoradiotherapy: A 9-year, 337-patient, multi-institutional experience. *Ann. Oncol.*, 15: 1179-1186.
31. Psyrri, A., M. Kwong and S. DiStasio *et al.*, 2004. Cisplatin, fluorouracil and leucovorin induction chemotherapy followed by concurrent cisplatin chemoradiotherapy for organ preservation and cure in patients with advanced head and neck cancer: Long-term follow-up. *J. Clin. Oncol.*, 22: 3061-3069.
32. Rivera, F., M. Vega and M.F. Lopez-Brea *et al.*, 2004. Long-term results of a phase II trial of induction chemotherapy with uracil-ftegafur (UFT), vinorelbine and cisplatin (UFTVP) followed by radiotherapy concomitant with UFT and carboplatin (RT/UFTJ) in a primary site preservation setting for resectable locally advanced squamous cell carcinoma of larynx and hypopharynx. *Laryngoscope*, 114: 1163-1169.
33. Kotz, T., R. Costello and Y. Li *et al.*, 2004. Swallowing dysfunction after chemoradiation for advanced squamous cell carcinoma of the head and neck. *Head Neck*, 26: 365-372.
34. Gillespie, B.M., M.B. Brodsky and A.T. Day *et al.*, 2004. Swallowing-related quality of life after head and neck cancer treatment. *Laryngoscope*, 114: 1362-1367.
35. Altundag, O., I. Gullu and K. Altundag *et al.*, 2005. Induction chemotherapy with cisplatin and 5-fluorouracil followed by chemoradiotherapy or radiotherapy alone in the treatment of locoregionally advanced resectable cancers of the larynx and hypopharynx: results of single-center study of 45 patients. *Head Neck*, 27: 15-21.
36. Urba, S.G., J. Moon and S. Giri *et al.*, 2005. Organ preservation for advanced resectable cancer of the base of tongue and hypopharynx: A South-west Oncology Group Trial. *J. Clin. Oncol.*, 23: 88-95.
37. Rischin, D., L. Peters and R. Fisher *et al.*, 2005. Tirapazamine, Cisplatin and Radiation versus Fluorouracil, Cisplatin and Radiation in patients with locally advanced head and neck cancer: a randomized phase II trial of the Trans-Tasman Radiation Oncology Group (TROG 98.02). *J. Clin. Oncol.*, 23: 79-87.