

## Impact of Eyestalk Ablation on the Androgenic Gland Activity in the Freshwater Prawn *Macrobrachium rosenbergii* (De Man)

<sup>1</sup>P. Revathi, <sup>2</sup>P. Iyapparaj, <sup>3</sup>L. Arockia Vasanthi, <sup>3</sup>S. Jeyanthi,  
<sup>4</sup>S. Sankaralingam, <sup>5</sup>R. Ramasubburayan, <sup>6</sup>S. Prakash and <sup>1</sup>M. Krishnan

<sup>1</sup>Department of Environmental Biotechnology, Bharathidasan University, Trichy-620 024, Tamilnadu, India

<sup>2</sup>CAS in Marine Biology, Faculty of Marine Sciences,  
Annamalai University, Parangipettai-608 502, Tamil nadu, India

<sup>3</sup>Department of Zoology, University of Madras,  
Guindy Campus, Chennai-600 025, Tamilnadu, India

<sup>4</sup>Department of Botany, Yadava College, Madurai-14, Tamilnadu, India

<sup>5</sup>CMST, Manonmaniam Sundaranar University, Rajakkamangalam-629502, Tamilnadu, India

<sup>6</sup>Research Institute, SRM University, Kattankulathur-603 203, Tamilnadu, India

**Abstract:** Effect of eyestalk ablation on the androgenic gland (AG) activity in freshwater male prawn *Macrobrachium rosenbergii* was studied for a period of 30 days. For this, eyestalk of the experimental prawns were ablated and resulted in increased body weight, gonado somatic index (GSI) as well as androgenic gland weight. In contrast, hepatosomatic index (HSI) is decreased in ablated prawns compared to intact. On the other hand, histological results clearly indicated that the testis of ablated prawn showed increase in spermatozoa concentration and size of seminiferous tubule. Besides, the androgenic gland of ablated prawn showed an abundance of epithelial cells. Surface topography analysis using Scanning Electron Microscopy (SEM) inferred the occurrence of epithelial cells were increased prominently and embedded in connective tissues of androgenic gland. Whereas, the biochemical constituents such as total protein and lipid content is increased in testis and androgenic gland of ablated prawns than intact. Deficiency in neuropeptide hormone complex due to eyestalk ablation is the causative of impaired reproductive process and androgenic gland activity in *M. rosenbergii*.

**Key words:** Eyestalk Ablation • Reproductive Activity • Biochemical Changes • Surface Topography

### INTRODUCTION

The crustacean eyestalk is known to have a neuro haemal organ to function due to the presence of the X-organ and sinus gland system. Excision of eyestalk is a classical endocrinological experiment to determine the functions of the eyestalk neuro peptide hormones. Eyestalk neuro peptide hormones are directly inhibited the gonad development in crustaceans [1]. The androgen gland hormone controls the differentiation of the male genital apparatus and the secondary sex characteristics [2, 3].

In some decapod species, removal of the X-organ and sinus gland complex by eyestalk ablation leads to hypertrophy of reproduction and molting.

The assessor sex gland like androgenic gland, which then displays ultrastructural features related to hyperactivity [4-6]. Gonad inhibiting hormone (GIH) and the gonad stimulating hormone (GSH) promote the testicular development through AG [2, 3]. It is possible that androgenic gland hormones not only control morphotypic differentiation but it also affect somatic growth by Kuris *et al.* [7]. In different crustaceans, the AG exerts well-defined male-specific morphological, physiological and behavioral effects. Many crustaceans exhibit a sexual dimorphic growth pattern, which might be a manifestation of the effects exerted by the AG, as found in *M. rosenbergii* [8]. The androgenic gland hormone appears to effect sex reversal in genetic females [9, 10].

In certain decapods, spermatogenesis starts only when the AGs are fully developed [11, 12]. In male prawn *M. rosenbergii* [9] and in intersex individuals of the Australian red claw Cray fish *Cherax quadricarinatus* removal of AG leads to cessation or regression of spermatogenesis [13].

In general, ablation is performed in hatcheries and research experiments to induce gonad development and molting in commercial crustaceans [14]. Earlier studies have emphasized more on the influence of eyestalk ablation on the gonad induction and growth by using different feeds [15]. Further, histological analysis appears to be a very sensitive parameter and is crucial in determining cellular changes in the target organs [16]. Besides, biochemical parameters are the best indicators for energy level of the biological system [17]. Studies related to effects of eyestalk neuropeptide hormones on the androgenic gland activity, male reproductive performance and biochemical changes in crustaceans are scarce hence the present attempt has been made to evaluate the same in freshwater male prawn *Macrobrachium rosenbergii*.

## MATERIALS AND METHODS

**Collection and Maintenance of Prawns:** *Macrobrachium rosenbergii* was collected from Aqua Nova hatchery, Kannathur, Chennai, Tamil Nadu, India. The prawns were transferred to the laboratory using aerated plastic bag and maintained in an aquarium with continuous aeration and optimum temperature ( $30\pm 2^\circ\text{C}$ ). During this period, the prawns were fed *ad libitum* with commercial pelletized feed and water was changed daily and maintained in the laboratory for 2-3 weeks for acclimatization before the start of the experiment.

**Experimental Design:** Prawns of five months old, weighing to  $22\pm 2\text{g}$  was taken for experimental studies. A total of 40 prawns were used and divided into 2 groups of each consisting 20 prawns. One group is served as intact (uneyestalk ablated) and another one is eyestalk ablated (experimental group). The experiments were performed in triplicate and maintained for a period of 30 days.

**Eyestalk Ablation:** Ablation of eyestalk removes the X-organ and sinus gland complex. Unilateral Eyestalk Ablation (UEA) was done using sterile surgical scissors following standard procedure. The ablated prawns were maintained in separate plastic troughs throughout the experiment.

**Body and Androgenic Gland Weight:** Body weights of the prawns were taken after properly blotting the animal in tissue paper without causing stress. At the end of experiment, the androgenic glands of both intact and ablated prawns were dissected out and weighed using an electronic balance.

**Gonadosomatic Index (GSI) and Hepatosomatic Index (HSI):** At the end of the experiment, gonads of both intact and ablated prawns were removed and the wet weights of the gonads were recorded using an electronic balance. The Gonadosomatic Index (GSI) and Hepatosomatic Index (HSI) were calculated following the method of Zhang *et al.* [18].

**Histology:** For histological studies, testis and androgenic gland was isolated from both intact and eyestalk-ablated prawns and fixed in Bouin's fixative. The samples were dehydrated through graded alcohol series and embedded in paraffin wax. Sections of 6-8  $\mu\text{m}$  thickness were taken, dehydrated and stained with Hematoxylin and Eosin. The stained sections were mounted using DPX and photomicrographs were taken using Leica 2500 microscope (Germany) [19].

**Scanning Electron Microscopy (SEM):** For scanning electron microscopy and rogenic gland was fixed in 4% glutaraldehyde buffered with 0.1M  $\text{PO}_4$  at pH 7.4 for 20 minutes. After post fixation, the samples were rapidly dehydrated in a graded acetone series and critically point dried with  $\text{CO}_2$ . Samples were mounted for SEM study and coated with 20nm gold in a polaron sputter coater with a rotating stage.

**Biochemical Analysis:** Protein: At the end of the experiment, prawns were dissected out and different reproductive tissues samples were taken and used for protein estimation. The samples such as testis and rogenic gland and hepatopancreas (100mg wet weight) were taken individually, homogenized with 10% trichloroacetic acid (TCA) and centrifuged for 10 min at  $9000 \times g$  at  $4^\circ\text{C}$ . Then the precipitate was dissolved in 1.0 N NaOH and used to measure the protein content. For each sample, the soluble protein concentration was determined spectrophotometrically at the wavelength of 595nm by the method of Coomassie Brilliant Blue G-250 described by Bradford [20]. Bovine serum albumin (BSA) was used as a standard.

**Lipid:** The total lipid content was analyzed using the vanillin-phosphoric acid method according to Folch *et al.* [21]. Hundred milligram of wet tissue of each sample was taken and homogenized with 0.5 ml of chloroform: methanol (2:1) and 0.5 ml of 0.9% NaCl was added and kept in a separating funnel at room temperature for 12 h. The lower phase was collected, 0.5 ml of conc.  $H_2SO_4$  was added, heated in boiling water for 10 min, cooled to room temperature and then 1 ml of phosphoric vanillin solution (13 mMol/l vanillin in 14 Mol/l phosphoric acid) was mixed immediately and held at room temperature for 30 min. The optical density was measured at 547 nm. Cholesterol was used as a standard.

**Statistical Analysis:** Data obtained from both the intact and ablated prawns were subjected to statistical analyses, such as one way analysis of variance (ANOVA) using SPSS 7.5 to determine whether the variations between the groups are significant.

## RESULTS

In the present study, eyestalk ablation has shown its effect on the androgenic gland activity in *Macrobrachium rosenbergii*. The androgenic gland activity was studied as a measure of observing the gonadosomatic and hepatosomatic indices and rogenic gland weight, histological and surface topographical changes in testis and androgenic gland in both the groups. Further, the biochemical variations in different reproductive tissues such as testis and rogenic gland and hepatopancreas were also assessed.

### Assessment of Male Reproductive Activity:

The GSI level increased in eyestalk ablated prawns compared to intact. In intact prawns, the GSI was  $1.91 \pm 0.03\%$  and in ablated prawn it was  $2.87 \pm 0.08\%$  at the end of experiment. In contrast, the HSI value decreased in eyestalk ablated prawns compared to intact. The HSI of intact prawn was  $8.42 \pm 0.56\%$  and in ablated prawn it was  $4.92 \pm 0.30\%$  (Fig. 1). The changes in the GSI level in ablated group differ significantly from that of intact group ( $P < 0.05$ ). With respect to the HSI level, intact group differed significantly than ablated group ( $P < 0.05$ ).

The androgenic gland weight in eyestalk ablated prawn was increased compared to intact prawns (Fig. 1).

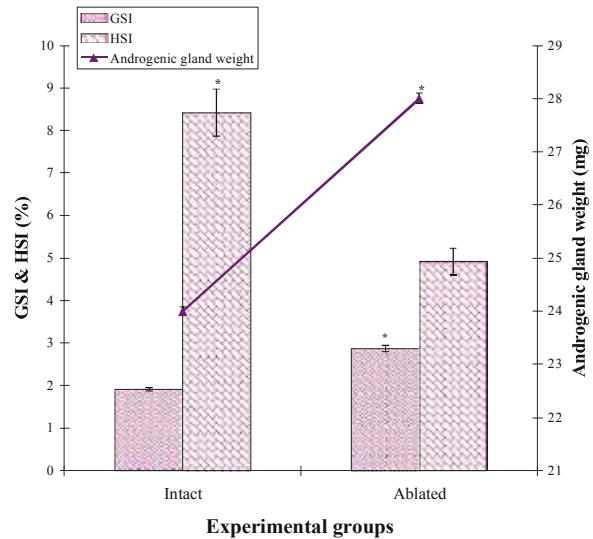


Fig. 1: Effect of eyestalk ablation on the GSI, HSI and androgenic gland weight in *M. rosenbergii* \* F test  $P < 0.05$ .

At the end of experiment, weight of the androgenic gland in ablated prawn was higher ( $28 \pm 0.10$  mg) than the intact prawn ( $24 \pm 0.08$  mg). Statistical analyses indicated that changes in the androgenic gland weight in ablated group differed significantly from that of the intact group ( $P < 0.05$ ).

### Cellular Level Changes in Different Reproductive

**Tissues:** The impact of eyestalk ablation on reproductive activity was studied in different reproductive tissues of the prawns and extrapolated that the structural changes were pronounced in testis and androgenic gland in intact and ablated groups. The intact prawn testis showed a normal architecture of the seminiferous tubules and normal distribution of spermatozoa in seminiferous tubules (Fig. 2A). However, the ablated prawn testis exhibited an increase in seminiferous tubule size and tightly packed mature spermatozoa with in seminiferous tubules (Fig. 2B).

Androgenic gland cellular level variations directly indicated that the function of the gland. In AG of intact prawn, epithelial cells were uniformly distributed and embedded in connective tissues (Fig. 3A). Whereas, in AG of ablated prawn, the abundance of epithelial cells along with connective tissues were observed. Based on the cellular level changes, increase in the number of the epithelial cells was enormous in ablated prawns than the intact prawns (Fig. 3B).

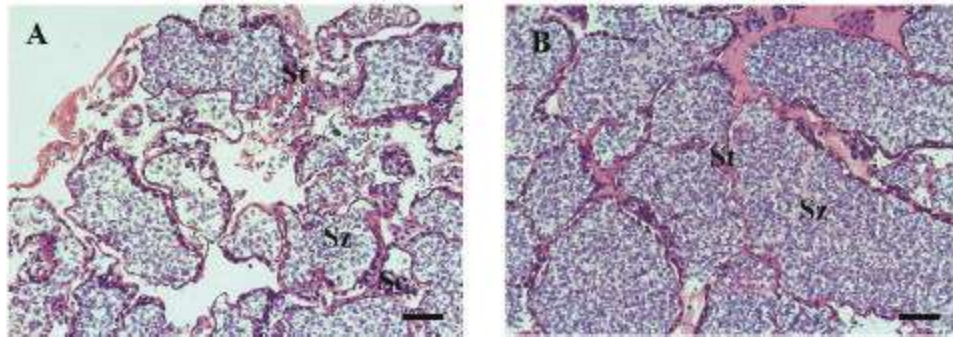


Fig. 2: (A) Intact prawn testis showing a normal architecture of the seminiferous tubules, spermatocytes and spermatozoa regular arranged in seminiferous tubules. (B) Ablated prawn testis showing increase the seminiferous tubule size and spermatozoa tightly packed with seminiferous tubules. Note increase the seminiferous tubule diameter and spermatozoa level in ablated prawn than intact. Bar: 50  $\mu$ m.

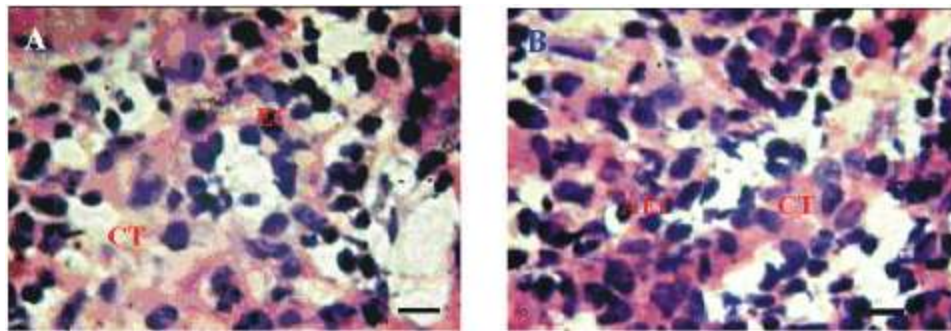


Fig. 3: (A) Intact androgenic gland showing the epithelial cells (EC) and connective tissue (CT). (B) Ablated prawn showing the abundance of epithelial cells (AEC) along with connective tissue (CT). Note increase the number of the epithelial cells in ablated prawn. Bar: 50  $\mu$ m.

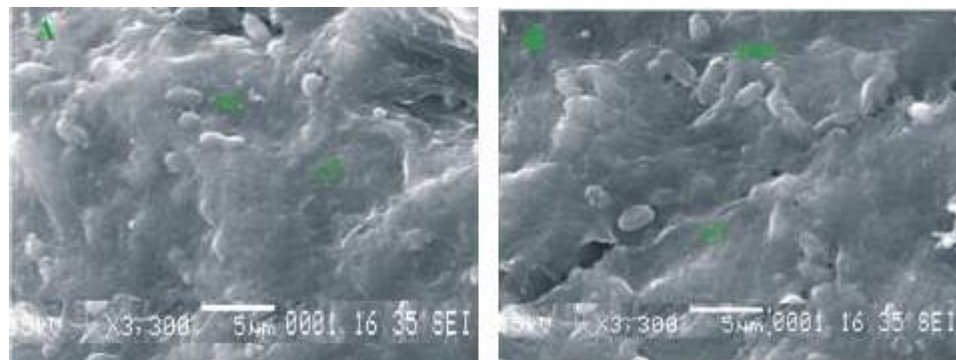


Fig. 4: (A) Intact prawn androgenic gland inner region showing the epithelial cells (EC) embedded with connective tissue (CT). (B) Ablated prawn androgenic gland showing abundance of mass of epithelial cells associated with connective tissues (CT). Note the mass of epithelial cells level varied in the intact and ablated groups.

#### Surface Topographical Changes in Androgenic Gland:

Scanning electron micrograph exhibited the inner region of AG in both intact and ablated prawn *M. rosenbergii* and inferred that AG inner region is remarkably varied in both intact and ablated groups. In intact prawn, mass of epithelial cells associated with

connective tissues were noticed (Fig. 4A). Besides in ablated prawns, the epithelial cells were abundantly embedded in the connective tissues as group (Fig. 4B). Based on the surface topographical variations, it was clear that the mass of epithelial cells were huge in ablated groups compared to intact groups.

Table 1: Effect of eyestalk ablation on the protein and lipid content (mg/g) in different tissues of *M. rosenbergii*

Biochemical contents in different tissues	Experimental groups	
	Intact	Ablated
<b>Protein content</b>		
Testis	40.61±2.79	43.34±2.85*
Androgenic gland	0.0401±0.014	0.054±0.0012*
Hepatopancreas	46.18±2.49*	39.17±2.46
<b>Lipid content</b>		
Testis	7.94 ± 1.14	10.30 ± 1.41*
Androgenic gland	0.0155 ±0.0081	0.01773±0.004*
Hepatopancreas	44.13 ± 2.04*	41.24±1.03

× ± SD is six observations. \* F test  $P < 0.05$

### Biochemical Changes in Different Reproductive Tissues:

Biochemical constituents such as total protein and lipid content assessed in testis and rogenic gland and hepatopancreas also showed variations in both intact and ablated prawns.

The total protein content increased in the test tissues except hepatopancreas of ablated prawn compared to intact. The total protein content of testis and rogenic gland and hepatopancreas in intact prawn is amounted to 40.61±2.79mg/g, 0.040±0.014mg/g and 46.18±2.49mg/g respectively. In ablated prawn, protein content increased in testis (43.34±2.85mg/g) and androgenic gland (0.054±0.001 mg/g). In contrast, protein content in hepatopancreas was significantly decreased and amounted to 39.17±2.46mg/g (Table 1). Statistical analyses indicated that the changes in the protein content in test tissues of ablated group differ significantly from that of intact group ( $P < 0.05$ ).

The lipid content of testis and rogenic gland and hepatopancreas in intact prawn was amounted to 7.94±1.14 mg/g, 0.016 ± 0.008 mg/g and 44.13±2.04 mg/g respectively. In ablated prawn, the lipid content remarkably increased in testis (10.30±1.41mg/g) and androgenic gland (0.018±0.004mg/g). Whereas in hepatopancreas of ablated prawn, the lipid content abruptly decreased to 41.24±1.03mg/g (Table 1). The changes in the lipid content in intact and ablated groups were differed significantly ( $P < 0.05$ ).

### DISCUSSION

From the present study, it was clearly evidenced that the eyestalk ablation in *M. rosenbergii* resulted in marked increase in GSI and androgenic gland weight, when compared to intact. However, the HSI level was decreased

in ablated prawns than intact. Likewise, Sanjeevraj *et al.* [22] found that the removal of eyestalk leads to increased gonadal weight in *M. rosenbergii*. Chakravarthy [23] noticed that, eyestalk ablation leads to increase in both male and female gonads with respect to size and maturity as evinced by GSI. Eyestalk hormonal factor involved in bringing about accelerate the gonadal maturation [24]. In bilateral eyestalk ablation in swimmer crab, *Portunus pelagicus* resulted in marked increase in the weight of testis and androgenic gland, when compared to intact [25]. Indian spiny lobster, *Panulirus homarus* the HSI was comparatively low in eyestalk-ablated lobster than in the intact [26]. The HSI was low in ablated lobsters as compared to intact, which may be due to the enhanced utilization of reserve materials stored in the hepatopancreas. Eyestalks were shown to produce GIH which plays a pivotal role in down-regulation of reproduction in crustaceans [26]. Eyestalk ablation experiments conducted in the present study have made it clear that eyestalk factor (GIH) exert inhibitory effect not only on gonads as well as AG, either directly or indirectly.

The present study clearly indicated that the eyestalk ablation induced the male reproductive activity as evidenced by increase in spermatozoa concentration in testis of *M. rosenbergii*. Similarly, eyestalk ablation in the crayfish *Cherax quadricarinatus* resulted in an inhibition on the mitotic division of spermatogonia to primary spermatocytes and a simultaneous increase in spermatozoa [27]. Accordingly, Otsu [28] suggested that eyestalk ablation during the sexually quiescent season led to a hyperactivity of the male genital system in *Paragonimus dehaani*. Eyestalk removal caused the enhancement of spermatophore formation in *Penaeus monodon* and *Penaeus vannamei* [29, 30]. Besides enhanced rate of spermatogenesis in *Metopograpsus messor*, when they were subjected to eyestalk ablation also reported. Similarly, occurrence of simultaneous acceleration of spermatogenesis was also reported in *Fenneropenaeus indicus* [31] and *Macrobrachium idella* [32]. Thus removal of eyestalks, the site of production of the GIH, has resulted in simultaneous acceleration of reproduction.

Our histological and SEM results demonstrated the hyperactivity of androgenic gland as marked by the abundance of epithelial cells is associated with connective tissue in the eyestalk ablated *M. rosenbergii*. Likewise, histological study of AG, after eyestalk ablation in *Portunus pelagicus* revealed that enormous increase in size and the signs of hyperactivity [33]. In correspondence, eyestalk ablation

resulted in hypertrophy of the AG compared to intact *M. rosenbergii* [34]. Similarly, eyestalk ablation in *Paratelphusa hydrodromous* resulted in increase in length and width of the AG, increase in the number of strands constituting the gland and finally the gland acquiring a puffy appearance [35]. Likewise, activation of AG has been reported in eyestalk ablated shrimps, *Penaeus canaliculatus* [36] and *Neocaridina denticulata* [37]. AG of the prawn *Penaeus hardwickii* on bilateral eyestalk ablation showed higher activity with hypertrophy and hyperplasia of the gland [38]. Ablated prawn AG cells cytoplasm showed dense granules as compared to the homogenous appearance in intact of *P. hardwickii*.

Biochemical studies are very important tool to assess the nutritional characteristics in biological system. The biochemical constituents in animal are known to vary with season of animal, stage of maturity, temperature and availability of food etc. The eyestalk hormones have known to influence the protein and lipid metabolism in crustaceans [39] which were found vary with times and species [40-42]. Hence, it was obvious that the eyestalk ablation induced the biochemical changes in different reproductive tissues such as testis and rogenic glad and hepatopancreas. Similarly, Koshio *et al.* [15] reported that neither unilateral eyestalk ablation nor feeding frequency affected the contents of the protein, lipid or the composition of the lipid class fatty acids of *M. rosenbergii*.

In the present study, the protein content increased in test tissues of eyestalk ablated *M. rosenbergii*. An increase of protein content 0.94-fold in testis, 0.74-fold in androgenic gland was recorded. In contrast, the decrease in protein content (1.18-fold) was observed in hepatopancreas. This trend was in agreement with other studies [43, 44]. Similarly, Balasubramanian and Suseelan [45] recorded the increased protein level increased in *Charybdis smithii* due to eyestalk ablation. In *Scylla serrata*, the elevation of protein content in different reproductive tissues due to eyestalk ablation was reported [46]. Anonymous [47] reported that the protein content was increased in blue crab due to eyestalk ablation. Eyestalk ablation induced the protein level in different tissues of *S. serrata* [48] was also observed. Accordingly, eyestalk ablation directly stimulated the protein level in *Portunus pelagicus* and *Portunus sanguinolentus* [49], *Scylla tranquebarica* [44]. However, the hepatic protein content was low in ablated lobsters as compared to the intact, which may be due to the enhanced

utilization of biochemical components in the hepatopancreas [50]. The above statement was in consistent with present results.

Lipids are high efficient of source of energy, which is equal to twice the energy of protein and carbohydrate [51]. Our results showed that the lipid content was higher in eyestalk ablated prawns compared to intact. An increase of lipid content 0.77-fold in testis and 0.87-fold in androgenic gland was found in ablated prawn than intact. In contrast, it was decreased 1.07-fold in hepatopancreas in ablated prawn *M. rosenbergii*. Similarly, in *Podophthalmus vigil* the lipid content increased in reproductive tissues due to eyestalk ablation [52]. Correspondingly, Balasubramanian and Suseelan [45] also recorded the eyestalk ablation induced lipid level from 6.2 to 7.6% in *C. smithii*. Eyestalk ablation induced lipid content in *Portunus pelagicus* [44] and *Portunus sanguinolentus* [49] was also recorded. The hepatic lipid level was low in ablated prawns as compared to the unablated prawns, which may be due to the enhanced utilization of reserve materials stored in the hepatopancreas [50].

On compilation of results on the histological and biochemical studies, it was inferred that the male reproductive system and AG are under the control of eyestalk neuro peptide hormones. In addition to the above, the AG which has been considered as an endocrine centre responsible for the differentiation of the male secondary sex characters in crustaceans. Eyestalk neuro peptide hormones play a crucial role in the successful functioning of male reproduction in *Macrobrachium rosenbergii* and its absence due to eyestalk ablation that caused changes in male reproductive activity and metabolism.

## ACKNOWLEDGEMENT

Financial supports from UGC-Dr. D. S. Kothari Post Doctoral Fellowship to Dr. P. Revathi gratefully acknowledged.

## REFERENCES

1. Sagi, A., L. Karp, Y. Milner, D. Cohen, A. Kuris and E.S. Chang, 1991. Testicular thymidine incorporation in the prawn, *Macrobrachium rosenbergii*: Moults cycle variations and ecdysteroid effects *in vitro*. Journal of Experimental Zoology, 259: 229-277.

2. Fingerman, M., 1997. Roles of neurotransmitters in regulating reproductive hormone release and gonadal maturation in decapod crustaceans. *Invertebrate Reproduction and Development*, 31: 47-54.
3. Adiyodi, K.G. and R.G. Adiyodi, 1970. Endocrine control of reproduction in decapod Crustacea. *Biological Review*, 45: 121-165.
4. DeMeusy, N., 1960. Différenciation des voles génitales males du crabe *Cacinus maenas* Linné. Rôle des pédoncules oculaires. *Biological Marine Science*, 1: 259-278.
5. Hoffman, D.L., 1968. Seasonal eyestalk inhibition on the androgenic glands of a protrandric shrimp. *Nature*, 218: 170-172.
6. Payen, G.G., J.D. Costlow and H. Charniaux-Cotton, 1971. Étude comparative de l'ultrastructure des glandes androgènes de crabes normaux et pédonculetomisés Pendant la vie larvaire ou après la puberté chez les espèces: *Rhithropanopeus harrisii* (Gould) et *Callinectes sapidus* Rathbun. *General and Comparative Endocrinology*, 17: 526-542.
7. Kuris, A., M.Z. Ra'anan, A. Sagi and D. Cohen, 1987. Morphotypic differentiation of male giant prawns, *Macrobrachium rosenbergii*. *Journal of Crustacean Biology*, 7: 219-237.
8. Sagi, A., A. Milstein, Y. Eran, D. Joseph, I. Khalaila, U. Abdu, S. Harpaz and I. Karplus, 1997. Culture of Australian redclaw crayfish (*Cherax quadricarinatus*) in Israel. II. Second grow out season of over wintered populations. *Israeli Journal of Aquaculture-Bamidgeh*, 49: 222-229.
9. Nagamine, C., A.W. Knight, A. Maggenti and G. Paxman, 1980. Effects of androgenic gland ablation on male primary and secondary sexual characteristics in the Malaysian prawn, *Macrobrachium rosenbergii* (De Man) (Decapoda, Palaemonidae) with first evidence of induced feminization in a nonhermaphroditic decapod. *General and Comparative Endocrinology*, 41: 423-441.
10. Taketomi, Y., 1986. Ultrastructure of the androgenic gland of the crayfish, *Procambarus clarkii*. *Cell Biology and International Reports*, 10: 131-136.
11. Payen, G., 1973. Etude descriptive des principales etapes de la morphogenese sexuelle chez un Crustace Decapodes a developement condense. PE crevisse *Pontastacus leptodactylus* (Eschscholtz 1823). *Annual Embryological. Morphogenesis*, 6: 179-206.
12. Taketomi, Y., M. Murata and K. Imakado, 1996. On the androgenic gland of the Crayfish, *Procambarus clarkii*. 1. Seasonal changes in the cell structure of the androgenic gland of the crayfish, *Procambarus clarkii*. *Mem. Fac. Gen. Education Kumamoto Univ. Natural Science*, 31: 65-72.
13. Khalaila, I., S. Weil and A. Sagi, 1999. Endocrine balance between male and female components of the reproductive system in intersex *Cherax quadricarinatus* (Decapoda: Parastacidae). *Journal of Experimental Zoology*, 283: 286-294.
14. Murugasan, R., P. Soundarapandian and K. Manivannan, 2008. Effects of unilateral eyestalk ablation on the biochemical changes of edible portunid crab *Charybdis lucifera* (Fabricius). *Journal of Fisheries and Aquatic Science*, 3(4): 82-86.
15. Koshio, S., S. Teshma and A. Kanazawa, 1992. Effects of unilateral eyestalk ablation and feeding frequencies on growth, survival and body compositions of juvenile freshwater prawn *Macrobrachium rosenbergii*. *Nip. Sui. Gak.*, 58: 1419-1425.
16. Dutta, G.J., 1996. Uridine diphosphate glucose and the synthesis of glucosides by mollusks. *Archives of Biochemistry and Biophysics*, 116(1): 399-405.
17. Mohan Raj, V., 2007. Effect of heavy metals cadmium and mercury on the eco physiology of Asian seabass *Lates calcarifer* (Bloch). Ph.D., Thesis University of Madras, Tamil Nadu, India.
18. Zhang, I.L., Z.H. Zuo, X.Y. Chen, Y. Zhao, S. Hu and C.G. Wang, 2007. Effect of tributyltin on the development of ovary in female cuvier (*Sebastiscus marmoratus*). *Aquatic Toxicology*, 83: 174-179.
19. Revathi, P., L. Arockia Vasanthi and N. Munuswamy, 2011. Effect of cadmium on the ovarian development in the freshwater prawn *Macrobrachium rosenbergii* (De Man). *Ecotoxicology and Environmental Safety*, 74: 623-629.
20. Bradford, M.M., 1976. A rapid and sensitive method for the quantification of microgram quantities of protein utilizing the principle of protein-dye binding. *Analytical Biochemistry*, 72: 248-254.
21. Folch, J., M. Lees, H. Sloane and G.H. Stanley, 1956. A simple method for the isolation and purification of total lipids from animal tissues. *Journal of Biological Chemistry*, 226: 497-509.

22. Sanjeevraj, G., B. Ravikumar and P. Gopalakrishnan, 1997. Effect of eyestalk ablation on molting and growth of different size groups of *Macrobrachium rosenbergii*. Proceedings of the National Seminar on water quality issues in aquaculture systems, (Dec. 18-19): 147.
23. Chakravarthy, M.S., 1992. Effect of eyestalk ablation on moulting and growth in prawn *Macrobrachium rosenbergii*. Indian Journal of Marine Science, 21: 287.
24. Ahmad Perviz, P., S. Manohar, J. Malabika Sikadar-bar, H. Ahmad Khan and A. Abdullah Wani, 2011. Studies on the effect of unilateral eyestalk ablation in maturation of gonads of a freshwater prawn *Macrobrachium dayanum*. World Journal of Zoology, 6(2): 159-163.
25. Sroyraya, M., C. Chotwiwatthanakun and M.J. Stewart, 2010. Bilateral eyestalk ablation of the blue swimmer crab, *Portunus pelagicus*, produces hypertrophy of the androgenic gland and an increase of cells producing insulin-like androgenic gland hormone. Tissue Cell, 42(5): 293-300.
26. Radhakrishnan, E.V. and M. Vijayakumaran, 1984. Effect of eyestalk ablation in the spiny lobster *Panulirus homarus* (Linnaeus): 3. On gonadal maturity. Indian Journal of Fisheries, 31(2): 209-216.
27. Khalaila, I., R. Manor, W. Simy, Y. Granot, R. Keller and A. Sagi, 2002. The eyestalk-androgenic gland-testis endocrine axis in the crayfish, *Cherax quadricarinatus*. General and Comparative Endocrinology, 127: 147-156.
28. Otsu, T., 1963. Bihormonal control of sexual cycle in the freshwater clam, *Pohmon dehaani*. Embryo, 8: 1-20.
29. Leung-Trujillo, J.R. and A.L. Lawrence, 1985. The effect of eyestalk ablation on spermatophore and sperm quality in *Penaeus vannamei*. Journal of World Marine Society, 22: 244-251.
30. Leung-Trujillo, J.R. and A.L. Lawrence, 1991. Spermatophores generation time in *Penaeus setiferus*, *P. vannamei* and *P. stylirostris*. Journal of World Marine Society, 22: 244-251.
31. Muthuraman, A.I., 1986. Biochemistry and physiology of semen in penaeid prawns. PhD. Thesis. University of Calicut, Kerala, India.
32. Sreekumar, S. and R.G. Adiyodi, 1982. Role of eyestalk principle(s) in spermatogenesis of the freshwater shrimp, *Macrobrachium idella*. 1<sup>st</sup> Int. Biennial Conference on Warm Water Aquaculture: Brigham Young University, Hawaii. Proceedings, pp: 406-411.
33. Sroyraya, M., C. Chotwiwatthanakun, M.J. Stewart, N. Soonklang and N. Kornthong, 2010. Bilateral eyestalk ablation of the blue swimmer crab, *Portunus pelagicus*, produces hypertrophy of the androgenic gland and an increase of cells producing insulin-like androgenic gland hormone. Tissue Cell, 42: 293-300.
34. Awari, S.A. and D. Kiran, 1999. Histological and histochemical study of androgenic gland of *Macrobrachium rosenbergii* (De Man). Journal of Aquatic Tropic, 14: 101-112.
35. Adiyodi, R.G., 1984. Seasonal changes and the role of eyestalks in the activity of the androgenic gland of the crab, *Paratelphusa hydrodromous* (Herbst). Comparative Physiology and Ecology, 9: 427-431.
36. Choy, S.C., 1987. Growth and reproduction of eyestalk ablated *Penaeus canaliculatus* (Crustacean: Penaeidae). Journal of Experimental Marine Biology and Ecology, 112: 93-107.
37. Taketomi, Y., M. Nishino and K. Yoshizumi, 1997. Effects of eyestalk hormone on the androgenic glands of the shrimp. *Neocaridina denticulate*. Hydrobiology, pp: 79-82.
38. Kulkarni, G., R. Nagabhushnam and P.K. Joshi, 1984. Neuroendocrine control of reproduction in the male penaeid prawn, *Parapenaeopoda hardwickii* (Crustacea: Decapoda, Penaeidae) Hydrobiologia, 180: 281-289.
39. Hignam, H.C. and L. Hill, 1979. The Comparative Endocrinology of the Invertebrates. Edward Arnold Publishers, London, pp: 209.
40. Vernberg, F.J. and J. Vernberg, 1974. Pollution and physiology on marine organisms, Academic press, New York, pp: 492.
41. Madhyasthan, M.N. and P.V. Rengnekhar, 1979. Metabolic effects of eyestalk removal in each crab *Varana literate*. Hydrobiology, 48: 25.
42. Soundarapandian, P., 1996. Effects of unilateral eyestalk ablation on growth and biochemical composition in the juveniles of the river prawn *Macrobrachium malcolmsonii* (H. Milne Edwards). PhD Thesis, Annamalai University, India, pp: 102.

43. Sheen, S.S. and L.R. D' Aramo, 1991. Response of juvenile freshwater, *Macrobrachium rosenbergii*, to different levels of cod liver/corn oil mixture in a semi-purified diet. *Aquaculture*, 93: 121-134.
44. Thirunavukkarasu, N., 2005. Biology, Nutritional evaluation and utilization of mud crab *Scylla tranquebarica* (Fabricius, 1798). PhD Thesis, Annamalai University, India, pp: 126.
45. Balasubramanian, C.P. and C. Suseelan, 2001. Biochemical composition of the deepwater crab *Charybdis smithii*. *Indian Journal of Fish*, 48: 333-335.
46. Prasad, P.N. and B. Neelakantan, 1989. Fecundity of the mud crab, *Scylla serrata* (Forsk.) . *Mahasagar*, 22: 23-28.
47. Anonymous, S., 1999. Crustaceans, crab, blue, cooked, moist heat. Blue crab-nutrition. Results from the USDA. Nutrient Database for Standard Reference, pp: 1-3.
48. George, C. and K. Gopakumar, 1987. Biochemical studies on crab *Scylla serrata*. *Fisheries Technology*, 24: 57-61.
49. Radhakrishnan, C.K., 1979. Studies on portunid crabs of porto Novo (Crustacea: Decapod: Brachyura). Ph.D Thesis, Annamalai University, India, pp: 129.
50. Varalakshmi, K.N. and Ravichandra Reddy, 2010. Effects of Eyestalk Ablations on Growth and Ovarian Maturation of the freshwater prawn *Macrobrachium lanchesteri* (de Man). *Turkish Journal of Fisheries and Aquatic Science*, 10: 403-410.
51. Okuzumi, M. and T. Fujii, 2000. Nutritional and functional properties of squid and cuttlefish. 35<sup>th</sup> Anniversary of commemorative publication, pp: 223.
52. Radhakrishnan, C.K. and R. Natarajan, 1979. Nutritive value of the crab *Podophthalmus vigil* (Fabricius). *Fisheries Technology*, 16: 37-38.