

Adhesive Vs Implant Retained Fingers Prosthesis: A Comparative Study on Esthetic and Functional Outcome

¹Nimit Thongpulsawasdi, ²Pokpong Amornvit, ³Dinesh Rokaya and ⁴Konrawee Keawcharoen

¹Orthopaedic Surgery Clinic, Golden Jubilee, Medical Centre,
Mahidol University, NakonPathom, Salaya, Thailand

^{2,3}Maxillofacial Prosthetic Clinic, Department of Prosthodontics,
Faculty of Dentistry, Mahidol University, Bangkok, Thailand

⁴Maxillofacial Surgery Clinic, Golden Jubilee, Medical Centre,
Mahidol University, NakonPathom, Salaya, Thailand

Abstract: Fingers have an important role in the esthetic and function. The amputation of finger leads to psychological problems. Though several reconstructive techniques may exist for the reconstruction, the use of finger prosthesis is also a suitable alternative option. The retention may be obtained from friction, adhesive and implant. This article describes a comparison between the adhesive and implant retained finger prosthesis used in the rehabilitation of the finger defect of left hand in 20-year-old male. Part of the index, middle and ring finger of the left were missing due to trauma. Implant retained was used in the index and middle finger whereas adhesive retained was used in the ring finger. To reduce the operating time and hospital visits, a one-stage technique for implant placement was done. The esthetic and functional outcome were evaluated. The study showed that, both the adhesive and the implant retained finger prosthesis increase the overall esthetic outcome of the hand whereas the implant retained finger prosthesis showed more functional outcome. The implant retained finger prosthesis tends to be more retentive, functional and more patient acceptance than adhesive retained finger prosthesis. So, implant retained finger prosthesis is a better choice for the prosthetic rehabilitation of finger defect and in case where implant cannot be placed, the adhesive retained finger prosthesis is an alternative to implants retained finger prosthesis.

Key words: Trauma • Implant Retained • Adhesive Retained • Finger Prosthesis

INTRODUCTION

The loss of the fingers causes of trauma, disease or congenital abnormality whereas trauma being the most common. These which results in functional deficiencies, esthetic problem and social dysfunction for the patient. The rehabilitation can be done by two methods; reconstructive surgery and prosthesis [1]. Several techniques such as toe-foot-transfer, distraction osteogenesis and osteo-cutaneous flap [2]. The esthetic outcome of these reconstructive surgical techniques is unpredictable.

The use of silicone finger prosthesis represents an alternative technique which has adequate esthetics. The finger prosthesis offers the best option because of good esthetic result and is noninvasive procedure. The retention can be obtained from friction, adhesive or bone anchored implants. Bone anchored implant is used since 1994 as described by Branemark and the surgery for implant placement has initially been described as a two-stage technique. But the comparison between one-stage and two-stage technique for implant placement for implant retained finger prosthesis have shown that one-stage technique is more safe, reliable [4].

Corresponding Author: Pokpong Amornvit, Maxillofacial Prosthetic Service, Faculty of Dentistry,
Mahidol University, 6 Yothi Street, Bangkok 10400, Thailand.
Tel: +66-891616260.

MATERIALS AND METHODS

A 20-year-old male had esthetic problem due to lost this index, middle and ring fingers of the left hand from industrial accidents (Fig. 1). On examination, the left hand showed his index and middle fingers were amputated at the level of proximal phalange and ring finger was amputated at the level of distal phalange. He gave no other relevant medical history. His primary concern was an esthetic problem especially at the social gatherings. Radiographic examinations were done in palmar projection (Fig. 2) and lateral projection (Fig. 3) to evaluate the remaining bone and its thickness. After consultation, the patient decided to choose the implant retained prosthesis for the index and middle finger and the conventional adhesive retained prosthesis for his ring finger.

Implant Retained Finger Prosthesis: Implant retained finger prosthesis was planned in index and middle finger. At the time of surgery, left brachial nerve block was done and hemostasis was obtained using the tourniquet at 250 mmHg. Then, skin incision was made at the implant site. The position and the angulation of the implants were guided by the fluoroscopy radiation. Then, implant of 4.7 mm diameter X 17mm length (Osseo Speed, Astra Tech, Molndal, Sweden) were placed into the medullary canal with the insertion torque more than 35 Ncm in both fingers (Figure 4). Radiographs were taken to verify the implant position. The initial stability was noted 65 Implant Stability Quotient (ISQ) using Resonance Frequency Analysis (RFA) in the index finger and 68 in the middle finger. The bone density in both fingers was observed as Type IV according to Lekholm and Zarb classification.⁵ Then, the skin flaps were repositioned using the sutures and covered the fixture. Then, the skin over the implant sites was punched and abutments were placed with 20 Ncm in both fingers (Fig. 4). The nylon sutures were removed 10 days postoperatively.

In the 8 weeks follow up, the stability of the implants were noted 72 ISQ by RFA in both fingers (Fig. 5). Then, an impression of the left hand was made with alginate (Jeltrate, Dentsply, York, Pennsylvania, USA) with the implant positioned on the index and middle finger and cast was poured with Type IV dental stone (Lafarge, Prestia, Meiel, France). Then the heat resin (Vertex-Dental, Zeist, Netherlands) substructure was fabricated and attached to the implant over which Wax pattern of finger was made. Then the wax pattern (Carvex TT 100 soft, Carvex, Haarlem, Holland) was sculptured and tried on patient till the patient was satisfied (Fig. 6).

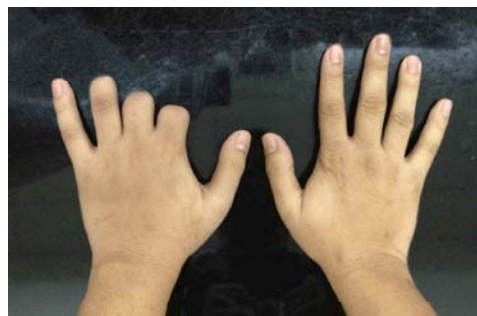

Fig. 1: Preoperative picture of the patient showing the defect of index, middle and ring finger of the left hand

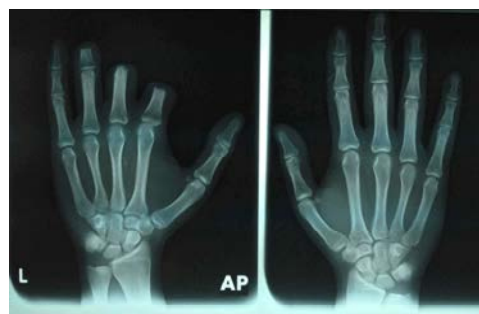

Fig. 2: Radiographic examination done at palmar projection showing defect of the index, middle and ring finger of the left hand

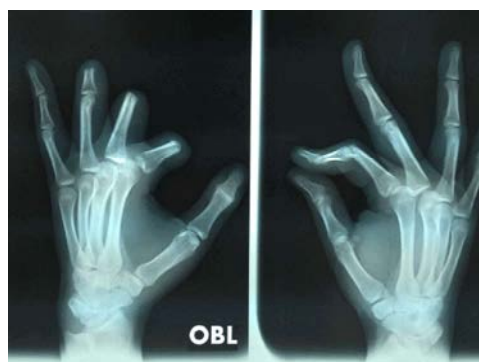

Fig. 3: Radiographic examination done at lateral projection showing defect of the index, middle and ring finger of the left hand

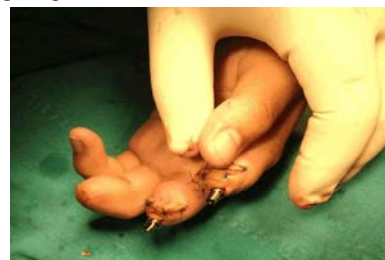

Fig. 4: Placement to the implant and abutment in index and middle finger of the left hand

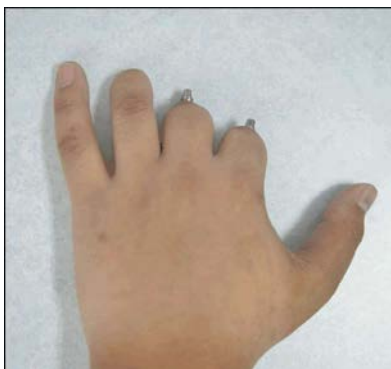

Fig. 5: Healing of soft tissue around abutment at 8 weeks follow up

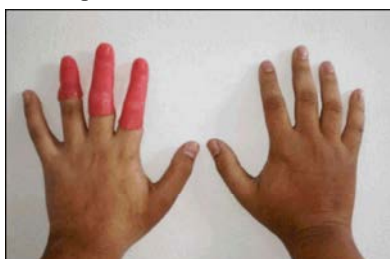


Fig. 6: Wax try-in of the finger prostheses



Fig. 7: Final silicone finger prostheses after external staining

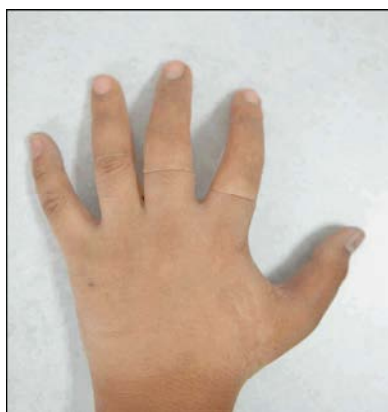

Fig. 8: Final silicone finger prostheses in patient; adhesive retained in the ring finger and implant retained in the index finger and the middle finger of the left hand



Fig. 9: Final silicone finger prostheses during the function; holding a glass of water

When the patient was satisfied with the wax pattern, it was transformed to the silicone finger prostheses (Silastic, MDX 4-4210, Medical grade silicone elastomer, Factor II, Lakeside, AZ, USA) by curing at room temperature and done external staining (Fig. 7). The prosthesis was delivered to the patient (Fig. 8). He was happy with the esthetic and functional outcome (Fig. 9).

At 6month follow-up, both of the implants showed an optimal degree of osseous integration with the absence of infection but mild peri-implantitis was seen with no other complications. It was managed with proper hygiene maintenance. He was given the hygiene maintenance of the implant and the prosthesis. After 8 months follow up no peri-implantitis was seen.

Adhesive Retained Finger Prosthesis: An impression of the left hand was made with alginate (Jeltrate, Dentsply, York, Pennsylvania, USA) and cast was poured with type IV dental stone (Lafarge, Prestia, Meiel, France). Then, the wax pattern (Carvex TT 100 soft, Carvex, Haarlem, Holland) was sculptured and tried on patient till the patient was satisfied (Fig. 6). When the patient was satisfied with the wax pattern, it was transformed to the silicone finger prostheses (Silastic, MDX 4-4210, Medical grade silicone elastomer, Factor II, Lakeside, AZ, USA) by curing at room temperature and done external staining (Fig. 7). The prosthesis was delivered to the patient (Fig. 8) and advised to use the Daro adhesive (Daro Adhesive Regular Strength, Factor II, Lakeside, AZ, USA) while wearing the prosthesis.

The finger Prostheses were delivered to the patient. He was happy with the esthetic outcome. At 6month follow-up, there was no infection and other complications but mild discoloration at the margins of the prosthesis.

RESULTS

Comparison between Implant vs Adhesive Retained Finger Prostheses is shown in (Table 1). It showed that the cost of implant retained was higher than the adhesive retained prosthesis. Regarding the implant retained finger prosthesis in index and middle finger, mild peri-implantitis was seen and it was managed after hygiene maintenance. Regarding the adhesive retained finger prosthesis, prosthetic complications were seen; discoloration and tear at the margins of the prosthesis.

The overall prognosis of the implant and adhesive retained prosthesis was satisfactory and the patient was happy with the prostheses.

DISCUSSION

In finger defect, trauma is the most common cause as in this case. It presents various levels of amputation; metacarpal or phalangeal bone. Most often, distal and middle part of the phalangeal bone is affected.

The amount of remaining tissue is the key for choosing the mode of retention for the finger prosthesis. Friction is only used when we can use a soft tissue undercuts it was absent in the ring finger of left hand this case. In this case, the ring finger was suitable for the adhesive retained finger prosthesis as the defect is small and retention can be obtained from the remaining bone and tissue (Fig. 1). Adhesive retained is a conventional and conservative method, as it is noninvasive and no surgical complications. The main advantage of adhesive retained is cheaper and ease of the hygiene maintenance. The adhesive retained finger prosthesis is useful when the presence of inadequate bone quality and quantity, or the systemic health of the patient contraindicates the surgery like in osteoporosis, or patient not willing to go for implant surgery. In this case, bone quality and quantity was inadequate in ring finger, so we used adhesive retained implant prosthesis. We used Daro adhesive system (Factor II, Lakeside, AZ, USA). These are water based adhesive. These adhesives in water emulsion have proven to be excellent and good patient acceptance. The complications of adhesive are: tearing the margins of the prosthesis, prosthesis discoloration and allergic reaction. In this case we used regular strength as it offered optimal strength and to increase the longevity of the prosthesis.

The prosthetic retention of finger from the friction or adhesive is challenging if the part of the finger is missing at the level of proximal phalange or metacarpal. In such

cases, the implant retained finger prosthesis offers the best option to improve the retention and stability. The case selection is important; the systemic health of the patient and bone quality and quantity of the finger bone for the implant placement. The phalangeal bone consists of proximal, middle and distal in all finger fingers except in the thumb which has only proximal and distal. The quality of the bone is greatest in proximal, moderate in middle and least in distal part of the phalangeal bone as seen in X-ray (Fig. 2-3).

The implant retained finger prosthesis presents various advantages; provides optimal retention, prevents discoloration and tearing of the margin of the prosthesis and better aesthetic than other methods of retention. Finite element study showed that when the force was applied along the long axis of the implant, the maximum stresses were located around the neck of the implant and cortex bone received more stress than cancellous bone [6]. The prosthesis was fabricated in such a way to prevent stress around the neck of the implants and instructions were given to the patient regarding reducing the stress over the implants. Patients can perform some functions also and allows a partial recovery of the tactile sensation to some extent by transferring stimuli to the bone through implant because of the direct pressure of the implant on the bone [7-9]. Our patient is able to perform certain daily manual activities: writing, typing on the computer, holding objects like cups (Fig. 9). Implant retained finger prosthesis presents minimal risk of infection and implants, complications by the optimal hygiene of the wounds. The major complications are: lack of osseous integration of the implant which is very rare, detachment of the prosthesis or lack of acceptance by the patient. In our case, mild peri-implantitis was observed and was managed and hygiene instructions were given.

Previous authors have considered two-stage surgery for the implant placement primarily for two reasons; to prevent early failure due to loading and to prevent infection [3,9,10]. The number of stages for implant placement depends on the primary stability of the implant and the quality of the bone. The number of stages for implant placement depends on the primary stability of the implant and the quality of the bone. Amornvit *et al.*, presented one-stage technique for the implant placement in implant retained finger prosthesis [4]. This technique is safe, reliable, more efficient with less operating time and hospital visits compared to the two-stage technique and more predictable procedure in metacarpal and phalangeal bone.

Table 1: Comparison between implant vs adhesive retained finger prosthesis

Features	Implant Retained Finger Prosthesis	Adhesive Retained Finger Prosthesis
1. Finger	Index and middle finger	Ring finger
2. Esthetic	High	Medium to low
3. Functional outcome	High to medium	Low
4. Cost	Higher	Lower
5. Surgical Complications	Mild peri-implantitis around the prosthesis and was managed	N/A
6. Prosthetic Complications	Not seen	Mild discoloration and tear at the margins of the prosthesis
7. Discomfort while wearing prosthesis	No	Yes

The durability of the prosthesis is around 1-3 years and depends on the activity of the patient. The implant retained increases the durability of the finger prosthesis [11,12]. The comparison between adhesive and implant retained finger prosthesis is shown in the (Table1). Furthermore, long term follow up is necessary to see long term results. Further clinical studies are required to provide significant results.

CONCLUSION

This case study showed that, both the adhesive and the implant retained retained finger prosthesis increase the overall esthetic outcome of the hand whereas the implant retained finger prosthesis showed more functional outcome. The implant retained finger prosthesis tends to be more retentive, functional and more patient acceptance than adhesive retained finger prosthesis. So, implant retained finger prosthesis is a better choice for the prosthetic rehabilitation of finger defect and in case where implant cannot be placed, the adhesive retained finger prosthesis is an alternative to implants retained finger prosthesis.

REFERENCES

- Aydin, C., S. Karakoca and H. Yilmaz, 2007. Implant-retained digital prostheses with custom-designed attachments: A clinical report. *J. Prosthet. Dent.*, 97:1 91-195.
- Doppen, P., M. Solomons and S. Kritzinger, 2009. Osseointegrated finger prostheses. *J. Hand Surg. Eur.*, 34: 29-34.
- Huber, H. and S.P. Studer, 2002. Materials and techniques in maxillofacial prosthodontic rehabilitation. *Oral Maxillofac. Surg. Clin. North Am.*, 14(1): 73-93.
- Lundborg, G., P.I. Branemark and B. Rosen, 1996. Osseointegrated thumb prostheses: a concept for fixation of digit prosthetic devices. *J. Hand Surg. Am.*, 21(2): 216-21.
- Amornvit, P., D. Rokaya, K. Keawcharoen, S. Raucharernporn and N. Thongpulsawasdi, 2013. One-Vs two-stage Technique for Implant Placement in Finger Prosthesis. *J. Clin. Diagn. Res.*, 7(9): 1956-1958.
- Lekholm, U. and G.A. Zarb, 1985. Patient selection and preparation. In: P.I. Branemark, G.A. Zarb and T. Albrektsson, editors. *Tissue-integrated prostheses-Osseointegration in Clinical Dentistry*. Chicago: Quintessence Publishing Co; pp: 199-209.
- Amornvit, P., D. Rokaya, K. Keawcharoen and N. Thongpulsawasdi, 2013. Stress Distribution in Implant Retained Finger Prosthesis: A Finite Element Study. *J. Clin. Diagn. Res.*, 7(12): 2851-2854.
- Cervelli, V., D.J. Bottini, A. Arpino, M. Grimaldi, M. Rogliani and P. Gentile, 2008. Bone-anchored implant in cosmetic finger reconstruction. *Annales de chirurgieplastiques the 'tique*, 53: 365-367.
- Rydevik, B., V. Shubayev and R. Myers, 2005. Osseoperception. In: P.I. Branemark, S. Chien, H.G. Gröndahl and K. Robinson, editors. *The Osseointegration Book: From Calvarium to Calcaneus*. Berlin: Quintessence, pp: 149-156.
- Aydin, C., S.K. Nemli and H. Yilmaz, 2013. Esthetic, functional and prosthetic outcomes with implant-retained finger prostheses. *Prosthet. Orthot. Int.*, 37(2): 168-74.
- Branemark, P.I., B.O. Hansson, R. Adell, U. Breine, J. Lindström, O. Hallén and A. Ohman, 1977. Osseointegrated implants in the treatment of the edentulous jaw: experience from a 10-year period. *Scand J. Plast. Reconstr. Surg. Suppl.*, 16: 1-132.
- Huber, H. and S.P. Studer, 2002. Materials and techniques in maxillofacial prosthodontics rehabilitation. *Oral Maxillofac. Surg. Clin. North Am.*, 14(1): 73-93.