

Study on the Prevalence and Pathology of *Gongylonema pulchrum* (Gullet Worm) of Sheep from Iran

¹Ali Eslami, ²Javad Ashrafihelan and ³Nasrollah Vahedi

¹Veterinary Department, Faculty of Veterinary Medicine,
University of Tehran, Tehran, Iran

²Department of Pathobiology, Faculty of Veterinary medicine, University of Tabriz, Tabriz, Iran

³Member of Scientific Board in Research Center of Agriculture, Mazandaran, Iran

Abstract: Seasonal sampling was carried out during 2006 and 350 esophagi (summer=60, autumn=135, winter=70 and spring=85) were examined at meat inspection for gongylonemiasis and its induced pathological lesions. The number and location of *G. pulchrum* in each esophagus were recorded and retrieved from the mucosa and preserved in 70% alcohol containing 5% glycerin. Several 1cm×1cm pieces were cut from the affected regions of esophagus fixed in 10 % buffered formalin solution, 5-6 microns thick sections were serially cut from paraffin blocks and stained with hematoxylin and eosin (HandE). Our findings revealed that out of 350 esophagi examined 16 (4.57%) harbored *G. pulchrum*, the majority of which (80%) were embedded in a zipper fashion in the third distal portion and the rest (20%) in entire esophagus. Mean number of worm was low (10) but 100 worms was collected from a single esophagus. Although winter was the least infected season, no seasonality was observed. Little gross lesions was noticed in the infected esophagi but histopathological findings revealed the presence of cross or coiled section of *G. pulchrum* in the stratified squamous epithelium causing mild to severe acanthosis, rete ridge formation, parakeratosis, congestion, edema and slight to severe chronic eosinophilic inflammatory reactions.

Key words: *Gongylonema pulchrum* • Gullet worm • Sheep • Iran

INTRODUCTION

Gongylonema pulchrum lies in a zipper fashion in the wall of esophagus or upper alimentary tract of sheep, goat, cattle, pig, zebu, buffalo and less frequently horse, camel, donkey, wild boar and man [1]. Accordingly it was recorded from 45% and 49.7% of cattle [2, 3], 21% of sheep [4], 5.6% of wild sheep [5], 35% of wild boars [6], donkey [7] and man [8] from Iran. Although adult worm do not considers pathogenic in animals but clinical symptoms were reported from cattle [9], marmoset [10] and man [8, 11] and development of squamous cell carcinoma in a Vari (*Lemur Macao variegates*) [12] was attributed to infection with *G. pulchrum*.

This study was performed in order to determine the prevalence, intensity and pathological lesions induced by *G. pulchrum* in sheep from Iran

MATERIALS AND METHODS

During four seasons of 2006, at meat inspection in Babol abattoir north of Iran, 350 esophagus of sheep (winter=70, spring=85, summer=60 and autumn=135) were examined for gongylonemiasis. Any changes in the infected esophagi were recorded. The worms embedded in zigzag tracks were carefully retrieved and preserved in 70% alcohol containing 5% glycerin after recording their location and number. The severity of parasite infestation was evaluated on the basis of number of burrowed tunnels in esophageal epithelium with or without parasite. The presence of less than 5, 5 to 9 and 10 or more burrowed tunnels were taken as mild, moderate and high infestation. Several 1cm×1cm pieces were cut from affected regions of preserved infested esophagi in 10 % buffered formalin solution and processed in a tissue

Corresponding Author: Dr. Ali Eslami, Veterinary Department, Faculty of Veterinary Medicine,
University of Tehran, Tehran, Iran, Tel: 0098-21-26211042.
Fax: 0098-21-66333222, E-mail: ayslami@ut.ac.ir.

processor (Jung Histokinette 2000, Leica, Germany) and paraffin blocks made, from which several 5-6 microns thick sections were serially cut with a microtome (Jung Histo-cuts, Leica, Germany) and stained with hematoxylin and eosin (HandE) [13]. Histopathologically, the sections were examined by light microscopy (Olympus CH₃₆ RF₂₀₀, Japan) and digitally photographed with a photomicrograph (Olympus DP12, U-TVO.5 XC-2, Japan).

The histopathologic changes of the epithelium of esophagi such as acanthosis and parakeratosis were assessed by using a semiquantitative system. Accordingly less than 10, 10 to 14 and 15 to 19 and 20 or more cell layers in the stratum spinosum and stratum corneum were taken as normal (free of pathologic changes), mild, moderate and severe acanthosis and parakeratosis respectively.

The same system was used to assess the extent of inflammation reactions. Therefore in high power microscopic field (×400), less than 5 eosinophils, mixed with neutrophils and lymphocytes, 5 to 9 and more than 10 were interpreted as mild, moderate and severe inflammation reactions.

RESULTS

Out of 350 esophagi examined 16 (4.56%) were found to be infected with *G. pulchrum*. The positions of the 161 worms along the esophagi were steadily increased toward the distal portion of the esophagus.

The data in table 1 would indicate that the percentage and mean number of worm infestation were low, although 100 *G. pulchrum* were collected from a single esophagus. Assessment of severity of infestation revealed that 12, 3 and 1 out of 16 infected esophagus harbored mild, moderate and massive worm respectively. The frequency distribution of *G. pulchrum* was over dispersed, because,

12, 3 and 1 out of 16 infected esophagi harbored 1-4, 10-14 and 100 parasites respectively representative of a negative binomial distribution. The results of seasonal variations are shown in Table 2.

Statistically no seasonality was observed, although winter was the least infected season.

Little gross lesions indicative of a pathological condition were associated with any infected esophagi. Tunnels produced by *G. pulchrum* were filled with egg shells, erythrocytes, neutrophils, eosinophils, cellular and fecal debris and lodged usually in the parakeratotic stratum corneum but sometimes in the stratum granulosum (Fig. 1).

Several white to pink zigzag burrowed tunnels were present in the mucosa, occasionally in the lamina propria, containing a worm, 62-149 mm long, where induced excessive cornification of stratum granulosum. These tunnels were filled with eggshells, erythrocytes, neutrophils, eosinophils, cellular and fecal debris and lodged usually in the parakeratotic stratum corneum but sometimes in the stratum granulosum (Fig. 1).

Histopathological findings showed a mild acanthosis, with evidence of hydropic change in acanthocytes, rete ridges formation, parakeratotic hyperkeratosis (parakeratosis) in the stratified squamous epithelium of the esophagi. The latter were very severe in the esophagus harboring 100 worm (Fig. 2).

Mild chronic inflammatory reaction was recorded with mild congestion, edema and mild to severe eosinophilic and neutrophilic polymorphonuclear inflammatory cells infiltration, mixed with lymphocytes and plasma cells, in the lamina propria and occasionally submucosa of infected esophagi. These changes were more severe in the esophagus harbored more than 100 worms (Fig. 2).

Table 1: Prevalence and intensity of *G. pulchrum* in 350 sheep esophagus

No Examined	No Infected	% Infection	Mean (range)	Location
350	16	4.56	10 (1-100)	80%× and 20%××

* D=Distal Portion ** E=Entire esophagus

Table 2: Seasonal variations of Gongylonematiasis in 350 Esophagi of sheep

Season	No Examined	No Infected	% Positive
Winter	70	1	1.4
Spring	85	6	4.57
Summer	60	4	6.6
Autumn	135	5	3.7

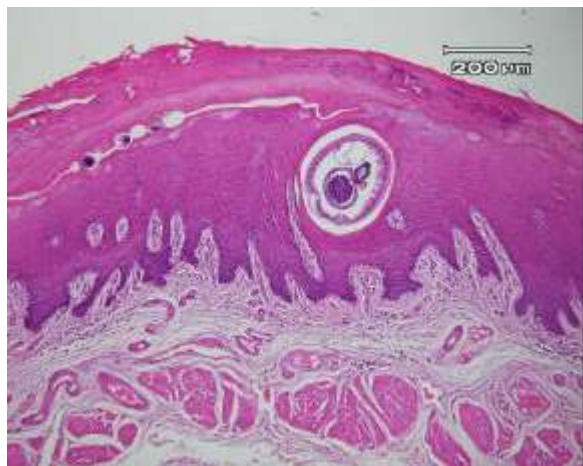

Fig. 1: Gongylonemiasis in sheep: acanthosis, with rete ridges formation, parakeratotic hyperkeratosis (parakeratosis), a burrowed tunnel, with eggshells and debris and without parasite and a cross section of adult helminth lied in burrowed tunnel under the stratum corneum are present. There is a mild eosinophilic inflammatory reaction (HandE, 100 ×).

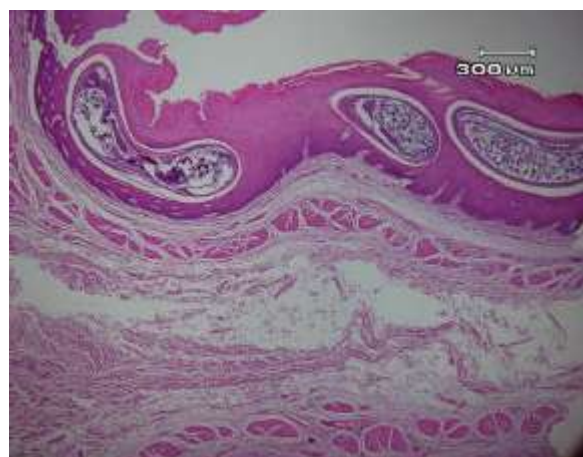


Fig. 2: Gongylonemiasis in sheep: massive parasite infection, as cross or coiled sections of adult helminthes lied in burrowed tunnels under the stratum corneum and marked acanthosis and hyperkeratosis are present (HandE, 40 ×).

DISCUSSION

It seems likely that Gongylonemiasis is a common parasitism of domestic and wild animals of Iran. The prevalence in sheep was similar to wild sheep (5.6%) [5], but less than sheep (21.5%) [4] and much less than that of cattle (45% and 49.7%) [2, 3] and wild boars [6] in Iran.

Various mathematical descriptions are available for over dispersed distribution, the negative binomial distribution being most commonly applied to host parasite system. The majority of host/parasite system that has been examined conforms to a negative binomial distribution including several species of nematodes [14]. Accordingly frequency distribution pattern of *G. pulchrum* in sheep esophagus in this survey similar to cattle of Iran [3] was highly aggregated consistent with a negative binomial distribution, indicating infestation of sheep was not random. The majority of esophagi harbored few [1-4], a few moderate [10-14] and one 100 worms.

Absence of seasonality may be due to persistence of worm in the esophagi or continuous reinfection, but taking into consideration the mean number of worm in the survey, the former hypothesis is more likely in harmony with our findings.

No pathogenicity can be attributed to gongylonemiasis in this study, a finding in contrast to hemorrhage occurred in cattle when infestation burden ranged from one to nine worms [9]. Development of an esophageal squamous cell carcinoma attributed in a 17-year-old, female vari (*Lemur macaco variegates*) [12] harboring *G. pulchrum* and two clinical sings including itching and scratching of the edematous and slightly hyperemic perioral tissues observed in common marmoset (*Callithrix jacchus*) [10] were attributed to gongylonemiasis.

Gongylonemiasis of man is rare, but to date, there have been nearly 50 cases in humans described worldwide, including Europe, china, the Middle East, Australia and New Zealand [9, 15, 16,17]. Nine cases have been described from the United States, where the last report was in 1963 [15]. It seems likely that the infection in man is associated with clinical symptoms. Creeping sensation in neck and upper digestive tract of a 27 year old woman in Iran [8] and sensations of movement with in the buccal mucosa of a 27 year old women [11] confirm this suggestion. Eberhard and Busillo [18] described a case of infection with *Gongylonema* in a 41-year-old woman living in New York City with a history more than 1-year duration of having the sensation of a moving organism in her mouth and a history of reflux-like symptoms but without eosinophilia and other laboratory parameters. Also, symptoms other than the sensation of something moving such as local irritation, pharyngitis and stomatitis and bloody oozing patches in the mouth were reported [16].

In this study chronic inflammatory reaction and prolonged mild to heavy parasitic infection caused marked epithelium hyperplasia of the stratum basale and stratum spinosum).

REFERENCES:

1. Soulsby, E. and J.L. Helminthes, 1982. Arthropods and Protozoa of Domesticated Animals. 7th ed. London, England. Bailliere Tindall, pp: 296-298.
2. Eslami, A.H. and F. Fakhrzadegan, 1972. Les nematodes parasites du tube digestif des bovine en Iran. Rev. Elev. Med. Vet. Pays Trop., 25(4): 527-529.
3. Anwar, M., H. Rak. and T.W. Gyorkos, 1979. The incidence of *Gongylonema pulchrum* from cattle in Tehran, Iran. Vet Parasitol., 5: 271-274.
4. Eslami, A. and L. Nabavi, 1976. Species of gastrointestinal nematodes of sheep from Iran. Bull Soc. Path. Exot., 69:92-95.
5. Eslami, A., M. Meydani, S.H. Maleki and A. Zargarzadeh, 1979. Gastrointestinal nematodes of wild sheep (*Ovis orientalis*) from Iran. J. Wildfe Dis., 15: 263-265.
6. Eslami, A. and S. Farsad-Hamdi, 1882. Helminth parasites of wild boars, *Sus scrofa* in Iran. J Wildfe Dis., 28(2): 316-318.
7. Movassahgi, A.R. and G.R. Razmi, 2008. Esophageal and gastric gongylonemiasis in a donkey. Iranian J. Vet. Res. Univ. Shiraz, 9(1): 84-86 and 104.
8. Molavi, G.H., J. Massoud and Y. Gutierrez, 2006. Human Gongylonema infection in Iran. J. Helminthol., 80(4): 425-428
9. Palmer, S.R., Lord Soulsby and D.I.H. Simpson, 1998. Zoonoses. Oxford Medical Publications, Oxford, UK.
10. Brack, M., 1996. Gongylonemiasis in the common marmoset (*Callithrix jacchus*). Lab. Anim. Sci., 46(3): 266-270.
11. Urch, T., B.C. Albrecht, D.W. Buttner and E. Tannich, 2005. Human infection with *Gongylonema pulchrum*. Dtsch Med. Wochenschr, 130(45): 2566-2568.
12. Bleier, T., U. Hetzel, C. Bauer, O. Behlert and E. Burkhardt, 2005. *Gongylonema pulchrum* infection and esophageal cell carcinoma in a vari (*Lemur macaco variegates*). J. Zool and Wildfe. M., 36(2): 342- 345.
13. Luna, L.G., 1968. Manual of Histologic Staining Method of the Armed Force Institute of Pathology, 3rd edition, New York USA Mc Graw-Hill Book Company, pp: 1-44.
14. Keymer, A., 1982. Density-dependent mechanisms in the regulation of intestinal helminth populations, Parasitol., 84: 573-587.
15. Eberhard, M. and C. Busillo, 1999. Human Gongylonema infection in a resident of New York City. Am. J. Trop. Med. Hyg., 61(1): 51-52.
16. Beaver, P.C., R.C. Jung and E.W. Cupp, 1984. Clinical Parasitology. 9th edition, Philadelphia, USA. Lea and Febiger, pp: 345-346.
17. Illescas-Gomez, M.P., 1988. Rodriguez M. Osorio, V. Gomez Garcia. and Gomes Morales M.A. Human Gongylonema infection in Spanish. Am. J. Trop. Med. Hyg., 38(2): 363-365.
18. Eberhard, M. and C. Busillo, 1999. Human Gongylonema infection in a resident of New York City. Am. J. Trop. Med. Hyg., 61(1): 51-52
18. Bailey, W.S., Parasites and Cancer, Sarcoma in dogs associated with *Spirocerca lupi*. Ann. N.Y. Acad. Sci., 108: 890-923.
19. Hou, P.C., 1964. Primary carcinoma of bile duct of the liver of cats infected with *Clonorchis sinensis*. J. Pathol. Bact., 87: 239-244.
20. Maxie, G., J. Kennedy and Palmer's, 2007. Pathology of Domestic Animals, 5th edition, Philadelphia, USA. Elsevier Saunders, 2: 40-42.
21. Cohen, S.M., D.T. Purtilo and L.B. Ellwein, 1991. Ideas in pathology: Pivotal role of increased cell proliferation in human carcinogenesis. Mod. Pathol., 4: 371-382.
22. Ohshima, H. and H. Bartsch, 1994. Chronic infection and inflammatory processes as cancer risk factors: possible role of nitric oxide in carcinogenesis. Mutat. Res., 305: 253-264.