Global Veterinaria 14 (2): 244-250, 2015
ISSN 1992-6197

DOI: 10.5829/idosi.gv.2015.14.02.9361

The Effectiveness of a Mixture of Honey, Beeswax and Olive Oil in Treatment of Canine Deep Second-Degree Burn

Alaa Moustafa and Ayman Atiba

Department of Surgery, Anesthesiology and Radiology, Faculty of Veterinary Medicine, Kafrelsheikh University, Kafrelsheikh, El Geish street, 33516, Egypt

Abstract: Burns is a global public health problem in the developed world and expensive burn dressings are not universally available. Most burns patients suffer from a deep second degree burn that can be treated conservatively. However, the ideal dressing for the burn wound has not been identified. This study is performed in animal experiment to compare the healing of deep second degree burns treated with silver sulfadiazine (SSD) and a Mixture of Honey, Beeswax and olive oil (MHBO). A standard deep second-degree burn wound was produced, in five dogs, each dog has three groups; MHBO, SSD 1% cream and control group (no topical therapy at all). The efficacy of treatment was assessed based on the healing percentage of the wound, time to complete wound healing and the degree of inflammation and exudation. Wound contraction was higher in MHBO group than both SSD and the control group. It was significantly higher in MHBO group than the control group on days 18, 21, 24 and 27 while significantly higher than the SSD group on days 21 and 24. The mean times for wound complete closure were 21.9±2.23 and 24.7±2.39 days for MHBO and SSD, respectively, being significantly shorter for MHBO. Clinically, inflammatory reaction and exudation were less in MHBO group than the SSD group and control group. Using topical MHBO will accelerate the burn wound healing process in comparison with both the control and SSD groups and can be used as an adjunctive or alternative agent in the future.

Key words: Beeswax · Burn · Dog · Honey · Olive Oil · Wound-Healing

INTRODUCTION

Burns are one of the most common injuries seen the world over [1, 2]. Burns not only impair the cutaneous tissue locally, but may also cause some systemic effects, such as loss of fluid and protein, sepsis, changes in the metabolic state and involvement of the hematological and immune systems [3]. Full-thickness burns involve both the outer layer (epidermis) and the underlying layer of the skin (dermis) [3, 4]. Burn management involves a prolonged period of hospitalization, expensive medication and surgical operations. Also, burns may cause patients to require long-term rehabilitation. However, some burns are not severe and can be handled outside the hospital setting in order to reduce both the burdens of cost and of hospitalization time [5]. Many of the synthetic drugs used to treat burns are not cost effective because of their high expense. Some effective methods, such as recombinant growth factors and tissue-engineered wound dressings, are highly expensive and beyond the reach of most patients in the developing world. Current burn treatments also present chances for unwanted adverse effects. Currently, the most commonly used local treatment for a burn is 1% silver sulfadiazine (SSD), which is useful to keep the burn wound free from bacterial contamination. However, studies revealed that the healing process of full thickness burn wounds is delayed by using SSD. Thus, researchers are looking for a better alternative burn dressing [6-8].

Previous studies show that using traditional herbal medicine is effective in healing wounds. Traditional herbal medicine is gaining popularity because of its widespread availability, no or fewer adverse effects, moderate efficacy and low cost as compared with synthetic drugs [9]. Honey is one of the oldest known medicines. It has been valued highly in the Middle East and was mentioned

Corresponding Author: Alaa Moustafa,Address, Department of Surgery, Anesthesiology and Radiology, Faculty of Veterinary Medicine, Kafrelsheikh University, Kafrelsheikh, 33516, Egypt.
E-mail: ametwally@rvc.ac.uk.

in the Holy Quran since 1436 years ago. It has been used for treatment of respiratory diseases, urinary diseases, gastrointestinal diseases and skin diseases including ulcers, wounds, eczema, psoriasis and dandruff [10]. Honey reduces inflammation, edema and exudation, promotes healing, diminishes the scar size and stimulates tissue regeneration [11-13]. The basis of using beeswax in the mixture was derived from the observation that beeswax has antibacterial properties [14].

One such potential burn dressing is olive oil, which was selected for several reasons: when destruction of the skin occurs, as happens with burns, one of the first reactions of the cells in the stratum corneum is to secrete fatty acids in order to restore the permeability barrier [15, 16]. On the other hand, they are more resistant to oxidative stress, which occurs in the burn area, than polyunsaturated fatty acids. Finally, fatty acids have antimicrobial properties [17], which can potentially reduce wound contamination. Olive oil also contains vitamin E [18] and phenol compounds such as hydroxytyrosol, tyrosol, oleuropein, 1- acetoxypinoresinol and (+)-pinoresinol, which are known to have powerful antioxidant potential [18-20]. Because free radicals play an important role in the pathophysiology of burns [21-27], both locally and systematically, using an antioxidant as a topical burn therapy may help in the recovery process.

Honey, beeswax and olive oil are natural materials that contain flavonoids, antioxidants, antibacterial ingredients and effects cytokines production by skin cells when applied topically [28, 29]. The aim of this study was to compare the healing of second degree burns treated with MHBO mixture or SSD.

MATERIALS AND METHODS

Chemicals and Drugs

Silver Sulfadiazine: 1% topical cream (El-Nasr Pharmaceutical Chemicals Co. Cairo, Egypt).

MHBO Mixture: MHBO mixture was prepared by thoroughly mixing of natural honey, olive oil and beeswax (v/v/v, 1:1:1). Natural unprocessed beeswax was obtained from Abo-Elkheir Farm, Zifta, Gharbeya Governorate, Egypt. The natural, pure mono floral clover honey was obtained from (IMTENAN Ethical nutrition, Cairo, Egypt) and it was supplied directly from the company without heating or irradiation and stored in dark containers at room temperature for use in the study. The honey was subjected to analysis of physical characters and chemical composition in Scientific Lab, Faculty of Veterinary Medicine, Kafrelsheikh University, Egypt. Honey was dark yellow in color and its composition included fructose 32%, glucose 21%, acidity 12%, moisture 17.9% and pH 3.7 and a carbohydrate content of 72.4 g/100 g. The olive oil used in the mixture was an extra virgin olive oil (Colavita, Pomezia, Rome, Italy).

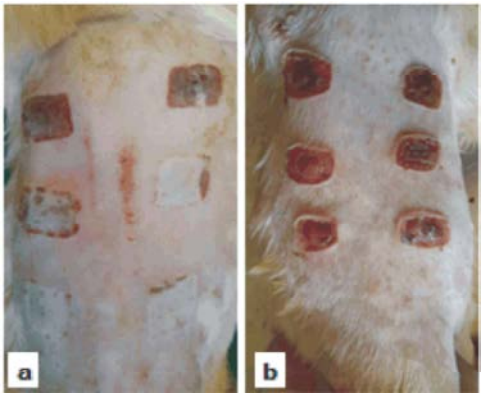

Fig. 1: The location of burn-wounds on the back of the dog.
Representative images of the burns on the day of starting the experiment (A) and 6 days post-burn after debridement of necrotic tissue had been performed (B).

Animals: Five healthy male mixed breed dogs, 13-15-month-old, weighing 10-14 kg were used for this experiment. The study protocol was reviewed and approved by the Animal Care Committee, Faculty of Veterinary Medicine, Kafrelsheikh University, in accordance with Egyptian ethical codes for studies on experimental animals.

Study Protocol: General anesthesia was performed with 0.2% ketamine HCl by intravenous drip method after premedication with xylazine (5 mg/kg). Each dog was then placed in the prone position and prepared for aseptic surgery. Equal sets of standardized deep, second-degree burn wound was created with a hot iron plate (diameter: 2×2cm) at an identical temperature (warmed 5 minutes within a water bath at 100°C and placed for 20 seconds on the animal back with an equal pressure) (Figure 1, A) [30]. The 30 burn skin wounds of the five dogs were randomly assigned in three groups (10 wounds each), Each dog had six burn skin wounds, 2 wounds in the MHBO group, 2 wounds in the SSD group (SSD cream) and 2 wounds in the control group (untreated group). After removal of necrotized tissues (Figure 1, B), all wounds were covered with a non-adherent occlusive bandage. The bandage was changed every 3 days and MHBO and SSD cream were reapplied every 3 days. Scabs that covered the wound

were gently removed, to allow the assessment of the wound.

The primary outcome criterion was the percentage wound healing. For assessment of wound healing, digital photography was taken every 3 days. The photographs are then assessed by software Image j and the percentage of healing was determined as follows: Percent of wound healing = [initial wound area – unhealed wound area / initial wound area] × 100.

The secondary outcome criterion was the time period between the infliction of the burns to complete wound closure and it was performed visually every 3 days. The clinical course of skin lesions by burns was evaluated for 27 consecutive days based on the following aspects: redness, swelling, crust, bleeding, secretion, granulation tissue. The intensity of clinical signs was scored (0-3) as 0: absent, 1: mild, 2: moderate, 3: strong.

Data Analysis: Data were collected, analyzed and reported as mean and standard deviation (Mean±S.D.). Statistical comparisons between groups were carried out by using SPSS software (Version 16.0, Chicago, IL, USA). One-way ANOVA followed by post-hoc Tukey's test were used to analyze the data. $P \leq 0.05$ was considered as statistically significant.

RESULTS

The wound size was stated as 100% on day 6 post-burn and wound size on other days calculated compared to the day 6 post-burn (Figure 1). After day 6 post-burn, wounds were initiated in both MHBO and SSD groups with a degree more than that of the control group.

Wound contraction was higher in the MHBO group than both SSD and the control group. MHBO group was significantly higher than the control group on days 18 ($P<0.05$), 21 ($P<0.01$) and 24 ($P<0.01$), 27 ($P<0.001$), while significantly higher than the SSD group on days 21 ($P<0.001$) and 24 ($P<0.001$) (Figure 2 and 3). The wound size percent at 6, 9, 12, 15, 18, 21, 24 and 27 days after burn injury are shown in Figure 3.

The mean times for wound complete closure were 22.9±2.56 and 25.7±2.31 days for MHOB and SSD, respectively, being significantly shorter for MHOB ($P<0.05$). Clinically, inflammatory reaction and exudation were less in MHOB group than SSD and the control group but not significantly. Also, there were no adverse outcomes (such as infection) noted in any of the groups.

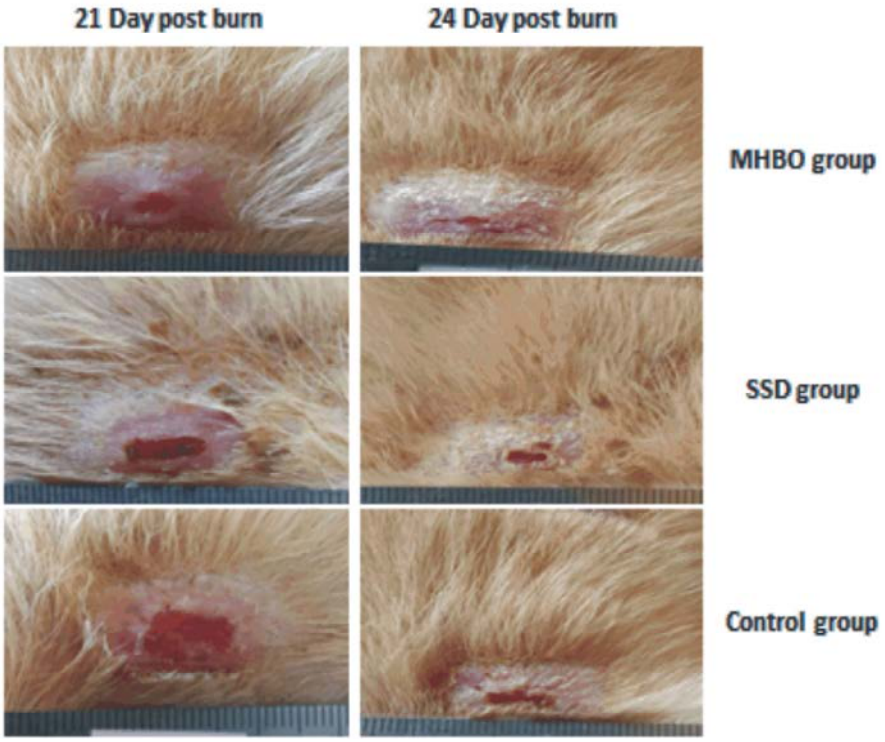

Fig. 2: Effects of Chemicals and Drugs on burns healing.
Visualization of burned wounds from MHBO, silver sulfadiazine and control groups on day 21 and 24 post-burn.

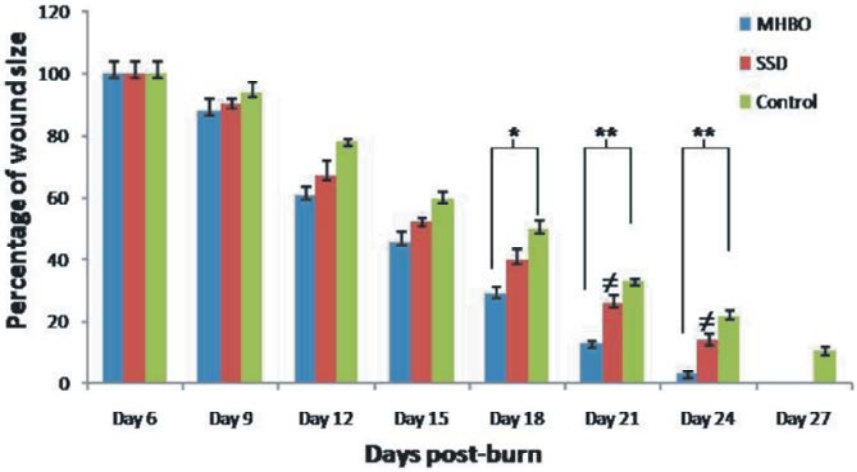

Fig. 3: The effect of MHBO, silver sulfadiazine on burns wound healing.
Comparison of wound burn sizes in the MHBO, (SSD) and control groups. The wound size was defined as 100% on day 6 post-burn and then calculated and compared with day 6 thereafter. $*p < 0.05$, $**p < 0.01$ and $\neq p < 0.001$ by One-way ANOVA followed by post-hoc Tukey's test. ($\neq$) represent the significant difference between MHBO group and the silver sulfadiazine group.

DISCUSSION

Burn is one of the most widespread injuries in the world. The pathophysiology and histopathology of thermal burns in animals is very similar to that in humans [30, 31]. SSD cream is the most widely used topical treatment for burn injury in animals [32-34]. The antimicrobial efficacy of SSD is probably the main reason for the use of this agent. Although SSD is considered a gold standard for treatment of burn injuries, prolonged application of this agent may result in a longer hospitalization [35, 36], indicating the need for a better burn dressing.

The use of natural products such as, honey, bees wax and olive oil to treat burns has great appeal, especially in underdeveloped countries, where more sophisticated and expensive therapies are not always available. A variety of natural products have been reported for the treatment of superficial burns, including Green tea (Camellia sinensis) [37], Aloe vera [30, 38], papaya extract [39], boiled potato peels [40], banana leaves [41], crude honey [42] and olive oil [1] with variable degrees of success. Because of their widespread availability, their hydrophobic nature and the presence of several substances with antioxidant activities, MHBO mixture possesses many characteristics that make it an appealing target for investigation into local burn wound therapy. Assessment of wound size was employed for evaluating efficacy of MHBO in the treatment of burn injuries in dogs. These results indicated that MHBO is able to accelerate the rate of wound healing and shortens the time of healing, compared with those treated with SSD in burned dogs. Moreover, the results of our studies involving clinical cases in dogs and horses (data were not shown) would indicate that the application of MHBO accelerated wound healing.

Honey reduces pain, edema, exudates and scar formation [43]. Honey seems to accelerate wound healing as measured by the thickness of granulation tissue, epithelialization from the periphery of the wound and the size of the open wound [44]. Pure honey inhibited fungal growth and diluted honey appears capable of inhibiting toxin production [45].

A natural mixture of high molecular weight alcohol (D-002) isolated and purified from beeswax, produces a significant reduction of exudate volume in carrageenan-induced pleuritic inflammation [46]. D-002 reduced leukotriene B4 and thromboxane B2 and diminished granuloma weight [47]. Olive oil is a source of at least 30 phenolic compounds such as hydroxytyrosol and oleuropein which have bactericidal activity [18]. Phenolic acid in olive oil has protective effect against cytotoxic effect of reactive oxygen species [48]. Olive oil contains a high percentage of monounsaturated fatty acids [49] and can potentially help restore the permeability barrier. In addition, monounsaturated fatty acids are an important component of cell membranes in the burn site, since they make the cell membranes more fluid [50] compared with

saturated fatty acids and in this way hasten cell metabolism. The present study showed a decrease of inflammation and exudation following MHBO treatment more than SSD and control but not significantly. The anti-inflammatory effects of MHBO can contribute to resolving the inflammatory process induced by burn injury [30].

The mechanism of action of honey has not been definitely known, though acidity, osmolality and hydrogen peroxide production have been proposed as an important factor [13]. Honey has been shown to increase nitric oxide in saliva taken from normal individuals [51]. In addition, it was found that various honeys contained different amount of nitric oxide metabolites and intravenous honey could increase urinary nitrite excretion in the animals [52]. Flavonoids, rich in olive oil and honey, have potent antioxidant, cytoprotective and anti-inflammatory activities and inhibited histamine, IL 6 and IL 8 [53]. Nitric oxide reduced incidence of skin infection in psoriasis [54]. Nitric oxide donors significantly reduced the number of CD14 and CD3 cells infiltrating the epidermis in psoriatic skin [55].

The mechanism of therapeutic effects of MHBO on burn lesions might be attributed to elevation of nitric oxide in the lesions, inhibition of fungal or bacterial growth, inhibition of leukotriene B4 and to its antioxidant and anti-inflammatory activities. One of the main limitations of this study is the histological examination to support our findings. Further studies were required to understand the mechanism underlining the effect of MHBO on wound healing after burn in dogs.

In conclusion, MHBO mixture promoted wound healing in second degree burn better than SSD cream. However, further work is needed to analyze each of the components in MHBO for their beneficial effects on wound healing.

REFERENCES

1. Gurfinkel, R., M. Palivatkel-Naim, R. Gleisinger, L. Rosenberg and A.J. Singer, 2012. Comparison of purified olive oil and silver sulfadiazine in the treatment of partial thickness porcine burns. Am. J. Emerg Med., 30(1): 79-83.
2. Upadhyay, N.K., R. Kumar, M.S. Siddiqui and A. Gupta, 2011. Mechanism of Wound-Healing Activity of Hippophae rhamnoides L. Leaf Extract in Experimental Burns. Evid Based Complement Alternat Med, pp: 659705.
3. Kumar, V., A.A. Aster and JC. Robbins, 2012. Basic Pathology. 9th ed. Philadelphia, PA. Elsevier Health Sciences.
4. Marx, J.A., H.R. Walls and R.M. Rosen's 2010. Emergency Medicine: Concepts and Clinical Practice. Vol 1. 7th ed. Philadelphia, PA: Mosby Incorporated.
5. Mashreky, S.R., A. Rahman, S.M. Chowdhury, S. Giashuddin, L. Svanstrom, T.F. Khan, R. Cox and F. Rahman, 2008. Burn injury: economic and social impact on a family. Public Health, 122(12): 1418-24.
6. Atiyeh, B.S. and C.M. Hayek SN., 2007. Effect of silver on burn wound infection control and healing: review of the literature. Burns, (33): 139-48.
7. Fuller, F.W., 2009. The side effects of silver sulfadiazine. J. Burn Care Res., 30(3): 464-70.
8. Mohajeri, D.M.M., Y. Doustar and M. Nazeri, 2011. Comparison of The Effect of Normal Saline and Silver Sulfadiazine on Healing of Skin Burn Wounds in Rats: A Histopathological Study. Middle-East Journal of Scientific Research, 10(1): 08-14.
9. Gray, D.C. and C.M. Rutledge, 2013. Herbal supplements in primary care: patient perceptions, motivations and effects on use. Holist Nurs Pract., 27(1): 6-12.
10. Zaghloul, A.A., H.H. el-Shattawy, A.A. Kassem, E.A. Ibrahim, I.K. Reddy and M.A. Khan, 2011. Honey, a prospective antibiotic: extraction, formulation and stability. Pharmazie, 56(8): 643-7.
11. Molan, P.C., 1999. The role of honey in the management of wounds. J. Wound Care, 8(8): 415-8.
12. Cooper, R.A. and P.C. Molan, 1999. Honey in wound care. J. Wound Care, 8(7): 340.
13. Al-Waili, N.S. and K.Y. Saloom, 1999. Effects of topical honey on post-operative wound infections due to gram positive and gram negative bacteria following caesarean sections and hysterectomies. Eur J. Med. Res., 4(3): 126-30.
14. Bogdanov, S., 2009. Beeswax: uses and trade. In: Bogdanov S, ed. The Beeswax Book. xx: Bee, Product Science; 2009: 11-12. Available at: www.bee-hexagon.net. Accessed xxx.
15. Mao-Qiang, M., P.M. Elias and K.R. Feingold, 1993. Fatty acids are required for epidermal permeability barrier function. J. Clin Invest, 92(2): 791-8.
16. Walters, KA.R.M., 2002. The structure and function of skin. In: Walters KA, Walter AW, editors. Dermatological and transdermal formulation. Marcel Dekker., pp: 1-40.
17. Kabara, J.J., D.M. Swieczkowski, A.J. Conley and J.P. Truant, 1972. Fatty acids and derivatives as antimicrobial agents. Antimicrob Agents Chemother, 2(1):. 23-8.

18. Owen, R.W., A. Giacosa, W.E. Hull, R. Haubner, B. Spiegelhalder and H. Bartsch, 2000. The antioxidant/anticancer potential of phenolic compounds isolated from olive oil. Eur J. Cancer, 36(10): 1235-47.
19. Visioli, F. and C. Galli, 1994. Oleuropein protects low density lipoprotein from oxidation. Life Sci., 55(24): 1965-71.
20. Visioli, F., G. Bellomo, G. Montedoro and C. Galli, 1995. Low density lipoprotein oxidation is inhibited *in vitro* by olive oil constituents. Atherosclerosis, 117(1): 25-32.
21. Arturson, G., 1996. Pathophysiology of the burn wound and pharmacological treatment. The Rudi Hermans Lecture, 1995. Burns, 22(4): 255-74.
22. Till, G.O., L.S. Guilds, M. Mahrougui, H.P. Friedl, O. Trentz and P.A. Ward, 1989. Role of xanthine oxidase in thermal injury of skin. Am J. Pathol., 135(1): 195-202.
23. Kaufman, T., R.A. Neuman and A. Weinberg, 1989. Is postburn dermal ischaemia enhanced by oxygen free radicals? Burns, 15(5): 291-4.
24. Hiramatsu, M., Y. Izawa, M. Hagihara, I. Nishigaki and K. Yagi, 1984. Serum lipid peroxide levels of patients suffering from thermal injury. Burns Incl Therm Inj., 11(2): 111-6.
25. Demling, R.H. and C. Lalonde, 1990. Systemic lipid peroxidation and inflammation induced by thermal injury persists into the post-resuscitation period. J. Trauma, 30(1): 69-74.
26. Saez, J.C., P.H. Ward, B. Gunther and E. Vivaldi, 1984. Superoxide radical involvement in the pathogenesis of burn shock. Circ Shock, 12(4): 229-39.
27. Hatherill, J.R., G.O. Till, L.H. Bruner and P.A. Ward, 1986. Thermal injury, intravascular hemolysis and toxic oxygen products. J. Clin Invest, 78(3): 629-36.
28. Zanoschi, C., C. Ciobanu, A. Verbuta and D. Frincu, 1991. The efficiency of some natural drugs in the treatment of burns. Rev Med Chir Soc Med Nat Iasi., 95(1-2): 63-5.
29. Tuck, K.L. and P.J. Hayball, 2002. Major phenolic compounds in olive oil: metabolism and health effects. J. Nutr Biochem, 13(11): 636-644.
30. Atiba, A., M. Marzok and A. Ghazy, 2014. Comparison of Aloe Vera and Silver Sulfadiazine in the treatment of Deep Second-Degree Burn in Dogs. Global Veterinaria, 13(5): 733-737.
31. Geiser, D.R. and R.D. Walker, 1984. Management of thermal injuries in large animals. Vet Clin North Am Large Anim Pract, 6(1): 91-105.
32. Pavletic, M.M. and N.J. Trout, 2006. Bullet, bite and burn wounds in dogs and cats. Vet Clin North Am Small Anim Pract, 36(4): 873-93.
33. Hanson, R.R., 2005. Management of burn injuries in the horse. Vet Clin North Am Equine Pract, 21(1): 105-23.
34. Karimi, M., P. Parsaei, S.Y. Asadi, S. Ezzati, R.K. Boroujeni, A. Zamiri and M.R. Kopaei, 2013. Effectsof Camellia sinensis Ethanolic Extract on Histometric and Histopathological Healing Process of Burn Wound in Rat. Middle-East Journal of Scientific Research, 13(1): 14-19.
35. Stern, H.S., 1989. Silver sulphadiazine and the healing of partial thickness burns: a prospective clinical trial. Br J. Plast Surg, 42(5): 581-5.
36. Cho Lee, A.R., H. Leem, J. Lee and K.C. Park, 2005. Reversal of silver sulfadiazine-impaired wound healing by epidermal growth factor. Biomaterials, 26(22): 4670-6.
37. Mehrdad, K., P. Pouya, Y. Sayyed, E. Sareh, K.B. Reza, Z. Alaleh and R. Mahmoud, 2013. Effectsof Camellia sinensis Ethanolic Extract on Histometric and Histopathological Healing Process of Burn Wound in Rat. Middle-East Journal of Scientific Research, 13(1): 14-19.3.
38. Visuthikosol, V., B. Chowchuen, Y. Sukwanarat, S. Sriurairatana and V. Boonpucknavig, 1995. Effect of aloe vera gel to healing of burn wound a clinical and histologic study. J Med Assoc Thai, 78(8): 403-9.
39. Starley, I.F., P. Mohammed, G. Schneider and S.W. Bickler, 1999. The treatment of paediatric burns using topical papaya. Burns, 25(7): 636-9.
40. Subrahmanyam, M., 1996. Honey dressing versus boiled potato peel in the treatment of burns: a prospective randomized study. Burns, 22(6): 491-3.
41. Gore, M.A. and D. Akolekar, 2003. Evaluation of banana leaf dressing for partial thickness burn wounds. Burns, 29(5): 487-92.
42. Subrahmanyam, M., 1998. A prospective randomised clinical and histological study of superficial burn wound healing with honey and silver sulfadiazine. Burns, 24(2): 157-61.
43. Molan, P.C., 2002. Re-introducing honey in the management of wounds and ulcers - theory and practice. Ostomy Wound Manage, 48(11): 28-40.
44. Bergman, A.Y., J. Weiss, D. Bell and M.P. David,1983. Acceleration of wound healing by topical application of honey. An animal model. Am. J. Surg., 145(3): 374-6.

45. Wellford, T.E., T. Eadie and G.C. Llewellyn, 1978. Evaluating the inhibitory action of honey on fungal growth, sporulation and aflatoxin production. Z Lebensm Unters Forsch, 166(5): 280-3.
46. Carbajal, D., V. Molina, S. Valdes, L. Arruzazabala and R. Mas, 1995. Anti-ulcer activity of higher primary alcohols of beeswax. J. Pharm Pharmacol, 47(9): 731-3.
47. Noa, M. and R. Mas, 1998. Effect of D-002 on the pre-ulcerative phase of carrageenan-induced colonic ulceration in the guinea-pig. J. Pharm Pharmacol., 50(5): 549-53.
48. Manna, C., S. D'Angelo, V. Migliardi, E. Loffredi, O. Mazzoni, P. Morrica, P. Galletti and V. Zappia, 2002. Protective effect of the phenolic fraction from virgin olive oils against oxidative stress in human cells. J. Agric. Food Chem, 50(22): 6521-6.
49. Lide, D.R., 1991. CRC handbook of chemistry and physics. 72nd ed. Boston (Mass): CRC Press. 1991-1992.
50. Lodish, H.B.A., S.L. Zipursky, P. Matsudaira, D. Baltimore and J. Darnell, 1999. Molecular cell biology. In: Freeman WH, editor. Biomembranes and the subcellular organization of eukaryotic cells. 4th ed. pp: 138-206.
51. Al-Waili, N.S., 2003. Effects of daily consumption of honey solution on hematological indices and blood levels of minerals and enzymes in normal individuals. J. Med. Food, 6(2): 135-40.
52. Al-Waili, N.S., 2003. Identification of nitric oxide metabolites in various honeys: effects of intravenous honey on plasma and urinary nitric oxide metabolites concentrations. J. Med. Food, 6(4): 359-64.
53. Theoharides, T.C., M. Alexandrakis, D. Kempuraj and M. Lytinas, 2001. Anti-inflammatory actions of flavonoids and structural requirements for new design. Int J Immunopathol Pharmacol, 14(3): 119-127.
54. Weller, R., 1997. Nitric oxide--a newly discovered chemical transmitter in human skin. Br J. Dermatol., 137(5): 665-72.
55. Giustizier, M.A.C. and C. Scarponi, 2002. Nitric oxide donors chemokine production by keratinocytes *in vitro* and *in vivo*. Am. J. Pathol., 161: 1409-1418.