

Effect of Ozone-Treated Aflatoxin Contaminated Diets on DNA Damage, Expression of Androgen and Androgen Receptor Genes and Histopathological Changes in Japanese Quail

¹Mariam G. Eshak, ²Mohamed M. Deabas, ³Abdel Razik H. Farrag,
¹Ibrahim M. Farag and ⁴Farid K. R. Stino

¹Department of Cell Biology, National Research Center, Dokki, Cairo, Egypt

²Food Toxicology and Contaminants Department, National Research Center, Dokki, Cairo, Egypt

³Department of Pathology, National Research Center, Dokki Cairo, Egypt

⁴Department of Animal Production, Faculty of Agriculture, Cairo University, Egypt

Abstract: The present study was designed to investigate the effect of the ozone treatment on the toxicity problems induced by contaminated feed with aflatoxin B₁ (AFB₁). The genetic and histopathological changes in Japanese quail were studied. Sixty, three-week old male quail were randomly distributed into 6 experimental groups (10 birds per group). These birds were fed the following diets for three weeks; 1) basal diet (control); 2) basal diet treated with ozone for 5 minutes, short duration, (SD diet); 3) basal diet treated for 15 minutes, long duration, (LD diet); 4) basal diet contaminated with aflatoxin AFB₁, 1mg/kg diet (AF diet); 5) AF diet treated for a short duration with ozone (AFSD diet); 6) AF diet treated for a long duration with ozone (AFLD diet). The concentration of ozone in all treatments was 40 ppm for the short and long durations. The treated samples were analyzed for aflatoxin B₁ by immune-affinity column (IAC) clean-up and evaluated by high liquid chromatography (HPLC). Compared to the control group the results showed that quail fed the diet contaminated with aflatoxin (AF diet) had significantly higher DNA damage (micronucleated polychromatic erythrocytes formation and DNA fragmentation) and significantly lower expression patterns of androgen gene (AN) and its receptor (ANR). Histopathological examination revealed severe lesions of liver and testis tissues as compared to the control group. Moreover, the reduction in expression of AN and ANR was accompanied by reduction in testes weight. Feeding the quail AFSD or AFLD diets resulted in a lower DNA damage and enhancement in the expression patterns of AN and ANR genes. Less prominent histopathological changes and remarkable amelioration in liver and testis tissues, compared to quail fed diet contaminated with aflatoxin alone were also observed. The enhancement in the expression levels of AN and ANR genes, due to ozone treatments, was accompanied by improvement in testes weight. The quail fed diets treated with ozone for five minutes showed significantly more genetic and histopathological improvement as well as testes weight as compared to quail fed contaminated diets treated with ozone for 15 minutes. Furthermore, the quail fed basal diets (without aflatoxin B₁ contamination) treated for 5 minutes with ozone had more improvements in its genetic and histopathological parameters as well as testes weights than the control group. It can be concluded that ozone treatment as an oxidizing agent for five minutes was a best duration for aflatoxin disinfection. It could be useful in food industry for the detoxification of toxic chemicals and destruction of dangerous micro-organisms.

Key words: Ozone • Aflatoxin • HPLC • DNA Damage androgen Gene • RT-PCR And Histopathology

INTRODUCTION

The contamination of animal feed with aflatoxin represents a worldwide problem for farmers. These toxins are produced on living and stored plants particularly

under moist conditions by several fungi, mainly species of *Aspergillus* (*A. flavus*, *A. parasiticus* and *A. nomius*) and various species of *Penicillium*, *Rhizopus*, *Mucor* and *Streptomyces* [1, 2]. *Aspergillus flavus* and *A. parasiticus* are common in most soils and are usually involved in

decay of plant materials [2]. Aflatoxins can induce serious diseases in farm animals resulting in suffering and even death and thus can cause substantial economic losses.

To avoid mycotoxicosis, several strategies have been investigated. The applied procedures for protecting animals against mycotoxicosis, are chemical, physical and biological methods [1].

Mycotoxins can be eliminated with calcium hydroxide monoethylamine [3], ozone [4, 5] or ammonia [6]. Ozone, or triatomic oxygen (O₃), is a powerful disinfectant and oxidizing agent [4]. It has been considered as a GRAS (generally recognized as safe) substance and used in a number of applications in the food industry for destruction or detoxification of chemicals or micro-organisms [7-10]. Ozone gas also could effectively degrade mycotoxins such as aflatoxins, cyclopiazonic acid (CPA), fumonisin B1, ochratoxin A (OTA), patulin, secalonin acid D (SAD) and zearalenone (ZEN) [4, 11].

Traditionally, ozone gas generated by an ozone generator is directly into the spiked or contaminated grains. But in practice, it was found that its efficacy of mycotoxin degradation for mycotoxin-spiked grain sample was not always satisfactory. Sometimes the higher doses of ozone as well as longer treatment duration are needed to achieve a good result [12, 13]. McKenzie *et al.* [4] investigated the degradation and detoxification of common mycotoxins in the presence of high concentrations of O₃. Their results indicated that AFB₁ and AFG₁ were rapidly degraded using 2 weight % O₃ (approximately, 24.2 mg/liter air), while AFB₂ and AFG₂ were more resistant to oxidation and required higher levels of 20 weight % O₃, (approximately, 242.0 mg/liter air) over period of 5.0 minutes for rapid degradation. Prudente and King [14] used 10 to 12 weight % O₃ (approximately, 145.2 mg /liter air) for degradation of aflatoxins in maize. Also, Wang *et al.* [11] used 4.8mg/L of ozone concentration and 12 h of exposure time at room temperature for reduction aflatoxin B₁ of stored grains.

Because of the adverse effects of the using the treated diets with ozone on human and animal health, practical and effective detoxifications strategies are highly desirable [4]. However, the utilization of sterilized diets with ozone for animal feeding and performing the biological examinations on such animals to verify the protecting against the harmful effects of decontaminated feed, are still very limited or are not yet used in practice. So, the present study was designed to evaluate the genetic alterations and histopathological changes on quail fed diets contaminated with aflatoxin (AFB₁) and treated with ozone. The genetic study in quail included,

micronucleus test, DNA fragmentation and gene expression of Androgen gene and its receptor. The histopathological examination was performed on liver and testis tissues.

MATERIALS AND METHODS

Fungal Strain: Toxigenic strain of *Aspergillus flavus* (ATCC 28542) was obtained from Microbial Research Center, Faculty of Agriculture, Ain Shams University, Cairo, Egypt (MIRCEN).

Potato Dextrose Agar (PDA) and Yeast Extract Sucrose: Potato dextrose agar (PDA) and yeast extract sucrose were obtained from Sigma-Aldrich, France.

Preparation of Aflatoxin B₁: A standard strain of *Aspergillus flavus* (ATCC-28542) was used for production of aflatoxin. This fungus was cultured on medium of potato dextrose agar (PDA) and yeast extract sucrose according to the method of Shotwell *et al.* [15]. One hundred and fifty grams of ground quail diet was poured in a one-liter flask and mixed with 150 ml of distilled water. A number of such flasks were autoclaved for 15 minutes at a pressure of 15 pounds per square inch and then cooled. Fungal spores were inoculated at 10% (v/w) into each flask. The flasks were placed for 5 days at 28°C in an incubator. Contaminated diets containing fungal spores (the content of two flasks) were mixed with 30 kg of wet diets and maintained for 7 days at room temperature. After this period the infected diets were dried and aflatoxin was extracted and measured [15].

Ozone Gas Production: Ozone gas was produced from air using ozone generator Model OZO 6 VTTL (OZO MAX LTD, shefford, Quebec, Canda) from purified extra dry oxygen fed gas. The amount of output from ozone was controlled by a monitor-controller having a plug-in sensor on a board which is changed for different ranges of ozone concentration and a belt pan in the monitor-controller that allows controlling the concentration in a selected range.

Ozone Gas Treatment: The contaminated diets with AFB₁ at a level of 1 mg/Kg and also normal diets were transferred separately into a 500 ml flask. Each flask was plugged with a silicone stopper with 2 holes in it. One hole was for the ozone line and the other was for tubing connected to the ozone destruct unit. The contaminated and normal diets were treated with 40 ppm of ozone concentration for two durations, 5 and 15 minutes.

Extraction of AFB₁

Sample Extraction: Fifty grams of finally ground quail diet samples (control with and without AFB₁ and ozone treatments) with 10 g of sodium chloride were placed in a blender jar. Two hundred ml methanol:water (80:20) were added. After covering the jar, blending was carried out at high speed for 1 min. The extract was poured into fluted filter paper and the filtrate was collected in a clean vessel.

Extract Dilution: Ten ml filtered extract were pipetted into a clean vessel. The extract was diluted with 40 mL of purified water and mixed well. The diluted extract was filtered through glass microfiber filter into a glass syringe barrel using markings on barrel to measure 4 ml.

Immune Affinity Chromatography: Filtered diluted extract (4 mL=0.2g sample equivalent) were passed completely through AflaTest ®-P affinity column at a rate of about 1-2 drops/second until air comes through the column. Five mL of purified water were passed through the column at a rate of about 2 drops/second. Affinity column was eluted by passing 1.0 ml HPLC grade methanol through the column at a rate of 1-2 drops/second and all eluted sample (1ml) was collected in a glass vial. Samples were evaporated under a stream of nitrogen and were evaluated by HPLC [16, 17].

Determination of aflatoxin B₁ by HPLC

Apparatus: The HPLC system consisted of Waters Binary Pump Model 1525, a Model Waters 1500 Rheodyne manual injector, a Waters 2475 Multi-Wavelength Fluorescence Detector and a data workstation with software Breeze 2. A phenomenex C18 (250 x 4.6 mm i.d.), 5 µm from Waters corporation (USA). An isocratic system with water: methanol: acetonitrile 240:120:40 was used [18]. The separation was performed at ambient temperature at a flow rate of 1.0 mL/min. The injection volume was 20 µL for both standard solutions and sample extracts. The fluorescence detector was operated at wavelength of 360 nm for excitation and 440 nm for emission. AFB₁ concentration in samples was determined from the standard curve, using peak area for quantitation.

Derivatization: The derivatives of samples and standard were done as follows: 100 µl of trifluoroacetic acid (TFA) was added to samples and mixed well for 30 sec and the mixture was left to stand for 15 min. Nine hundred µl of water: acetonitrile (9:1 v/v) were then added and mixed well by vortex for 30 sec and the mixture was used for HPLC analysis.

Birds: Sixty unvaccinated 21 days old male Japanese quail chicks were obtained from the quail project, Faculty of Agriculture, Cairo University. The quail were divided into six groups. Each group of 10 quail were weighted and placed in a heated wooden brooder (battery cage). The birds received 24 h of light per day for the duration of the experiment. The birds also received *ad libitum*, water and a commercial growing quail ration (basal diet) containing 24% protein and 2,900 Kcal ME/Kg diet. The diet also contained all the required amino acids, vitamins and minerals according to the recommendations of the National Research Council [19]. No antibiotics, coccidiostats or growth promoters were added to the diet. All animals received human care in compliance with the guidelines of the Animal Care and Use Committee of Faculty of Agriculture, Cairo University, Egypt.

Experimental Design: In this study, six diets were used for six groups of quail as follows; 1) Control, basal diet; 2) basal diet contaminated with aflatoxin AFB₁ at a level of 1mg/Kg diet (AF group); 3) basal diet treated with 40 ppm of ozone concentration for 5 minutes, short duration treatment, (SD group); 4) basal diet treated with 40 ppm of ozone concentration for 15 minutes, long duration treatment (LD group); 5) basal diet contaminated with aflatoxin and treated with 40 ppm of ozone concentration for 5 minutes (AFSD group) and 6) basal diet contaminated with aflatoxin and treated with 40 ppm of ozone concentration for 15 minutes (AFLD group). The birds of all groups were fed the corresponding previously mentioned diets for 3 weeks. After that all birds were euthanized and liver, kidney and testes were collected. Testes were weighed and used to evaluate the expression patterns of Androgen gene (AN) and its receptor (ANR) using real time quantitative PCR. The percentage of micronucleated polychromatic erythrocytes (%MnPCEs) was evaluated using micronucleus test. Whereas, the rate of DNA fragmentation was determined in kidney tissues.

Moreover, specimens of liver and testes were dissected for all animals immediately after killing for the histopathological examinations.

DNA Damage

Micronucleus Test: The hepatic cells resuspended in a small volume of fetal calf serum on a glass slide were used for smear preparation. The smear of hepatic cells was prepared from each quail. After air-drying, the slide was fixed in methyl alcohol for 10 min and stained with 5% Giemsa stain for 10 min. Three slides were prepared for each animal and were coded before observation and one

was selected for scoring. From each coded slide, 2,000 polychromatic erythrocytes (PCEs) were scored for the presence of micronuclei under oil immersion at high power magnification. In addition, the percentage of micronucleated polychromatic erythrocytes (%MnPCEs) was calculated on the basis of the ratio of MnPCEs to PCEs [20].

DNA Fragmentation Analysis: Kidney samples were collected immediately after sacrificing the animals. The tissues were lysed in 0.5 ml of lysis buffer containing, 10 mM tris-HCl (pH 8), 1 mM EDTA, 0.2% triton X-100, centrifuged at 10,000 r.p.m. (Eppendorf) for 20 min at 4°C. The pellets were resuspended in 0.5 ml of lysis buffer. Half ml of 25% trichloroacetic acid (TCA) was added to the pellets (P) and the supernatants (S) and incubated at 4°C for 24 h. The samples were centrifuged for 20 min at 10,000 r.p.m. (Eppendorf) at 4°C and the pellets were suspended in 80 ml of 5% TCA, followed by incubation at 83°C for 20 min. Subsequently, to each sample 160 ml of DPA solution [150 mg DPA in 10 ml glacial acetic acid, 150 ml of sulfuric acid and 50 ml acetaldehyde (16 mg/ml)] was added and incubated at room temperature for 24 h [21]. The proportion of fragmented DNA was calculated from absorbance reading at 600 nm using the formula:

$$\% \text{Fragmented DNA} = [\text{OD(S)} / \text{OD(S)} + \text{OD(P)}] \times 100$$

Gene Expression Analysis

Extraction of total RNA: Testis tissues of quail of all groups were used individually to extract total RNA using TRIzol® Reagent (cat#15596-026, Invitrogen, Germany). Total RNA of each tissue was treated individually with 1 U of RQ1 RNase-free DNase (Invitrogen, Germany) to digest DNA residues, re-suspended in DEPC-treated water and photospectrometrically quantified at A260. Purity of total RNA was assessed by the 260/280 nm ratio (between 1.8 and 2.1). Additionally, integrity was assured with ethidium bromide-stain analysis of 28S and 18S bands by formaldehyde-containing agarose gel electrophoresis. Aliquots were used immediately for reverse transcription (RT), otherwise stored at -80°C.

Synthesis of the cDNA Using Reverse Transcription (RT) Reaction: The complete Poly(A)⁺ RNA isolated from quail tissues was reverse transcribed into cDNA in a total volume of 20 µl using RevertAid™ First Strand cDNA Synthesis Kit (MBI Fermentas, Germany). An amount of total RNA (5µg) was used with a reaction mixture, termed as master mix (MM). The MM was consisted of 50 mM MgCl₂, 5x reverse transcription (RT) buffer (50 mM KCl; 10

mM Tris-HCl; pH 8.3), 10 mM of each dNTP, 50 µM oligo-dT primer, 20 U ribonuclease inhibitor (50 kDa recombinant enzyme to inhibit RNase activity) and 50 U M-MuLV reverse transcriptase. The mixture of each sample was centrifuged for 30 sec at 1000 g and transferred to the thermocycler (Biometra GmbH, Göttingen, Germany). The RT reaction was carried out at 25°C for 10 min, followed by 1 h at 42°C and finished with a denaturation step at 99°C for 5 min [22]. Afterwards the reaction tubes containing RT preparations were flash-cooled in an ice chamber until being used for DNA amplification through sqRT-PCR.

Semi Quantitative Real Time-polymerase Chain Reaction (SQRT-PCR):

PCR reactions were set up in 25 µL reaction mixtures containing 12.5 µL 1× SYBR® Premix Ex Taq™ (TaKaRa, Biotech. Co. Ltd.), 0.5 µL 0.2 µM sense primer, 0.5 µL 0.2 µM antisense primer, 6.5 µL distilled water and 5 µL of cDNA template. The reaction program was allocated to 3 steps. First step was at 95.0°C for 3 min. Second step consisted of 40 cycles in which each cycle divided to 3 steps: (a) at 95.0°C for 15 sec; (b) at 55.0°C for 30 sec; and (c) at 72.0°C for 30 sec. The third step consisted of 71 cycles which started at 60.0°C and then increased about 0.5°C every 10 sec up to 95.0°C. At the end of each sqRT-PCR a melting curve analysis was performed at 95.0°C to check the quality of the used primers. Each experiment included a distilled water control.

The quantitative values of RT-PCR of androgen receptor (ANR) (AR-F: 5'-CTGCGG AAG TGC TAC GAG GC-3', AR-R: 5'-CGA AGT TCA TCA AAG AGC TTC TG-3', [22]; and androgen (AN) (T-F: 5'-GCC GGG GAT ATG AGT GAA T-3', T-R: 5'-CCT GGC TCG ATT TGT AAT CC-3', (GenBank: FG547171.1) genes were normalized on the bases of β-actin (β-actin-F: 5'-TGT GAT GGT GGG AAT GGG TCA G-3', B-actin-R: 5'-TTT GAT GTCACG CAC GAT TTC C-3', [23] expression.

Calculation of Gene Expression: First the amplification efficiency (Ef) was calculated from the slope of the standard curve using the following formulae [24]:

$$E_f = 10^{-1/\text{slope}}$$
$$\text{Efficiency (\%)} = (E_f - 1) \times 100$$

The relative quantification of the target to the reference was determined by using the ΔC_T method if E for the target (GH, IGF-1) and the reference primers (β-Actin) are the same [24]

$$\text{Ratio}_{(\text{reference}/\text{target gene})} = E_f^{C_T(\text{reference})} - \frac{C_T(\text{target})}{E_f}$$

Histopathological Examination: Specimens of liver and testes, were dissected from all animals immediately after killing, washed thoroughly with formal saline and then fixed in 10% neutral-buffered normal saline for 72 hours at least. All the specimens were washed in tap water for half an hour, dehydrated in ascending grades of alcohol (70-90-95% absolute), cleared in xylene and then embedded in paraffin wax. Serial sections of 6 µm thick were cut and stained with Haematoxylin and eosin [25] for histopathological investigation. Images were captured and processed using Adobe Photoshop version 8.0.

Statistical Analysis: All data of MnPCEs, DNA fragmentation and gene expression were analyzed as a one-way analysis of variance using the General Linear Model, SAS software [26]. Weight data were reported as least square means (LSM) ± standard errors (SEM). Gene expression data are expressed as means ± SEM. Mean values were separated, when significance is present, using Duncan's Multiple Range Test [27]. Significance level was set at 5%.

RESULTS

Data presented in Figure 1a and 1b showed that the percentage of reduction of AFB₁ in artificially contaminated feed was 72.3 and 86.7% after ozonation at 40 ppm for 5 and 15 min respectively, compared with the control. It is apparent that the percentage of inhibition increases with increasing the time of exposure and the dose of ozone used.

DNA Damage

Micronucleus Test: The results (Table 1 and Fig. 2) showed that feeding on contaminated diet with aflatoxin induced significantly more micronuclei (MnPCEs) in male quail (AF group) as compared to the control group. The frequencies of (MnPCEs) in quail fed normal diet treated with short duration of ozone (SD group) were similar with those found in the control, while the group of quail fed diet treated with long duration of ozone (LD group) of ozone had slight increase of micronuclei as compared to control group. Statistical analysis showed that there were no significant differences between control and (SD or LD) group or between SD and LD groups. On the other hand, the frequencies of micronuclei in quail fed contaminated diet with aflatoxin and treated with short (AFSD) or long (AFLD) duration of ozone were slightly lower than those found in quail fed contaminated diet with aflatoxin B₁

Table 1: Effect of ozone-treated diets on the incidence of micronucleated polychromatic erythrocytes (MnPCEs) in male Japanese quail.

Treatment	Incidence of MnPCEs in liver tissues
Control	7.30 ± 0.1 ^b
Ozone (SD)	7.10 ± 0.2 ^b
Ozone (LD)	8.20 ± 0.2 ^b
AF	18.60 ± 0.3 ^a
AF+ Ozone (SD)	13.70 ± 0.3 ^{ab}
AF+ Ozone (LD)	14.80 ± 0.3 ^{ab}

a-b LS Means followed by different superscripts, differ significantly (p ≤ 0.05).

Table 2: Effect of ozone-treated diets on the rate of DNA fragmentation in the kidney tissue of male Japanese quail.

Treatment	% DNA fragmentation in kidney tissues
Control	10.10±0.1 ^b
Ozone (SD)	9.80±0.1 ^b
Ozone (LD)	11.40±0.1 ^b
AF	24.70±0.4 ^a
AF + ozone (SD)	18.20±0.2 ^{ab}
AF+ ozone (LD)	19.80±0.2 ^{ab}

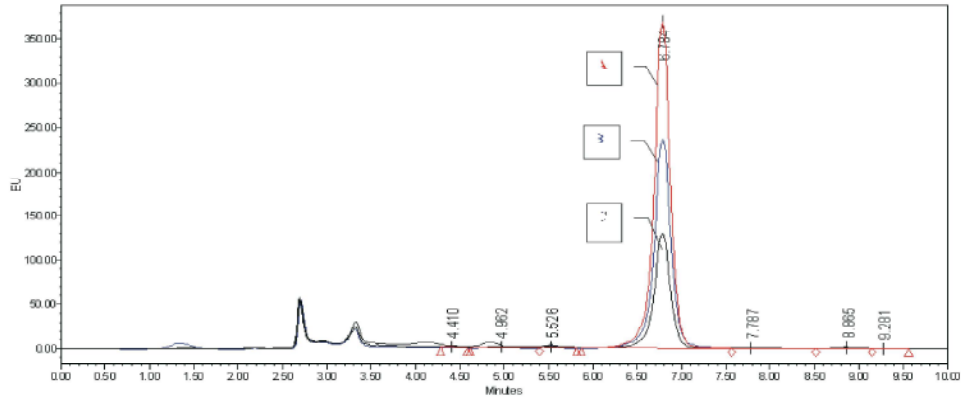
a-b LS Means followed by different superscripts, differ significantly (P ≤ 0.05).

alone (AF group). However, there were no significant differences between the AF, AFSD and AFLD groups and any of the other groups.

DNA Fragmentation: The results presented in Table 2 and Fig. 3 indicated that the rate of incidence of DNA fragmentation was significantly (p ≤ 0.05) higher in quail fed diet contaminated with aflatoxin (AF group) as compared to those of the control group. The rates of DNA fragmentation were slightly (but not significantly) lower in quail fed basal diet treated with short duration of ozone (SD group) in comparison to those of the control group. Whereas, the rates of DNA fragmentation slightly increased in quail fed basal diet treated with long duration of ozone (LD group) as compared to those of the control group. No significant differences in the frequencies of DNA fragmentation were observed between the quail fed diet contaminated with aflatoxin and treated with short (AFSD group) or treated with long (AFLD group) duration of ozone and any of the other groups.

Gene Expression and Testes Weight

Gene Expression Analysis: The present results (Fig. 4 and Fig. 5) revealed a significant decrease or down regulation of gene expression levels of each androgen gene (AN) and its receptor (ANR) in quail fed diets contaminated with aflatoxin (AF groups) as compared to those found in the controls. The expression levels of AN and ANR genes in quail fed diets treated with short (SD group) or long (LD group) duration of ozone were similar (especially in LO group) with that in the control



(A = Aflatoxin B₁ positive control, B=AFB₁+ Ozone (SD) C= AFB₁+ Ozone (LD); EU=Emission unit
 Fig1a : HPLC chromatogram of AFB1 in artificially contaminated diet with *A. flavus* strain after ozonation at 40 ppm with different exposure time 5, 15 min and positive control.

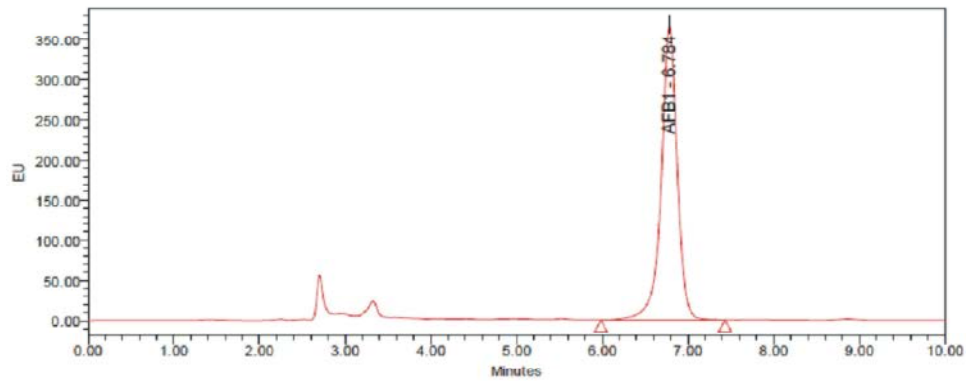


Fig1b: HPLC chromatogram of aflatoxin B₁ (AFB₁) standard.

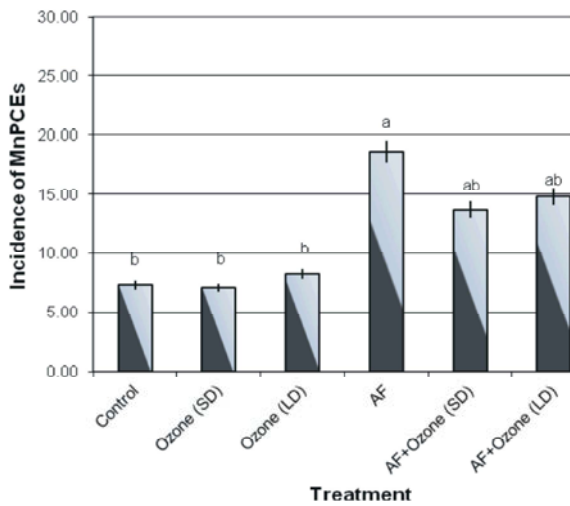


Fig. 2: Micronucleated polychromatic erythrocytes (MnPCEs) of male quail fed diets treated with a-b LS Means followed by different superscripts, differ significantly ($p \leq 0.05$).

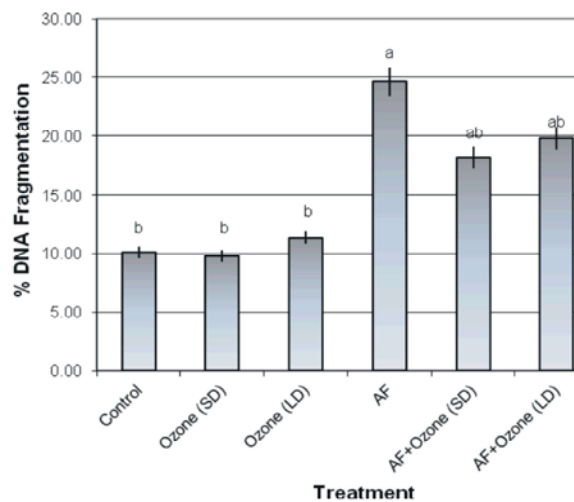


Fig. 3: DNA fragmentation in kidney tissues of male quail fed diets treated with Ozone. a-b LS Means followed by different superscripts, differ significantly ($P \leq 0.05$).

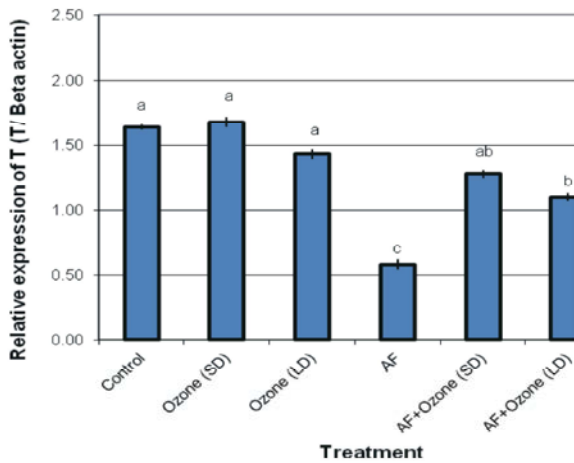


Fig. 4: Semi-quantitative Real Time-PCR analysis of androgen -mRNAs in testis tissues collected from male quail fed diets treated with ozone. a-b LS Means followed by different superscripts, differ significantly ($P \leq 0.05$).

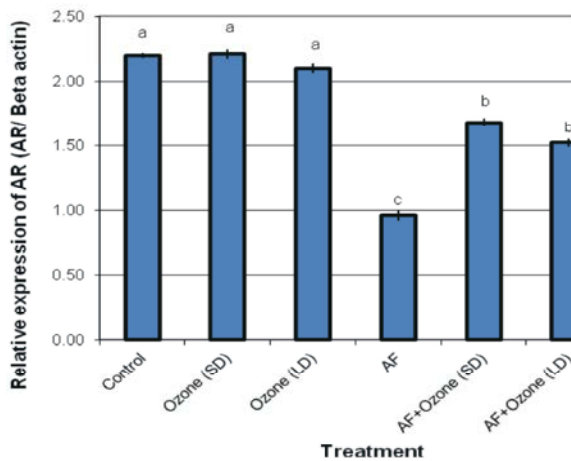


Fig. 5: Semi-quantitative Real Time-PCR analysis of androgen receptor-mRNAs in testis tissues collected from male quail fed diets treated with ozone. a-b LS Means followed by different superscripts, differ significantly ($P \leq 0.05$).

Table 3: Effect of ozone-treated diets on quail testes weight (Mean± SE) at 6 weeks of age.

Treatments	Testes weight at 6 weeks of age (gm)
Control	5.7±0.64
Ozone (SD)	7.2±1.00
Ozone (LD)	6.7±0.45
AF	5.5±0.67
AF+ ozone (SD)	6.0±1.1
AF+ ozone (LD)	5.9±0.65

a-b LS Means followed by different superscripts, differ significantly ($P \leq 0.05$).

and there were no significant differences between SD and C group, or between LD and C groups or between SD and LD groups. On the other hand, the expression levels of AN and ANR genes were significantly higher (or up-regulated in quail fed diets contaminated with aflatoxin and treated with short (AFSD group) or long (AFLD group) duration of ozone as compared to those found in quail fed contaminated diets with aflatoxin alone (AF group). Moreover, there were no significant differences between AFSD and AFLD groups for the expression level of AN or ANR genes, however, the levels of gene expression of AN or ANR in AFLD group were the highest.

Testes Weight: Table (3) showed that the weight of testes slightly decreased in quail fed diet contaminated with aflatoxin (AF group) as compared to those in the control group; however, this decrease was not significant. On the other hand, the weight of testes increased in quail fed diets treated with short (SD group) or long (LD group) duration of ozone in comparison with those found in the control group (C group), the SD group had the highest weight. However, there were no significant differences for the testes weights between SD or LD and control groups or between SD and LD groups. Moreover, the weights of testes were improved in quail fed diet contaminated with aflatoxin and treated with short (AFSD) or long (AFLD) duration of ozone as compared to those found in quail fed diet contaminated with aflatoxin alone (AF group). The improvement of testis weight was more effective in AFSD group than AFLD group; however, there were no significant differences between AFSD or AFLD and AF groups or between AFSD and AFLD groups.

Histopathology Analysis

Liver: The liver section from the control (Figures 6-A, 6-D) and ozone groups revealed normal histological pictures. When compared with the normal liver tissues of the vehicle controls, liver tissue in the quail exposed to aflatoxin showed different features of histopathological changes and liver injuries, characterized by moderate to severe hepatocellular degeneration and necrosis (Figure 6-B). Moreover, inflammatory cell infiltration, congestion and blood vessels dilatation were found (Figure 6-C).

The histopathological changes and liver injuries induced by aflatoxin were lowered when quail fed diets contaminated with aflatoxin and treated with ozone LD level (Figure 6-E) and remarkably lowered when treated with the ozone SD level (Figure 6-F).

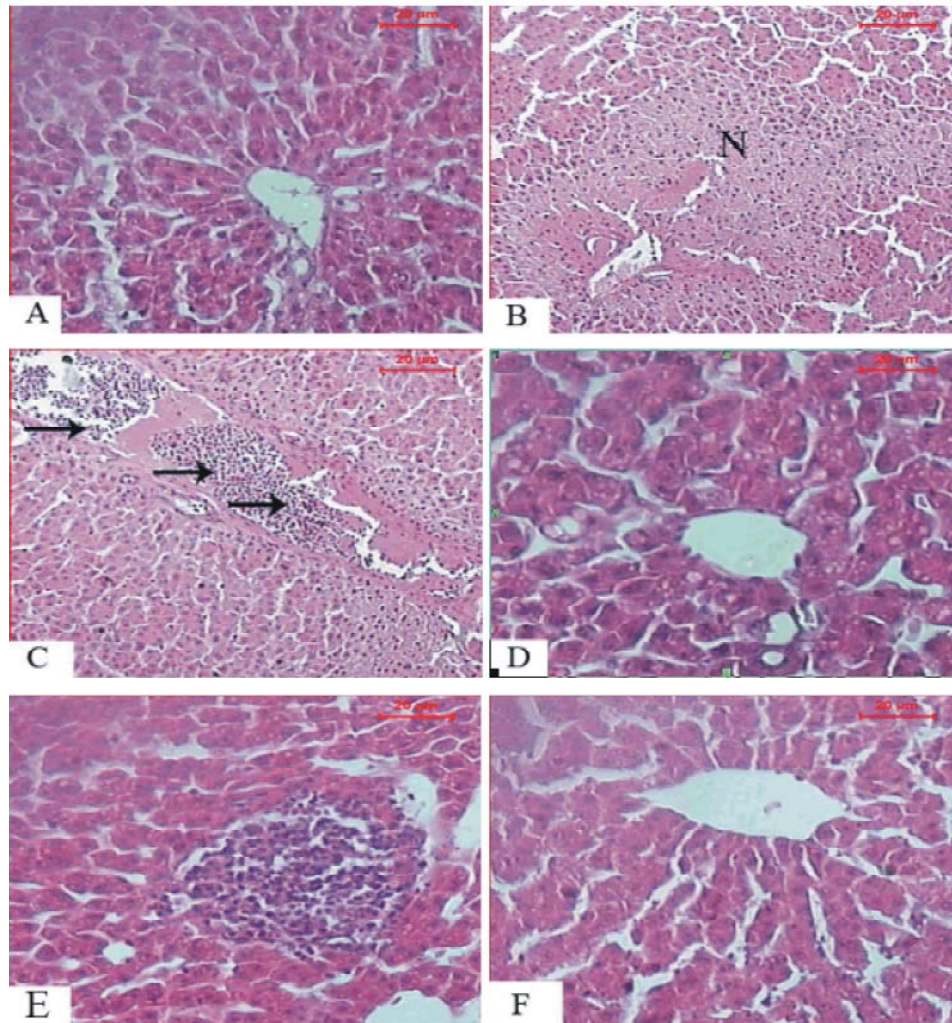


Fig. 6: Photomicrographs of A): a T.S. of control quails liver shows the normal structure of the hepatocytes, (B): a T.S. of liver of aflatoxin-administration quails showing distinct area of necrosis (N), (C): a T.S. of liver of aflatoxin-administration quails showing dilated and congested vein as well as the lymphocytic infiltration (arrows). (D): a T.S. of liver of quail groups showing the normal structure of the hepatocytes. (E): a T.S. of liver of quail fed diets contaminated with AFB1 and treated with LD duration of ozone demonstrating decreased the liver damaged area compared to that of aflatoxin treated group. (F): T.S. of liver of quail fed diets contaminated with AFB1 and treated with SD duration of ozone illustrating ameliorated histopathological changes.

Testis: Microscopic examination of quail's testes revealed that seminiferous tubules and spermatogenesis appeared normal in control and ozone treated groups (Figure 7-A, 7-D). Testes of quail exposed to aflatoxin showed many histopathological changes. These changes included degeneration of the germinal epithelium and rupture in the spermatogenesis layer large spaces between the spermatogenic cells. Morphometrically, seminiferous tubules were reduced in their diameters and appeared with wide lumens, as well as, decreased the spermatogenic cells layer thickness (Figure 6-B). Blood

hemorrhage was common in the intertubular connective tissue, persist cells appeared with pyknotic nuclei (Figure 7-C).

Examination of testes of quail fed diets contaminated with aflatoxin and treated with LD ozone revealed less prominent histopathological changes when compared with the aflatoxin treated group (Figure 7-E). Testes of quail fed diets contaminated with aflatoxin and treated with SD ozone revealed remarkable amelioration and more or less as a control group (Figure 7-F).

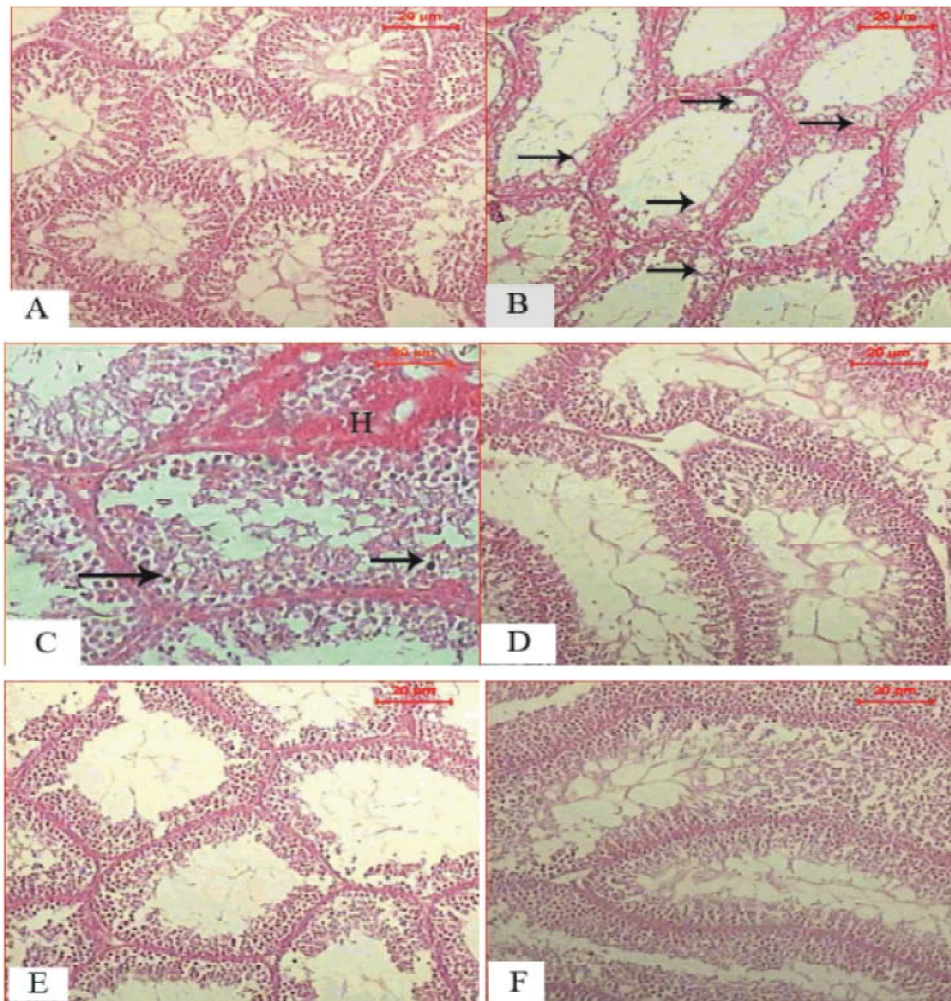


Fig. 7: Photomicrographs of (A): a T. S. of the testis of the control quails shows normal structure of seminiferous tubules containing different types of spermatogenic cells, (B): a T.S. of the testis of quails treated with aflatoxin showing rupture in the spermatogenic layer (arrow), decreased the spermatogenic cells layer thickness and wide lumens of seminiferous tubules, (C): a T.S. of the testis of quails treated with aflatoxins illustrating hemorrhage in the intertubular connective tissue (H) and pyknotic nuclei (arrows), (D): a T.S. of the testis of quail groups treated with ozone showing normal structure of seminiferous tubules containing different types of spermatogenic cells, (E): a T.S. of the testis of quails fed diets contaminated with AFB1 and treated with LD duration of ozone revealed less improvement in spermatogenic cells compared to that of aflatoxin treated group, and (F): a T.S. of the testis of quails fed diets contaminated with AFB1 and treated with SD duration of ozone illustrating remarkable improvement in the seminiferous tubules which more or less similar to that of the control.

DISCUSSION

The present results showed that quail fed diet contaminated with aflatoxin had significant increase of MnPCEs and DNA fragmentation as well as significant decrease of expression of AN gene and its receptor (ANR) as compared to the control group. Moreover, histopathological examination revealed severe lesions of liver and testis tissues.

AFB1 genotoxicity might be caused through the formation of AFB1-DNA adducts. This toxin is metabolized by the mixed-function oxidase system to a number of hydroxylated metabolites and to aflatoxin 8, 9 epoxide which binds to DNA, forming covalent adducts [28] and disturbs DNA replication causing genetic alteration [29-31]. The adduct formation occurs preferably with guanine resulting in AFB1-N-7 guanine adduct responsible for mutagenesis in AFB1-treated cells [32].

The interaction of AFB1 can be with the total genomic DNA [33]. This can result in small to large changes in genomic DNA including micronuclei and DNA fragmentation [32 - 34] as confirmed by our findings in the present study. Micronucleus assaying, as of chromosome aberrations, is a cytogenetic form that measures chromosomal damage, thus it is only effective when both DNA strands are broken [35, 36].

Also, several reports suggested that toxicity might ensue through the generation of intracellular reactive oxygen species (ROS) like superoxide anion, hydroxyl radical and hydrogen peroxide (H₂O₂) during the metabolic processing of AFB1 in the liver. These ROS may attack soluble cell compounds as well as membranes, eventually leading to the impairment of cell functionality, cytotoxicity and genotoxicity [37, 38]. This is confirmed in our findings by the presence of more frequent micronuclei and DNA fragmentation in the aflatoxin group than the control group.

The down regulation of the expression of AN and ANR genes in our study was supported by the report of Eshak et al. [39]. They found that the gene expression of glyceraldehyde phosphate Dehydrogenase (GAPDH), Neural- cadherin (N- Cadherin), Neural cell adhesion molecule (NCAM) and cytochrome P450 cholesterol side chain cleavage (P450 scc) genes were down regulated in the quail fed diet containing AFB1 as compared to the normal controls. Also, our findings can be explained by the reports of Ahmed and Singh [40] in chickens, and Ibegwuonu and Llewellyna et al. [41, 42] in rats. The authors found that the concentrations of RNA in the nervous tissues were depressed by AFB1 treatment. Verma [2] reported that after bioactivation of aflatoxins in liver, it can bind with RNA polymerase and might affect the translocation processes. On the other hand, histopathological results in this study of both liver and testes might reflect and explain the DNA damage (including MnPCE and DNA fragmentation) and down regulation of the expression of AN and ANR genes. Microscopic examination of the liver and testis sections of the AFB1-treated groups showed severe histopathological changes typical to those reported in the literature especially, hepatocellular degeneration, necrosis, inflammatory cell infiltration and congestion in the liver [43- 46]. Also, degeneration of the germinal epithelium, rupture in the spermatogenic layer, reduction of somiferous tubules diameter and decrease of spermatogenic cells layer thickness were reported in testis tissues [34,47-49].

Compared to quail fed the diet contaminated with aflatoxin alone, the present results showed that the quail fed diets contaminated with aflatoxin and treated with short or long duration of ozone had decreased MnPCEs and DNA fragmentation as well as enhanced the expression level of AN and ANR genes. Moreover, the histopathological examinations revealed less prominent histopathological changes and remarkable amelioration in liver and testis tissues. These findings indicated that the treatment with ozone has reduced or degraded the aflatoxin contamination in the birds diets. Consequently, the adverse effect of such decontaminated (ozone treated) feed on animal health might be diminished. The reduction or degradation of AFB1 by ozone treatment had been reported in earlier studies; Wang et al. [50] found that the treatment with ozone had reduced aflatoxin levels by 92% in the animal diets and no reversion to the parent compound was observed. Moreover, the effect of ozone on the degradation of AFB1 was studied and determined [14,51,52]. In these studies, standard solutions containing AFB1 were dried and suspended in water and treated with ozone for up to 60 seconds. Dichloromethane extracts and the remaining water solution of the samples were evaluated with 2-D thin layer chromatography (TLC). Dichloromethane extracts analysis showed that AFB1 was totally degraded after 60 Seconds.

In the current study, the reduction of AN and ANR expression was associated with the reduction of testes weights. In contrast, the enhancement of the expression of such genes was accompanied by an increase in the testes weights. Because weight of the testes largely depends on the mass of the differentiated spermatogenic cells [53], the marked reduction in testes weights by AFB1, can be explained by a reduction in androgen and its receptor [54] as confirmed by our findings. In contrast, the improvement of testes weight in quail fed diets treated with ozone indicated that the treatment of ozone reduced or minimize the AFB1 effects in the diets [55, 50]. Our findings were supported by the report of Liao et al. [54], who observed that the abnormal expression of ANR gene in testicular tissues of clincken-quail hybrids had reduced the function of androgen regulating Sertoli cells and consequently led to reduction of growth and development of testes.

In the present study, it was found that feeding diets treated with ozone for long duration had less improvement in genetic and histopathological changes in comparison to feeding on diets treated with ozone for short duration. These findings indicated that some nutrients in the foods

and feeds, especially proteins, were degraded and destroyed by long duration of ozone treatment and consequently led to decreased protein level in the diets [14, 56, 57].

Earlier studies indicated that feeding sheep diets containing low level of protein led to deleterious effect in their genetic materials. Farag and Awadalla [58] found that the sheep which were fed a diet containing high protein level had few frequencies of chromosomal aberrations and high fertility as compared to sheep fed diet containing medium or low protein level. Moreover, in previous studies it was found that using a high protein diet was considered as an anti-carcinogenic agent [59, 60] and decreased the frequencies of chromosomal aberrations that was caused by carbayl doses (mutagenic agent) in both somatic and germ cells in mice [61].

Furthermore, in the present study, it was observed that quail fed basal diets (without aflatoxin contamination) treated with ozone for short duration showed genetic and histological improvements more than the control group. These improvements included low frequencies of MnPCEs and DNA fragmentation as well as enhancing the expression levels of AN and ANR genes and the histological structures of liver and testis tissues. The contamination with aflatoxin cause deleterious reactions in feed production (e.g. lipid oxidation in poultry meat) and adverse health effects in humans. Thus, it can be concluded that short ozone treatment in stored diets is a best duration for aflatoxin disinfection. Also, the application of such treatment is useful in food industry for the destruction and detoxification of toxic chemicals or dangerous microorganisms. This is a simple approach to reduce the bioavailability of aflatoxins in the animal feed and subsequently decrease health hazards in human being.

REFERENCES

1. Huwig, A., S. Freimund, O. Kappeli and H. Dutler, 2001. Mycotoxin detoxification of animal feed by different absorbents. *Toxicology Letters*, 122: 177-188.
2. Verma, R.J., 2004. Aflatoxins cause DNA damage. *Int. J. Hum. Genet.*, 4(4): 231-236.
3. Bauer, J., 1994. Möglichkeiten zur Entgiftung mykotoxinhaltiger Futtermittel. *Monatsh. Veternärmed*, 49: 175-181.
4. McKenzie, K.S., A.B. Sarr, K. Mayura, .H. ailey, D.R. Miller, T.D. Rogers, W.P. Norred, K.A. Voss, R.D. Paltner, L.F. Kubena and T.D. Phillips, 1997. Oxidative degradation and detoxification of mycotoxins using a novel source of ozone. *Food and Chem. Toxicol.*, 35: 807-820.
5. Lemke, S.L., K. Mayura, S.E. Ottinger, K.S. McKenzie, N. Wang, C. Fickey, L.F. Kubena and T.D. Phillips, 1999. Assessment of the estrogenic effects of zearalenone after treatment with ozone utilizing the mouse uterine weight bioassay. *J. Toxicol. Environ. Health*, 56: 283-295.
6. Park, D.L., 1993. Perspectives decontamination procedures. *Food Addit. Contam.*, 10: 49-60.
7. Silva, L.M., L.A. Da de-Faria and J.F. Boodts, 2001. Green processes for environmental application: Electrochemical ozone production. *Pure and Applied Chemistry*, 73: 1871-1884.
8. Raila, A., A. Lugauskas, D. Steponavicius, M. Railiene, A. Steponaviciene and E. Zvicevicius, 2006. Application of ozone for reduction of mycological infection in wheat grain. *Annals of Agricultural and Environmental Medicine*, 13: 287-294.
9. Inan, F., M. Pala and I. Doymaz, 2007. Use of ozone in detoxification of aflatoxin B1 in red pepper. *Journal of Stored Products Research*, 43: 425-429.
10. Franco, D.V., W.F. Jardim, J.F. Boodts and L.M. Silva, 2008. Electrochemical ozone production as an environmentally friendly technology for water treatment. *Clean Soil, Air. Water*, 36: 34-44.
11. Wang, S., H. Liu, J. Lin and Y. Cao, 2010. Can ozone fumigation effectively reduce aflatoxin B1 and other mycotoxins contamination on stored grain? .10th International Working Conference on Stored Product Protection.
12. Jianwei, L., L. Rongtao, C. Lan and W. Junli, 2003. Research on O3 to degrade AFB1 in cereals. *Grain Storage*, 32: 29-33.
13. Proctor, A.D., M. Ahmedna, J.V. Kumar and I. Goktepe, 2004. Degradation of aflatoxins in peanut kernels/flour by gaseous ozonation and mild heat treatment. *Food Additives and Contaminants*, 21: 786-793.
14. Prudente, A.D. and J.M. King, 2002. Efficacy and safety evaluation of ozonagation to degrade aflatoxin in corn. *Journal of Food Science*, 67: 2866-2872.

15. Shotwell, O.L., C.V. Stubblefield and W.G. Sorneson, 1966. Production of aflatoxin on rice. *Applied Microbiology*, 14: 425-429.
16. Trucksess, M.W., M.F. Stack, S. Nesheim, R. Albert and T. Romer, 1994. Multifunctional column coupled with liquid chromatography for determination of aflatoxins B1, B2, G1 and G2 in corn, almonds, Brazil nuts, peanuts and pistachios nuts: Collaborative study. *Journal AOAC International*, 7: 1512-1521.
17. Goodarzi, M. and D. Modiri, 2011. The Use of clinoptilolite in broiler diet to decrease aflatoxin effects. *International Conference on Asia Agriculture and Animal IPCBEE vol. 13 (2011) IACSIT Press*. Singapore.
18. Deabes, M.M., H.R. Darwish, K.B. Abdel-Aziz, I.M. Farag, S.A. Nada and N.S. Tawfek, 2012. Protective effects of *Lactobacillus rhamnosus* GG on aflatoxins-induced toxicities in male albino mice. *Journal of Environmental & Analytical Toxicology*, 2(3): 2-9.
19. NRC, National Research Council, 1994. Nutrient requirements of poultry. 9th rev. National Academy Press, Washington, DC.
20. Adler, I.D., 1984. Cytogenetic tests in mammals. In: Venitt, S., Parry, J. M. (eds). *Mutagenicity testing (a practical approach)*. IRI Press, Oxford, pp: 275-306.
21. Gibb, R.K., D.D. Taylor, T. Wan, D.M. Oconnor, D.L. Doering and C. Gercel-Taylor, 1997. Apoptosis as a measure of chemosensitivity to cisplatin and taxol therapy in ovarian cancer cell lines. *Gynecologic Oncology*, 65: 13-22.
22. Voigt, C., G.F. Ball and J. Balthazart, 2009. Sex differences in the expression of sex steroid receptor mRNA in the quail brain. *J. Neuroendocrinol.*, 21(12): 1045-1062.
23. Hwang, H.S., K.J. Han, Y.H. Ryu, E.J. Yang, Y.S. Kim, S.Y. Jeong, Y.S. Lee, M.S. Lee, S.T. Koo and S.M. Choi, 2009. Protective effects of electro-acupuncture on acetylsalicylic acid-induced acute gastritis in rats. *World J. Gastroenterol.*, 15: 973-977.
24. Bio-Rad Laboratories, Inc., 2006. *Real-Time PCR applications guide*. Bulletin, 5279, pp: 101.
25. Drury, R.A.B. and E.A. Wallington, 1980. *Carleton's histological technique*, 5th ed. London, Oxford University Press, pp: 167-237.
26. SAS Institute Inc., 2004. *SAS/STAT 9.1 User's Guide*, Cary, NC: SAS Institute Inc.
27. Duncan, D.B., 1955. Multiple range and multiple F tests. *Biometrics*, 11: 1-42.
28. Busby, W. F. Jr. and G.N. Wogan, 1984. Aflatoxins. In: Searle, C. E. (ed.). *Chemical carcinogens*, 2nd ed. ACS Monograph 182. Washington DC. American Chemical Society, pp: 945-1136.
29. Sinha, S.P. and V. Prasad, 1990. Effect of dietary concentration of crude aflatoxin on meiotic chromosomes, sperm morphology and sperm count in mice, *Mus musculus*. *Proc. Indian Nat. Sci. Acad.*, 56: 269-276.
30. Sharma, R.A. and P.B. Farmer, 2004. Biological relevance of adduct detection to the chemoprevention of cancer. *Clin Cancer Res.*, 10: 4901-4912.
31. Preston, R.J. and G.M. Williams, 2005. DNA-reactive carcinogen; mode of action and human cancer hazard. *Criterion Rev Toxicol.*, 35: 673-683.
32. Kallio, M. and J. Lahdetie, 1997. Effects of the DNA topoisomerase II inhibitor membrane in male mouse meiotic divisions in vivo cell cycle and induction of aneuploidy. *Environ. Mol. Mutagen*, 29: 16-27.
33. Choy, W.N., 1993. A review of the dose-response induction of DNA adducts by aflatoxin B1 and its implications to quantitative cancer-risk assessment. *Mutat. Res.*, 296: 181 -198.
34. Faridha, A., K. Fasial and M.A. Akbarsha, 2006. Duration-dependent histopathological and histometric changes in the testis of aflatoxin B1-treated mice. *J. Endocrinol. Reprod.*, 10(2): 117-133.
35. Slamenova, D., A. Gabelova, L. Ruzekova, I. Chalupa, E. Horvathova, T. Farkasova, E. Bozsakyova and R. Stetina, 1997. Detection of MNNG-induced DNA lesions in mammalian cells. Validation of comet assay against DNA unwinding technique, alkaline elution of DNA and chromosomal aberrations. *Mutat. Res.*, 383: 243 -252.
36. Zeni, O. and M.R. Scarfi, 2010. DNA damage by carbon nano tubes using the single cell gel electrophoresis technique. *Methods Mol. Biol.*, 625: 109-119.
37. Towner, R.A., S.Y. Qian, M.B. Kadiiska and R.P. Mason, 2003. In vivo identification of aflatoxin-induced free radicals in rat bile. *Free Radic. Biol. Med.*, 35: 1330-1340.
38. Berg, D., M. Youdim, and P. Riedere, 2004. Redox imbalance. *Cell Tissue Res.*, 318: 201-203.

39. Eshak, M.G., W.K.B. Khalil, E.M. Hegazy, I.M. Farag, M. Fadel, and F.K.R. Stino, 2010. Effect of yeast (*Saccharomyces cerevisiae*) on reduction of aflatoxicosis, enhancement of growth performance and expression of neural and gonadal genes in Japanese quail, *Journal of American Science*, 6(12): 824-838.
40. Ahmed, N. and U.S. Singh, 1984. Effect of aflatoxin B1 on brain serotonin and catecholamines in chickens. *Toxicology Letters*, 21: 365-367.
41. Ibegwuonu, F.L., 1983. The neurotoxicity of aflatoxin B1 in the rat. *Toxicology*, 28: 247-259.
42. Llewellyna, G.C., W.V. Dashekb, T.D. Kimbroughc, C.E. OReard and L.B. Weekleye, 1988. Aflatoxin B1 affects feed consumption in male rats through an action on the central nervous system. *International Biodeterioration*, 24: 417-425.
43. Ortatatl, M., H. Oguz, F. Hatipoglu and M. Karaman, 2005. Evaluation of pathological changes in broilers during chronic aflatoxin (50 and 100 ppb) and clinoptilolite exposure. *Research in Veterinary Science*, 78: 61-68.
44. Naaz, F., S. Javed and M. Abdin, 2007. Hepatoprotective effect of ethanolic extract of *Phyllanthus amarus* Schum on aflatoxin B1 induced liver damage in mice. *J. Ethnopharmacol.*, 113: 503-509.
45. El-Agamy, D., 2010. Comparative effects of curcumin and resveratrol on aflatoxin B1-induced liver injury in rats. *Arch. Toxicol.*, 84 (5): 389-396.
46. Darwish, H.R., E.A. Omara, K.B. Abdel-Aziz, I.M. Farag, S.A. Nada and N.S. Tawfek, 2011. *Saccharomyces cerevisiae* modulates aflatoxin-induced toxicity in male albino mice, *Report and Opinion*, 3 (12): 32-43.
47. Piskac, A., J. Drábek, R. Halouzka and L. Groch, 1982. The effect of long term administration of aflatoxins on the health status of male rats and pigs with respect to morphological changes in the testes. *Vet Med (Parha)*, 27(2): 101-111.
48. Verma, R.J. and A. Nair, 2002. Effects of aflatoxins on testicular teroidogenesis and amelioration by vitamin. *Food chem. Toxicol.*, 4: 669-672.
49. Agnes, V.F. and M.A. Akbarsha, 2003. Spermato-toxic effect of aflatoxin B1 in the albino mouse. *Food Chem. Toxicol.*, 41: 119-130.
50. Wang, Y., J.M. King, J. Losso and Z. Xu, 2005. Evaluation of lutein and proteins in ozone treated corn. Refereed abstract and presented at the IFT annual meeting, July, abstract number 32-7, New Orleans.
51. Prudente, A.D. and J.M. King, 2004. Mutagenic potential of ozone-related aflatoxin reaction products in Corn. Presented at the National American Oil Chemists Society Annual meeting, May, Cincinnati, OH.
52. Menelaou, E., J.M. King and J. Losso, 2004. Isolation of aflatoxin-free lutein and corn oil from aflatoxin-contaminated corn. Presented at the National IFT meeting, Las Vegas, Nevada.
53. Carreau, S., C. Lambard, I. Denis-Galeraud, B. Bilinska and S. Bourguiba, 2003. Aromatase expression and role of estrogens in male gonad; a review. *Reprod Biol Endocrinol.*, 11: 1-35.
54. Liao, H., X. Guo, L. Zhou, Y. Li, X. Li, D. Liang, D. Li, and N. Xu, 2012. Expressin of androgen and estrogen receptors in the testicular tissue of chickens, quails and chicken-quail hybrids. *African Journal of Biotechnology*, 11(29): 7344-7353.
55. Prudente, A.D. and J.M. King, 2006. Effects of ozone on the degradation of aflatoxin B1 in a model system presented at the IFT annual meeting, abstract number 003F-07, Orlando, FL.
56. Seung-Wook, S., 2006. Depolymerization and decoloration of chitosan by ozone treatment. M.S. Thesis. Louisiana State University, pp: 84.
57. Seo, S., J.M. King and W. Prinyawiwatkul, 2006. Controlling molecular weight of chitosan by ozone treatment. Presented at the IFT annual meeting, abstract number 078A-01, June, Orlando, FL.
58. Farag, I.M. and I.M. Awadalla, 1996. The effect of levels of nutrition on the productive performance and chromosome changes in Ossimi sheep. *Zag. Vet. J. (ISSN. 1110 - 1458)*, 24(4): 24-37.
59. Melmed, R.N., A.A. El-Aser and S.J.S.J. Holt, 1976. Hypertrophy and hyperplasia of the neonatal rat exocrine pancreas induced by orally administered soyabean trypsin inhibitor. *Biochem. Biophys. Acta*, 421: 280-286.
60. Zakhary, N.I., N.K. Badr El-Din, A.A. El-Asaer, H.A. Ibrahim and N.Z. Moharram, 1989. Effect of soyabean feeding and vitamin C on experimental carcinogenesis.5: Biochmeical changes in the liver of albino mice induced by feeding nitrite and dibutylamine. *J. Egypt. Cancer Inst.*, 4: 173-181.
61. El-Fiky, S.A., K.B. Abdel Aziz and S.A. Abdel Basel, 1992. Protective role of soybean against chromosomal and biochemical effects of carbaryl (sevin) in male mice. *J. Egypt. Soc. Toxicol.*, 9: 15-25.