

Modulation of Gentamicin-induced Testicular and Brain Damage in Rats

Zeynab Kh. El-Maddawy

Department of Pharmacology,
Faculty of Veterinary Medicine, Alexandria University, Egypt

Abstract: The effects of the aminoglycoside antibiotic gentamicin, on blood, reproductive system and brain tissue of rats and the concurrent administration of L-carnitine with the drug were studied. Rats were intramuscularly injected with gentamicin at a dose of 20 or 80 mg/kg b.wt. i.m., divided into three equal doses daily for 10 days and killed at the 11th or 57th day of experiment. Gentamicin induced significant reduction in index weight of testes, epididymis, accessory sex organs, sperm cell concentration, motility, live sperms percentages and testosterone hormone level. While testicular total cholesterol and sperm abnormalities were increased. The drug also caused a significant decrease in the activity of testicular and brain catalase and reduced glutathione (GSH) content. Also the level of lipid peroxidation product malondialdehyde (MDA) showed a significant increase. Some histopathological changes in testicular and brain tissues in addition to adverse effects on hematological parameters were also recorded. The intensity of these adverse effects increased significantly with the high dose of the drug. The subcutaneous injection of L-carnitine (200 mg/kg b.wt.) once/day for 56 successive days improved significantly the previously mentioned parameters compared to gentamicin treated groups in both periods of experiment. Moreover, all studied parameters were restored to normal values in L-carnitine with gentamicin (20 mg/kg b.wt.) treated group at the 57th day of experiment. In conclusion, injection of therapeutic or high dose of gentamicin induced adverse effects on reproductive system, blood and brain tissue of male rats. Interestingly administration of L-carnitine with gentamicin ameliorates these adverse effects by improving antioxidant status and reducing lipid peroxidation.

Key words: Gentamicin • Testes • Brain • Oxidative Stress • L-carnitine • Antioxidant status

INTRODUCTION

Gentamicin is an aminoglycoside antibiotic, it acts by inhibiting protein synthesis in susceptible bacteria resulting in cell death (bactericidal). It has rapid onset of action, low rate of true resistance [1], high antibacterial efficacy and is commonly used for the treatment of several pathogenic Gram-negative bacterial infections. It is also active against some Gram-positive organisms, e.g. Staphylococcus (including methicillin and penicillin resistant strains). *In vitro* gentamicin is active against Salmonella and Shigella [2].

Gentamicin is rapidly absorbed after i.m. injection and peak serum levels are usually achieved within 30 to 90 minutes and are measurable for 6-8 hours. It is widely distributed into body fluid and also can be detected in

tissues [1]. Gentamicin does not appear to be metabolized and excreted almost entirely by renal glomerular filtration and excreted unchanged in the urine. A major complication of gentamicin treatment is nephrotoxicity even with the therapeutic doses [3]. Gentamicin induced nephrotoxicity could be due to the drug generation of reactive oxygen species (ROS) [4-7].

ROS destroy the cell components (lipids, proteins and DNA). Peroxidation of membrane lipids during oxidative stress induces the fragmentation of polyunsaturated fatty acids and release of various aldehydes and alkenes [7].

L-carnitine (4N-trimethylammonium-3-hydroxybutyric acid), L-lysine derivative, is a naturally occurring amino acid-like compound and it is an endogenous mitochondrial membrane compound [8]. L-carnitine plays

Corresponding Author: Zeynab Khamis EL-Maddawy, Department of Pharmacology,
Faculty of Veterinary Medicine Alexandria University, Edfina-Rashid-Behera, P.O. Box: 22758, Egypt.
Tel: +20-1007284201, Fax: +20-452960450.

an important role for facilitating or a transport of long chain fatty acids from cytosol to mitochondria in order to enter the β -oxidation cycle [9-11]. Carnitine is also associated with buffering of excess acetyl-Co A which is potentially toxic to the cells [9]. It is mainly used as an effective nutritional supplement and also for antioxidant activity.

There were few studies investigating the role of gentamicin in reproductive system and brain tissue so this work was designed to evaluate some pharmacodynamic effects of gentamicin on male albino rats, through studying the effects of drug on semen characters, some hematological, biochemical, hormonal and histopathological changes. Also this study extended to investigate the protective effects and possible mechanism of action of L-carnitine against gentamicin induced adverse effects.

MATERIALS AND METHODS

Gentamicin was obtained from Memphis Company, Egypt under authority of Schering-plough corporation/USA.

L-carnitine provided by Arab Company for Pharmaceuticals and Medicinal Plants (Mepaco-Medifood), Egypt. The diagnostic kits determining values of Hb, total cholesterol, catalase level, GSH and MDA contents were obtained from Bio-diagnostic Company, Egypt.

Other chemicals purchased from EL-Gomhoria Company, Egypt.

Animals and Experimental Design: Seventy two Albino male rats of 180-200 days old and weighing 190 - 220 g were obtained from the Medical Research Institute of Alexandria University, Egypt. Rats received balanced ration, water and humane care in compliance with the guidelines of the National Institutes of Health (NIH) of Animal Care and the local committee approved this study. Rats were acclimatized 2 weeks prior to the experiments.

Rats were randomly assigned into 6 equal groups (12 rats / group)

Group 1: Rats received saline (6 ml/ kg b.wt. i.m.) divided into three equal doses daily for 10 days together with a single s/c injection of saline (2 ml/ kg b.wt.) daily for 56 successive days (control group).

Group 2: Rats received L-carnitine at a dose of 200 mg/kg b.wt. s.c. in 2 ml/ kg b.wt. saline [12] once/ day for successive 56 days.

Group 3: Rats received gentamicin at a dose of 20mg/kg b.wt. i.m. [13] divided into three equal daily doses for 10 days.

Group 4: Rats received gentamicin at a dose of 80 mg/kg b.wt. i.m. according to the modified method of Kopple *et al.* [12] divided into three equal daily doses for 10 days.

Group 5: Rats received gentamicin at a dose of 20 mg/kg b.wt. i.m. divided into three equal doses, daily for 10 days together with L-carnitine at a dose of 200 mg/kg b.wt. s.c. once/ a day for 56 successive days.

Group 6: Rats received gentamicin at a dose of 80 mg/kg b.wt. i.m. divided into three equal doses daily for 10 days together with L-carnitine at a dose of 200 mg/kg b.wt. s.c. once/ a day for 56 successive days

The duration of the present study was 56 days to cover the spermatogenic cycle in rats which ranges from 48-56 days [14].

Six rats from each treated and control groups were killed at the 11th day from drugs and saline administration to follow up some pharmacodynamic effects of the drugs on male rats. At the 57th day of experiment all rats were killed. All experimental rats were deprived of food overnight and individually weighed at the specific killing time. Blood, body organs and epididymal contents were obtained from treated and control rats.

Blood Samples: Fasting blood samples were collected via retro-orbital plexus bleeding at specific time for killing. From each rat 2 blood samples were collected one on EDTA for hematological studies and the other was left to clot then centrifuged at 3000 rpm for 15 min to obtain serum which stored at -20°C for hormonal assay.

Weight of Internal Body Organs: After collection of the blood samples, the animals were killed, immediately sacrificed by cervical decapitation. The testes, epididymis, prostate and seminal vesicle glands were dissected out, grossly examined and weighed. The index weight (I.W.) of each organ was calculated according to Matousek [15] where, I.W. = organ weight (g) / body weight (g) x 100.

Examination of Epididymal Sperm:

Epididymal Sperm Count: Epididymal spermatozoa were counted by a modified method of Yokoi *et al.* [16]. The epididymis was minced in 5 ml saline, placed in a rocker for 10 min and incubated at room temperature for 2min. The supernatant was diluted 1: 100 in a solution

containing 5 g NaHCO₃ (for breaking up the mucous droplets), 1 ml formalin 35% and 25 mg eosin per 100 ml distilled water. Approximately, 10 µl of the diluted semen was transferred to each counting chamber of an improved Neubaur haemocytometer (Depth 0.1 mm; LABART, Munich, Germany) and was allowed to stand for 5 min before counting under a light microscope at high power lens.

Epididymal Sperm Motility, Abnormalities and Live-sperm Percentages: A drop of freshly undiluted semen from the cauda epididymis was mixed with one drop of physiological saline on the slide. The progressively motile sperm percentage was evaluated microscopically under high power lens [17]. The percentages of live sperm and morphologically abnormal spermatozoa were determined after staining on the same slide with eosin-nigrosin stain. A total of 300 sperm were counted on each slide under high power lens of the light microscope and percentages of abnormal sperm and live ones were recorded according to Bearden and Fuquay [17].

Hematological Studies: Hemoglobin concentration was determined by the method described by Drabkin and Austin [18] using commercially available diagnostic kits. Packed cell volume percentage was determined by microhematocrite technique according to Dacie and Lewis [19]. Erythrocytic and total leukocytic counts were estimated using Double improved Neubauer haemocytometer [19].

Hormonal Assay: Serum testosterone was determined using an enzyme immunoassay kit (Immunometrics Ltd., London, UK) according to Demetrius [20].

Total Cholesterol Assay: Testicular total cholesterol was extracted with acetone-alcohol (1:1). Total cholesterol is determined after enzymatic hydrolysis and oxidation. The indicator quinoneimine is formed from hydrogen peroxide and 4-aminophenazone in the presence of phenol and peroxidase according to Allain *et al.* [21].

Antioxidant Status and Oxidative Stress Assays: One testis and part of brain of each rat were kept frozen at -70 °C for assessment of GSH and LPO contents and catalase activity. GSH level was measured based on the reduction of 5,5'-dithiobis (2-nitrobenzoic acid) (DTNB) with glutathione according to the method of Glatzle *et al.* [22]. LPO was represented as MDA which was measured after the reaction with thiobarbituric acid in acidic medium at 95°C for 30 minutes to form thiobarbituric acid reactive

product according to Ohkawa *et al.* [23]. Catalase activity was estimated based on the reaction of the enzyme with a known quantity of H₂O₂ according to Aebi [24].

Histological Examination: One testis from each rat were removed, washed with physiological saline, blotted on filter paper, rapidly fixed in modified Davidson's fluid for 48 h and stored in 70% alcohol until further processing [25]. The remaining parts of brains specimens were collected and fixed in 10% neutral buffered formalin solution. Five micron thick paraffin sections were prepared from both organs then stained with hematoxylin and eosin (HE) and later examined histopathologically [26].

Statistical Analysis: Results were statistically analyzed by ANOVA followed by Duncan's multiple range test. Data are presented as means plus or minus the standard error. The minimum level of significance was set at $p \leq 0.05$ [27].

RESULTS

Organs Weights: the obtained data revealed a significant decrease ($P \leq 0.05$) in index weight values of testes, epididymis and accessory sex organs in gentamicin at different doses and periods of experiment and L-carnitine + gentamicin (20 mg/kg at 11th day or 80mg/kg b.wt. at both periods) treated groups compared to control. The reduction was more evident in gentamicin (80mg/kg b.wt.) and less evident in L-carnitine with gentamicin (20mg/kg b.wt. at 11th day) treated groups (Table 2). However, L-carnitine completely restored the index weight values of reproductive organs in gentamicin (20 mg/kg b.wt.) treated group at 57th day compared to control (Table 1).

Seminal, Hormonal and Testicular Total Cholesterol Assays: There was a significant ($P \leq 0.05$) decrease in sperm cell concentration, motility and live percentages, testosterone hormone level and a significant elevation in sperm abnormalities and testicular total cholesterol values in rats treated with gentamicin at different doses and periods of experiment and L-carnitine + gentamicin (20 mg/kg at 11th day or 80mg/kg b.wt. at both periods) compared to control (Tables 2&3). The administration of L-carnitine with gentamicin improved the previously mentioned values except sperm cell concentration value with gentamicin dose (80mg/kg at 11th day) compared to gentamicin alone treated groups. Moreover, Table 2&3 showed that, all the above mentioned parameters were

Table 1: Effect of gentamicin and / or L-carnitine on index weight of testes, epididymis and accessory sex organs of rats

Parameter Group	Index weight of testes (g/100g b.wt.)		Index weight of epididymis (g/100g b.wt.)		Index weight of accessory sex organs (g/100g b.wt.)	
	At 11 th day	At 57 th day	At 11 th day	At 57 th day	At 11 th day	At 57 th day
Control	1.74±0.02 ^a	1.74±0.01 ^a	0.81±0.01 ^a	0.79±0.02 ^a	1.15±0.01 ^{ab}	1.19±0.01 ^a
L-carnitine	1.75±0.01 ^a	1.73±0.01 ^a	0.81±0.01 ^a	0.80±0.01 ^a	1.18±0.01 ^a	1.17±0.01 ^a
Gentamicin (20 mg /kg b.wt.)	1.51±0.02 ^b	1.50±0.02 ^b	0.56±0.01 ^c	0.57±0.01 ^b	0.94±0.01 ^c	0.89±0.01 ^b
Gentamicin (80mg/kg b.wt.)	1.12±0.01 ^d	1.08±0.01 ^d	0.45±0.02 ^c	0.46±0.02 ^c	0.46±0.01 ^c	0.51±0.02 ^c
Gentamicin (20 mg/kg b.wt.) + L-carnitine	1.42±0.01 ^b	1.72±0.01 ^a	0.64±0.01 ^b	0.76±0.02 ^a	1.11±0.02 ^b	1.17±0.01 ^a
Gentamicin (80mg/kg b.wt.) + L-carnitine	1.21±0.02 ^c	1.30±0.01 ^c	0.52±0.01 ^d	0.59±0.01 ^b	0.64±0.02 ^d	0.80±0.02 ^b

Values are expressed as mean ± S.E. N= 6. Values with different letters at the same column are significantly different at $P \leq 0.05$.

Table 2: Effect of gentamicin and / or L-carnitine on sperm cell concentration, motility and abnormalities of rats.

Parameter Group	Sperm cell concentration (x10 ⁶ /ml)		Sperm motility (%)		Sperm abnormalities(%)	
	At 11 th day	At 57 th day	At 11 th day	At 57 th day	At 11 th day	At 57 th day
Control	430.00±7.75 ^a	442.3±6.09 ^a	91.67±1.05 ^a	90.0±1.83 ^a	8.89±0.83 ^d	9.89±0.83 ^c
L-carnitine	437.50±8.54 ^a	440.0±7.30 ^a	90.83±1.54 ^a	90.8±1.54 ^a	9.8±0.54 ^d	9.33±0.54 ^c
Gentamicin (20 mg /kg b.wt.)	365.17±4.48 ^c	356.3±6.10 ^b	55.00±1.83 ^c	59.2±2.39 ^b	18.2±0.79 ^{bc}	17.2±0.89 ^b
Gentamicin (80mg/kg b.wt.)	325.33±5.00 ^d	315.0±5.32 ^c	35.83±2.39 ^d	35.8±2.39 ^c	35.2±1.39 ^a	32.2±1.39 ^a
Gentamicin (20 mg/kg b.wt.) + L-carnitine	391.67±2.79 ^b	436.3±7.78 ^a	63.33±1.67 ^b	85.0±1.83 ^a	15.0±0.83 ^c	8.5±0.83 ^c
Gentamicin (80mg/kg b.wt.) + L-carnitine	340.83±2.39 ^d	371.3±5.53 ^b	50.83±1.54 ^c	65.8±1.54 ^b	25.8±1.23 ^b	23.8±1.46 ^b

Values are expressed as mean ± S.E. N= 6. Values with different letters at the same column are significantly different at $P \leq 0.05$.

Table 3: Effect of gentamicin and / or L-carnitine on sperm live, testosterone and total cholesterol values of rats.

Parameter Group	Sperm live (%)		Testosterone (ng/ml)		Testicular total cholesterol (mg/g wet tissue)	
	At 11 th day	At 57 th day	At 11 th day	At 57 th day	At 11 th day	At 57 th day
Control	92.17±0.98 ^a	93.2±1.19 ^a	2.29±0.01 ^a	2.30±0.01 ^a	5.55±0.51 ^c	6.38±0.45 ^d
L-carnitine	93.00±0.37 ^a	93.3±1.26 ^a	2.28±0.01 ^a	2.30±0.01 ^a	5.00±0.70 ^c	6.10±0.42 ^d
Gentamicin (20 mg /kg b.wt.)	70.33±1.15 ^c	69.5±2.49 ^b	2.15±0.01 ^c	2.17±0.011 ^b	15.20±0.71 ^c	12.5±0.88 ^c
Gentamicin (80mg/kg b.wt.)	55.17±2.98 ^d	58.7±3.99 ^c	1.04±0.01 ^c	1.10±0.01 ^c	33.55±1.88 ^a	30.6±1.12 ^a
Gentamicin (20 mg/kg b.wt.) + L-carnitine	81.50±0.99 ^b	91.2±1.08 ^a	2.21±0.01 ^b	2.29±0.03 ^a	10.08±0.68 ^d	6.18±0.4 ^d
Gentamicin (80mg/kg b.wt.) + L-carnitine	65.33±2.39 ^c	74.2±1.70 ^b	1.13±0.01 ^d	1.18±0.02 ^c	23.17±1.66 ^b	18.6±1.09 ^b

Values are expressed as mean ± S.E. N= 6. Values with different letters at the same column are significantly different at $P \leq 0.05$.

Table 4: Effect of gentamicin and / or L-carnitine on testicular lipid peroxidation (MDA) level, reduced glutathione (GSH) content and catalase activity of rats.

Parameter Group	Testicular LPO (nmol MDA/g wet tissue)		Testicular GSH (umol/g wet tissue)		Testicular catalase (unit/g wet tissue)	
	At 11 th day	At 57 th day	At 11 th day	At 57 th day	At 11 th day	At 57 th day
Control	4.00±0.08 ^c	4.05±0.08 ^d	10.12±0.03 ^b	10.3±0.06 ^b	6.20±0.18 ^a	5.95±0.17 ^a
L-carnitine	3.95±0.05 ^c	3.97±0.09 ^d	11.92±0.09 ^a	12.2±0.13 ^a	6.38±0.14 ^a	6.13±0.10 ^a
Gentamicin (20 mg /kg b.wt.)	6.10±0.09 ^c	6.13±0.16 ^c	8.23±0.12 ^d	8.32±0.14 ^c	4.22±0.10 ^c	4.19±0.06 ^b
Gentamicin (80mg/kg b.wt.)	10.27±0.18 ^a	10.3±0.15 ^a	5.23±0.10 ^f	5.38±0.1 ^d	2.38±0.12 ^c	2.33±0.11 ^c
Gentamicin (20 mg/kg b.wt.) + L-carnitine	4.73±0.12 ^d	3.83±0.12 ^d	9.40±0.16 ^c	10.6±0.09 ^b	5.10±0.09 ^b	6.03±0.04 ^a
Gentamicin (80mg/kg b.wt.) + L-carnitine	8.15±0.11 ^b	6.84±0.13 ^b	7.60±0.07 ^e	8.52±0.07 ^c	3.40±0.14 ^d	4.35±0.10 ^b

Values are expressed as mean ± S.E. N= 6. Values with different letters at the same column are significantly different at $P \leq 0.05$.

Table 5: Effect of gentamicin and / or L-carnitine on brain lipid peroxidation (MDA) level , reduced glutathione (GSH) content and catalase activity of rats.

Parameter Group	Brain LPO (nmol MDA/g wet tissue)		Brain GSH (umol/g wet tissue)		Brain catalase (unit/g wet tissue)	
	At 11 th day	At 57 th day	At 11 th day	At 57 th day	At 11 th day	At 57 th day
Control	13.50±0.28 ^d	13.1±0.31 ^c	4.76±0.11 ^b	4.96±0.19 ^b	3.03±0.04 ^a	3.31±0.1 ^a
L-carnitine	13.20±0.23 ^d	13.1±0.27 ^c	5.21±0.14 ^a	5.92±0.07 ^a	3.08±0.08 ^a	3.37±0.15 ^a
Gentamicin (20 mg /kg b.wt.)	17.88±0.81 ^c	18.9±0.51 ^b	3.16±0.07 ^c	3.15±0.06 ^b	1.93±0.05 ^c	1.96±0.03 ^b
Gentamicin (80mg/kg b.wt.)	40.67±1.83 ^a	34.8±1.15 ^a	2.12±0.06 ^f	2.09±0.13 ^c	1.29±0.08 ^d	1.36±0.1 ^c
Gentamicin (20 mg/kg b.wt.) + L-carnitine	15.40±0.37 ^{cd}	12.6±0.22 ^c	4.07±0.06 ^c	5.83±0.12 ^a	2.43±0.06 ^b	3.42±0.19 ^a
Gentamicin (80mg/kg b.wt.) + L-carnitine	26.33±0.76 ^b	18.8±0.52 ^b	3.56±0.10 ^d	3.25±0.33 ^b	1.93±0.06 ^c	2.11±0.05 ^b

Values are expressed as mean ± S.E. N= 6. Values with different letters at the same column are significantly different at $P \leq 0.05$.

Table 6: Effect of gentamicin and / or L-carnitine on hemoglobin (Hb g%), packed cell volume (PCV %), red blood corpuscles (RBCs) and white blood cells (WBCs) counts of rats.

Parameter Group	Hb (g%)		PCV(%)		RBCs (x10 ⁶ cmm)		WBCs (x10 ³ cmm)	
	At 11 th day	At 57 th day	At 11 th day	At 57 th day	At 11 th day	At 57 th day	At 11 th day	At 57 th day
Control	13.00±0.12 ^a	13.1±0.13 ^a	43.73±0.34 ^a	43.5±0.33 ^a	7.02±0.11 ^a	7.00±0.09 ^a	9.93±0.08 ^a	10.5±0.33 ^a
L-carnitine	12.80±0.12 ^a	13.0±0.12 ^a	44.03±0.31 ^a	44.0±0.31 ^a	7.03±0.10 ^a	7.02±0.07 ^a	9.98±0.09 ^a	10.6±0.30 ^a
Gentamicin (20 mg /kg b.wt.)	10.53±0.27 ^{bc}	10.6±0.08 ^b	40.27±0.53 ^c	39.9±0.63 ^b	6.30±0.13 ^c	6.42±0.09 ^b	9.02±0.07 ^{bc}	9.35±0.17 ^b
Gentamicin (80mg/kg b.wt.)	9.10±0.28 ^d	9.57±0.23 ^c	35.20±0.29 ^d	36.5±0.43 ^c	5.87±0.11 ^d	5.82±0.2 ^c	8.83±0.08 ^c	9.09±0.39 ^c
Gentamicin (20 mg/kg b.wt.) + L-carnitine	10.87±0.34 ^b	12.8±0.09 ^a	41.80±0.36 ^b	43.8±0.21 ^a	6.72±0.14 ^b	7.02±0.13 ^a	9.20±0.09 ^b	10.30±0.9 ^a
Gentamicin (80mg/kg b.wt.) + L-carnitine	9.83±0.27 ^c	10.3±0.11 ^b	39.70±0.67 ^c	39.4±0.39 ^b	6.50±0.15 ^{bc}	6.40±0.08 ^b	9.10±0.05 ^b	9.35±0.10 ^b

Values are expressed as mean ± S.E. N= 6. Values with different letters at the same column are significantly different at $P \leq 0.05$.

completely restored to normal values in L-carnitine with gentamicin(20 mg/kg b.wt.) treated group at the 57th day of experiment.

Antioxidant Status and Oxidative Stress Assays:

Gentamicin at different doses and periods of experiment and L-carnitine + Gentamicin (20 mg/kg at 11th day or 80mg/kg b.wt.. at both periods) treated groups caused a significant ($P \leq 0.05$) increase in testicular & brain LPO represented by MDA level and a decrease in GSH content and catalase activity in the same tissues compared to control group (Tables 4&5). However, administration of L-carnitine alone induced a significant ($P \leq 0.05$) increase in testicular & brain GSH content compared to control.

Moreover, administration of L-carnitine + gentamicin reduced the intensity of increased LPO caused by the drug and partially restored antioxidant status, even the MDA level, GSH content and catalase activity were completely restored to normal values in gentamicin (20 mg/kg b.wt.) treated group at the 57th day of experiment (Tables 4&5).

Hematological Parameters: The obtained results showed that, there was a non significant effect ($P \leq 0.05$) on Hb g%, PCV%, RBCs and WBCs counts in L-carnitine at both periods of experiment and L-carnitine + gentamicin

(20mg/kg at 57th day) treated groups compared to control one. While there was a significant reduction ($P \leq 0.05$) in their values in other treated groups compared to control. The reduction was more evident in gentamicin (80mg/kg b.wt.) and less evident in L-carnitine with gentamicin (20mg/kg b.wt. at 11th day) treated groups (Table 6).

Histopathological Findings

Testes: Normal testicular architecture, well-organized seminiferous tubules with complete spermatogenesis and normal interstitial connective tissue observed in both control animals and rats treated with L-carnitine either at 11th or 57th day of experiment.

Testicular tissue of rats treated with gentamicin (20mg/kg) alone at 11th or 57th day of experiment showed congestion of the interstitial blood vessels.(Fig.1A), besides degenerative changes of some of the seminiferous tubules as incomplete spermatogenesis which represented by lack of the epithelial multilayers on the basement membrane of the seminiferous tubules.

Testicular tissue of rats treated with gentamicin (80mg/kg) at both periods of experiment showed edema of the interstitial blood vessels. (Fig.1B), significant degeneration of the seminiferous tubules represented by sever desquamation of germinal epithelium with necrosis of spermatocytes, spermatids, moreover there was hyalinization of the luminal contents (Fig.1C).

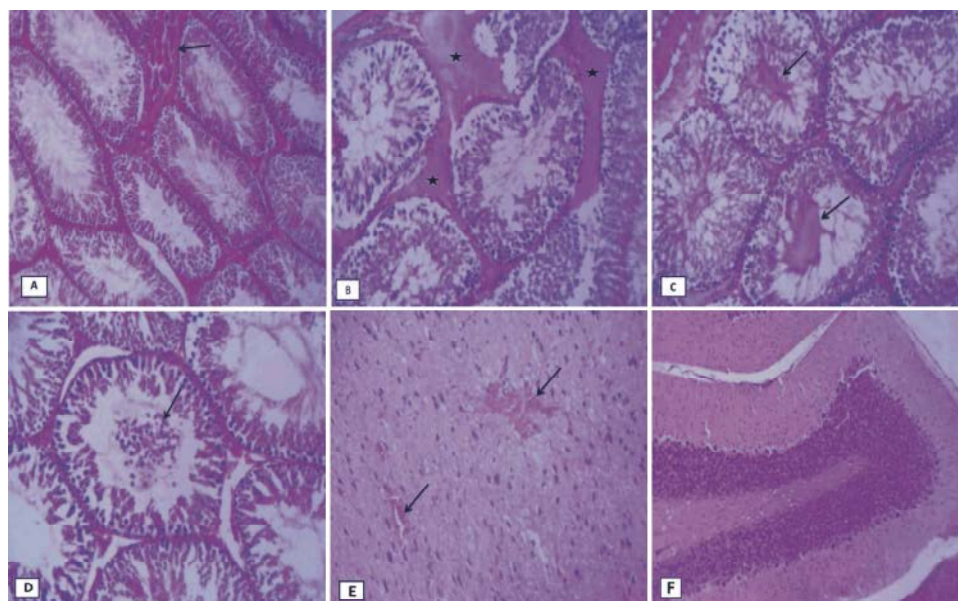


Fig. 1: Photomicrograph of rat testes and brain stained with HE(x 200): (A) Testicular tissue of rat treated with gentamicin (20mg/kg) alone at 11th day of experiment showed congestion of the interstitial blood vessels(arrow). (B) Testicular tissue of rat treated with gentamicin (80mg/kg) alone at 11th day showed edema of the interstitial blood vessels (stars). (C) Testis of rat treated with gentamicin (80mg/kg) alone at 57th day showed hyalinization of the luminal contents (arrows). (D) Testis of rat treated with L-carnitine +gentamicin (80mg/kg) at 57th day showed mild desquamation of germinal epithelium (arrow) with marked improvement of spermatogenesis. (E) Brain of rat treated with gentamicin (80mg/kg) at 11th day showed hemorrhage in Purkinje cell layer of the cerebellum(arrows). (F) Brain of rat treated with L-carnitine +gentamicin (80mg/kg) at 57th day showed mild edema in Purkinje cell layer of the cerebellum.

In animals treated with L-carnitine +gentamicin (20mg/kg) there was a protective effect on the testicular tissue where congestion of the interstitial blood vessels was absent with mild cellular degeneration of the tubular germinal epithelium at 11th of experiment. Moreover, relatively normal testes with low density of spermatozoa in which structurally and functionally active seminiferous tubules with presence of elongated spermatids and spermatozoa (with low density) in the majority of the tubules were detected at 57th of experiment.

In animals treated with L-carnitine +gentamicin (80mg/kg) there was a protective effect in testicular tissue start at 11th and become more pronounced at 57th day evidenced by mild desquamation of germinal epithelium with marked improvement of spermatogenesis(Fig.1D).

Brain: Microscopically, the brain showed slight congestion in blood vessels of cerebrum gray matter as well as in meninges in rats treated with gentamicin (20mg/kg) at 11th or 57th day of experiment. Moreover in rats treated with gentamicin (80mg/kg) at both periods of experiment the brain showed hemorrhage (Fig.1E) and mild

edema in Purkinje cell layer of the cerebellum (Fig.1F) in some cases.

In animals treated with L-carnitine +gentamicin (20mg/kg) there was a complete protective effect in the brain tissue (similar to those of control) at both periods of experiment.

There was a protective effect of L-carnitine in the group treated with gentamicin (80mg/kg) at both periods in the brain tissue as it had the normal histological appearance with congestion of some meningeal blood vessels in few cases.

DISCUSSION

Oxidative stress is considered one of the important causes of various diseases and organ toxicities.

Administration of gentamicin at both doses (20 or 80 mg/kg b.wt.) for both periods (11&57 days of experiment) induced some fertility abnormalities appeared as a significant reduction in testes, epididymis and accessory sex glands weights, testosterone hormone level, sperm cell concentration, motility and livability percentages.

Moreover, there was a significant increase in total sperm abnormalities % and testicular total cholesterol. These findings go side by side with the histological findings in testes. All these fertility troubles were more pronounced with high dose of the drug.

The reduction of testosterone hormone and elevation of testicular total cholesterol may be resulted from the effect of gentamicin on the steroidogenic enzymes, causing an alteration in the formation of testosterone and accumulation of cholesterol in the testes [28]. Also, the changes in testicular lipid profile were strongly correlated with testicular degeneration, histological and biochemical alteration [29]. The etiology may be ascribed to the fact that lipids, in particular cholesterol is the precursor of male sex hormones and thus increased testicular cholesterol may result from impaired utilization in steroidogenesis [30], associated with impaired testicular activity.

Khaki *et al.* [31] suggested that the necrosis of the interstitial cells may be resulted in decreased synthesis of testosterone hormone. This study showed an increase in testicular MDA levels, reduction in antioxidant reserves GTH and catalase in gentamicin treated groups in a dose dependant at different periods as compared to the control group. It indicates oxidative stress and its implications on testicular activity.

Gentamicin induced reproductive abnormalities as a result of its direct toxic effects on testes induced oxidative stress [32]. Spermatozoa have high content of polyunsaturated fatty acids in their plasma membrane thus they are highly susceptible to damage by excessive concentrations of ROS.

The lipid peroxidation damages the structure of lipid matrix in spermatozoa membranes lead to loss of motility and impairment of spermatogenesis [33]. Gentamicin inhibits germ cells division and protein synthesis in the testis. It also, induced cell death in the seminal vesicle [32]. These results are compatible with those of Narayana [32] and Akondi *et al.* [34].

Agarwal and Saleh [35] reported that excessive generation of free radicals may attack integrity of DNA in the sperm nucleus, thus accelerated the process of germ cell apoptosis, leading to decline in sperm counts and abnormalities associated with male infertility. Gentamicin induced increase in intracellular ROS content which can reach a toxic level, thus causing cell death and malfunctioning of the organ.

There were no reports as far as known describing the protective role of L-carnitine against gentamicin induced testicular oxidative damage. Inhibitors of oxidative stress

provide significant beneficial effect on gentamicin induced testicular oxidative stress. L-carnitine, considered as an important example for antioxidants that have been already proven as effective agents in various models both *in vitro* and *in vivo*.

The results showed that administration of L-carnitine with gentamicin treatment either 20 or 80mg/kg b.wt. at the 11th or 57th day of experiment improved the reproductive alteration induced by the drug. It reduced oxidative stress and improved antioxidant status and histological structure of testicular tissue. Also L-carnitine induced significant decrease in testicular total cholesterol and testosterone hormone levels. Sperm count and percentages of sperm motility and viability were improved. Moreover, all measured parameters were completely restored to normal values in group treated with gentamicin (20mg/kg b.wt.) at 57th day of experiment. Histopathological findings in the groups treated with L-carnitine also confirmed the previous improvement in testicular tissues.

It has been found that L-carnitine improved antioxidant status in rats and increased free radical scavenging from the cellular sites [36,37]. L-carnitine could protect HK-2 cells from H₂O₂-induced injury via inhibition of oxidative damage, cell apoptosis and mitochondria dysfunction [38].

Antioxidants protect DNA and other important molecules from oxidation and damage, thus improve sperm quality and consequently increase fertility rate [39,40].

This study showed that an increase in brain MDA level, reduction in antioxidant reserves GTH and catalase together with some histological changes in brain tissue in gentamicin (20 or 80 mg/kg b.wt.) treated groups at different periods as compared to the control group. the alterations in brain tissue increased with high dose.

Gentamicin was found to penetrate into the cerebrospinal fluid in healthy dogs. The increase of CSF concentration could be expected after repetitive gentamicin administration. Also, meningitis increases the penetration of parenterally administered gentamicin into the CSF [41, 42].

Decrease of antioxidant enzyme may be due to rapid consumption and exhaustion of storage of this enzyme in fighting free radicals generated during the development of brain damage.

The results of this investigation showed that administration of L-carnitine with gentamicin treatment either 20 or 80mg/kg b.wt. at 11 or 57 day of experiment reduced oxidative stress and improved the antioxidant status and histological changes in brain tissue. these results are in line with previous studies of Pallor *et al.* [43]

who demonstrated that L-carnitine induced a protective effects on the toxicity of brain injury in neonates related to hypoxia and ischemia and during ischemia-reperfusion cases.

Gopal *et al.* [44] found that d-Methionine (d-Met), a sulfur-containing nucleophilic antioxidant, has been shown to prevent cisplatin-induced central nervous system tissue damage from acute cisplatin toxicity.

L-carnitine reduced the oxidative stress and rotation behavior stimulated by quinolinic acid and 3-nitropropionic acid each alone or in combination in brain of rats, the protective properties of L-carnitine in the neurotoxic models tested are mostly mediated by its characteristics as an antioxidant agent [45].

The present investigation showed that there was a significant decrease in Hb g%, PCV%, RBCs and WBCs counts in gentamicin (20or 80mg /kg b.wt.) treated groups at the 11 or 57 day of experiment, the reduction was more pronounced with high dose. These results could be attributed to leukopenia, anemia, decreased reticulocyte counts and thrombocytopenia caused by the drug.

Gentamicin was shown to chelate mitochondrial iron forming iron-gentamicin complex which is a potent catalyst of free radical formation capable of inhibiting mitochondrial respiration causing cell death [46].

These results are compatible with those recorded by El Badwi *et al.* [47], Hasan *et al.* [48] in rats and mice, respectively.

Treatment with L-carnitine improved these hematological parameters due to its antioxidant parameters that enhanced hematopoiesis.

The present results detected that administration of L-carnitine daily induced significant increase in testicular and brain GTH at the 11th or 57th day of experiment as compared to control group. So, L-carnitine could offer protection by directly increasing tissue antioxidant capacities.

It could be concluded that gentamicin at therapeutic dose or high dose induced testicular and brain oxidative stress in addition to adverse effects on blood picture, the severity of these adverse effects increased with high dose. However, L-carnitine elicited a significant protective efficacy role against gentamicin-associated oxidative stress owing to its antioxidant property. So, the present study recommends that L-carnitine could be included in prescriptions along with gentamicin to ameliorate its adverse effects on hematological parameters, brain tissue and male fertility.

ACKNOWLEDGEMENT

The author would like to thank Dr. Hossam G. Tohamy (lecturer of Pathology, Faculty of Veterinary Medicine, Alexandria University), for his valuable help to the histopathological examination of this work.

REFERENCES

1. Chambers, H.F., 2008. Aminoglycosides. In: Goodman and Gilman's. The Pharmacological Basis of Therapeutics (Brunton, L.L., J.S. Laz and K.L. Parker). 11thEd. Medical Publication Division, New York, Chicacho, San Francesco, Lisbon, London, pp: 1165-1166.
2. Reiter, R.J., D. Tan, R.M. Sainz, J.C. Mayo and B.S. Lopez, 2002. Melatonin reducing the toxicity and increasing the efficacy of drugs. *Journal of Pharmacy and Pharmacology*, 5: 1299-1321.
3. Sweileh, W.M., 2009. A prospective comparative study of gentamicin and amikacin induced nephrotoxicity in patients with normal baseline renal function. *Fundamental and Clinical Pharmacology*, 23(4): 515-520.
4. Amini, F.G., M. Rafieian-Kopaei, M. Nematbakhsh, A. Baradaran and H. Nasri, 2012. Ameliorative effects of metformin on renal histologic and biochemical alterations of gentamicin-induced renal toxicity in Wistar rats. *Journal of Research in Medical Sciences*, 17(7): 621-625.
5. Rafieian-Kopaei M., H. Nasri, M. Nematbakhsh, A. Baradaran, A. Gheissari and H. Rouhi, 2012. Erythropoietin ameliorates gentamycin-induced renal toxicity: A biochemical and histopathological study. *Journal of Nephropathology*, 1: 109-116.
6. Stojiljkovica, N., M. Stoilkovicb, P. Randjelovica, S. Veljkovica and D. Mihailovicc, 2012. Cytoprotective effect of vitamin C against gentamicin-induced acute kidney injury in rats. *Experimental and Toxicologic Pathology*, 64(1-2): 69-74.
7. Halliwell, B. and S. Chirico, 1993. Lipid peroxidation: its mechanism, measurement and significance. *American Journal of Clinical Nutrition*, 57: 715-725.
8. Kelly, G.S., 1998. L-carnitine: Therapeutic applications of a conditionally-essential amino acid. *Alternative Medicine Review*, 3: 345-360.

9. Brass, E.M., 2000. Supplemental L-carnitine and exercise. *American Journal of Clinical Nutrition*, 72: 618-623.
10. Szilagyi, M., 1998. L-carnitine as essential methylated compound in animal metabolism. An overview., *Acta Biologica Hungarica*, 49: 209-218.
11. Rani, P.J. and C. Panneerselvam, 2001. L-carnitine as a free radical scavenger in aging. *Experimental Gerontology*, 36: 1713-1726.
12. Kopple, J.D., H. Ding, A. Letoha, B. Ivanyi, D.P. Qing and L. Dux, 2002. L-carnitine ameliorates gentamicin-induced renal injury in rats. *Nephrology Dialysis Transplantation*, 17: 2122-2131.
13. Paget, E. and M. Barnes, 1964. Evaluation of drug activities, toxicity test. *Pharmacometrics*. Academic Press, London. New York.
14. Clermont, Y. and S.C. Harvey, 1965. Duration of seminiferous epithelium of normal hypophysectomized and hypophysectomized hormone treated albino rats. *Endocrinology*, 79: 80-89.
15. Matousek, J., 1969. Effect on spermatogenesis in guinea pigs, rabbits and sheep after their immunization with sexual fluid of bulls. *Journal of Reproduction and Fertility*, 19: 63-72.
16. Yokoi, K., E.O. Uthus and F.H. Nielsen, 2003. Nickel deficiency diminishes sperm quantity and movement in rats. *Biological Trace Element Research*, 93: 141-154.
17. Bearden, H. and J. Fuquay, 1980. *Applied Animal Reproduction*. Reston Publishing Co., Inc. Reston, Virginia, pp: 158-160.
18. Drabki, N., D.L. and J.M. Austin, 1932. Spectrophotometric constants for common hemoglobin derivatives in human, dog and rabbit blood. *Journal of Biological Chemistry*, 98: 719-733.
19. Dacie, J.V. and S.M. Lewis, 1984. *Practical Haematology*. 6th Ed., ELBS and Churchill Livingstone, London, UK.
20. Demetrius, J.A., 1987. Testosterone in methods. In *Clinical Chemistry* (Tech, A.G. and L.A. Kaplan). 2nd Ed. CVMOS Co., pp: 268.
21. Allain, C.C., L.S. Poon, C.S. Chan, W. Richmond and P.C. Fu, 1974. Enzymatic determination of total serum cholesterol. *Clinical Chemistry*, 20: 470-475.
22. Glatzle, D., J. Vulliemuier, F. Weber and K. Decker, 1974. Glutathione reductase test with whole blood, a convenient procedure for the assessment of the riboflavin in status humans. *Experientia*, 30: 665-667.
23. Ohkawa, H.P., W. Ohishi and K. Yagi, 1979. Assay for lipid peroxides in animal tissues by thiobarbituric acid reaction. *Analytical Biochemistry*, 95(2): 351-358.
24. Aebi, H., 1974. Catalase. In: H.U. Bergmeyer and H. Ulrich, "Methods of Enzymatic Analysis", 2nd Ed., Verlag Chemic, Weinheim, New York, pp: 673.
25. Latendresse, J.R., A.R. Warbritton, H. Jonassen and D.M. Creasy, 2002. Fixation of testes and eyes using a modified Davidson's fluid: comparison with Bouin's fluid and conventional Davidson's fluid. *Toxicologic Pathology*, 30: 524-533.
26. Bancroft, J.D., A. Stevens and D.R. Turner, 1996. *Theory and Practice of Histological Technique*. 4th Ed., Churchill, Livingston, New York, London, San Francisco, Tokyo.
27. SAS, 2002. *Statistical Analysis System*. Statistics. L-carnitine y, NC: SAS Institute.
28. Ghosh, S. and S. Dasgupta, 1999. Gentamicin induced inhibition of steroidogenic enzymes in rat testis. *Indian Journal of Physiology and Pharmacology*, 43(2): 247-250.
29. Chowdhury, A.R., A.K. Gautam and V.K. Bhatnagar, 1990. Lindane-induced changes in morphology and lipid profile of testes in rats. *Biomedica Biochimica Acta*, 49: 1059-1065.
30. El-Sweedy, M., N. Abdel-Hamid and M. El-Moselhy, 2007. The role of a mixture of green tea, turmeric and chitosan in the treatment of obesity-related testicular disorders. *Journal of Applied Biomedicine*, 5: 131-138.
31. Khaki, A., A.A. Khaki, S. Iraj, P. Bazi, S.A.M. Imani and H. Kachabi, 2009. Comparative study of aminoglycosides (gentamicin & streptomycin) and fluoroquinolone (ofloxacin) antibiotics on testis tissue in rats: light and transmission electron microscopic study. *Pakistan Journal of Medical Sciences*, 25(4): 624-629.
32. Narayana, K., 2008. An aminoglycoside antibiotic gentamicin induces oxidative stress, reduces antioxidant reserve and impairs spermatogenesis in rats. *Journal of Toxicological Sciences*, 33(1): 85-96.
33. Pandev, L.K., S. Panday, S. Singh, S. K. Bhattacharya and B.K. Panda, 2000. Role of free radical in male infertility. *The International Journal of Gynecology and Obstetrics*, 70(2): 73-78.
34. Akondi, R.B., A. Akula and S.R. Challa, 2011. Protective effects of rutin and naringin on gentamicin induced testicular oxidative stress. *European Journal of General Medicine*, 8(1): 57-64.

35. Agarwal, A. and R.A. Saleh, 2002. Utility of oxidative stress test in the male infertility clinic. *Zhonghua Nan Ke Xue*, 8(1): 1-9.
36. Rani, P.J. and C. Panneerselvam, 2002. Effect of L-carnitine on brain lipid peroxidation and antioxidant enzymes in old rats. *Journals of Gerontology Series A: Biological Sciences and Medical Sciences*, 57: 134-137.
37. Sener, G., K. Paskaloglu, H. Satiroglu, I. Alican, A. Kacmaz and A. Sakarcan, 2004. L-L-carnitine ameliorates oxidative damage due to chronic renal failure in rats. *Journal of Pharmacology*, 43: 698-705.
38. Ye, J., J. Li, Y. Yu, Q. Wei, W. Deng and L. Yu, 2010. L-carnitine attenuates oxidant injury in HK-2 cells via ROS-mitochondria pathway. *Regulatory Peptides*, 161: 58-66.
39. Lu, P., B.S. Lai, P. Liang, Z.T. Chen and S.Q. Shun, 2003. Antioxidation activity and protective affection of ginger oil on DNA damage *in vitro*. *Journal of Zhongguo Zhong Yao ZaZhi*, 28: 873-875.
40. Jedlinska-Krakowska, M., G. Bomba, K. Jakubowski, T. Rotkiewicz, B. Jana and A. Penkowski, 2006. Impact of oxidative stress and supplementation with vitamins E and C on testes morphology in rats. *Journal of Reproduction and Development*, 52: 203-209.
41. Goitein K., J. Michel and T. Sacks, 1975. Penetration of parenterally administered gentamicin into the cerebrospinal fluid in experimental meningitis. *Chemotherapy*, 21(3-4): 181-188.
42. Krastev, S.V., 2008. gentamicin disposition in cerebrospinal fluid (csf) and aqueous humour in healthy dogs. *Trakia Journal of Sciences*, 6(1): 14-18.
43. Pallor, M.S., J.R. Holdal and T.F. Ferris, 1984. Oxygen free radicals in ischemic acute renal failure in the rat. *Journal of Clinical Investigation*, 74: 1156-1164.
44. Gopal, K.V., C. Wu, B. Shrestha, K.C. Campbell, E.J. Moore and G.W. Gross, 2012. d-Methionine protects against cisplatin-induced neurotoxicity in cortical networks. *Neurotoxicology and Teratology*, 34(5): 495-504.
45. Silva-Adaya, D., V. Pérez-De La Cruz, M.N. Herrera-Mundo, K. Mendoza-Macedo, J. Villeda-Hernández, Z. Binienda, S.F. Ali and A. Santamaria, 2008. Excitotoxic damage, disrupted energy metabolism and oxidative stress in the rat brain: antioxidant and neuroprotective effects of L- carnitine. *Journal of Neurochemistry*, 105(3): 677-689.
46. Priuska, E.M. and J. Schacht, 1995. Formation of free radicals by gentamicin and iron and evidence for an iron/gentamicin complex. *Biochemical Pharmacology*, 50:1749-1752.
47. El Badwi, S.M.A., A.O. Bakhiet and E.H. Abdel Gadir, 2012. Haemato-biochemical effects of aqueous extract of *Khaya senegalensis* stem bark on gentamicin induced nephrotoxicity in Wistar rats. *Journal of Biological Sciences*, 12: 361-366.
48. Hasan, H.F., A.M. Hamzah and Z.R. Zghair, 2013. Effect between *Cyperus Esculentus* seeds extract and gentamicin on induced endometritis in mice. *The Journal of Physics and Chemistry of Solids*, 7: 40-47.