

Protective Effect of Methanol Seed Extract of *Citrullus lanatus* on Paracetamol-Induced Hepatotoxicity in Adult Wistar Rats

¹Damilola Alex Omoboyowa, ¹Xavier Chizimuzo Akalomu, ²Ugochukwu B. Amadi and ¹Oti Agha Aja

¹Biochemistry Research Unit, Department of Science Laboratory Technology, Akanu Ibiam Federal Polytechnic, Afikpo, Ebonyi State, Nigeria

²Chemistry Research Unit, Department of Science Laboratory Technology, Akanu Ibiam Federal Polytechnic, Afikpo, Ebonyi State, Nigeria

Abstract: *Citrullus lanatus* is a plant used widely in the African system of medicine for its diverse medicinal and nutritional properties. Its extracts have a vast pharmacological activity and are used as raw materials for medicine and other commodities. Each part of this plant has its own therapeutic importance and uses which include: anti-anaemia, anti-malaria, antioxidant and others. The present study investigated the effect of methanolic extract of *Citrullus lanatus* seed on liver marker enzymes and liver histology of acetaminophen exposed hepatotoxic rats using standard protocols. A total of twenty (20) male wistar rats distributed into five groups (n=4) were used for the study. Group I rats served as normal control and were not exposed to paracetamol, while groups II, III, IV and V rats were exposed to 750 mg/kg body weight of paracetamol served as intoxicated test groups. Groups II, III, IV and V were treated with 0.5 ml distilled water, 25 mg/kg body weight of silymarin, 200 and 400 mg/kg body weight of *C. lanatus* seed extract respectively for seven days. At the end of the 7 days experimental period, all animals were sacrificed using cervical dislocation method; blood was obtained for assay of the following of hepatic marker enzymes; Alanine amino transaminase (ALT), Aspartate amino transaminase (AST), Alkaline phosphatase (ALP) and total bilirubin respectively. Liver tissue was removed, fixed in 10% formalin and processed for histopathological studies using Haematoxylin and Eosin (H and E) staining technique. The results indicated the presence of the phytochemical content of the extract in the order: alkaloids > steroids > terpenoids > flavonoids > saponins > tannins > phenol. Result of the acute toxicity test showed that the extract is safe at a dosage of up to 5000 mg/kg body weight. The results showed that induction of paracetamol caused significant ($P < 0.05$) increase in the marker enzymes and a multiple, mild to moderate periportal infiltration of mononuclear leucocytes in hepatocytes. It was observed that treatment with the extract caused dose-dependent significant ($P < 0.05$) decrease in plasma AST, ALT, ALP and bilirubin concentrations and increased protection in the damaged hepatocytes. Conclusion: the results observed in this study revealed the hepato-protective activity of methanol seed extract of *C. lanatus* which can substantiate its use in the treatment of hepatic damage in traditional medicine

Key words: Hepatotoxicity • Phytochemical • Enzymes • Paracetamol • Toxicity • Histopathology

INTRODUCTION

The liver is the largest glandular organ in the body (Approximately 1,500 grams) of the normal adult and is located in the right upper quadrant of the abdomen. It is glossy in appearance and dark red in color from the rich supply of blood flowing through it [1]. The liver has the primary metabolic function of regulating the blood

concentration of most metabolites, particularly glucose and amino acids [2]. The characteristic structure and organization of the liver enable it to perform vital roles in regulating, synthesis, storage, secretion and breaking down different substances in the body. In addition, the liver's ability to regenerate liver tissues helps maintain these functions, even in the face of moderate damage [3]. Liver disease ranks as the third leading disease related

Corresponding Author: Damilola Alex Omoboyowa, Biochemistry Research Unit, Department of Science Laboratory Technology, Akanu Ibiam Federal Polytechnic, Afikpo, Ebonyi State, Nigeria. Tel.: +2347032665874.

cause of death for many people of ages 25 to 59 particularly common liver disorders include hepatitis and cirrhosis. It is generally believed that liver damage follows a spectrum, progressing from inflammation and swelling to fatty degeneration, cirrhosis and cancer. Since the liver can still function with up to 80% deterioration, symptoms are often vague and may not be noticed until damage is severe. When symptoms and signs manifest, they may include dinginess in the whites of the eyes, Jaundice, pale stools, pain on the right side or under right shoulder blade, loss of appetite, digestive disturbances, a metallic taste in the mouth, frontal headache and drowsiness after meals intolerance fatty foods and energy loss [2].

Many drugs of biological origin, most importantly those from plant origin are undergoing several clinical trials and investigations in order to ascertain their medicinal potentials. It has been observed that many plants contain a variety of substances, which have appreciable physiological and pharmacological actions on man and animals. Traditional herbalist uses the extracts of most plants with pharmaceutical importance to treat some hepatic damage [4]. *Citrullus lanatus* of family Cucurbitaceae is commonly known as water melon. Water melon is thought to have originated in Southern African because it is found growing wild through the area. It has been cultivated in African for over 4,000 years. *Citrullus lanatus* was brought to American by Spanish and quickly became a very popular crop [5]. Most of the health benefits observed in people that utilizes *Citrullus lanatus* (Water melon) plants for the management of many ailments is attributed to their numerous pharmacological and medicinal properties. This study aimed at understanding the biochemical, pharmacological and toxicological effects of the extracts of *Citrullus lanatus* seeds in hepatotoxic rats.

MATERIALS AND METHODS

Plant Material: Water melon (*Citrullus lanatus*) seed used for this study was collected from Eke market, Afikpo north Local Government Area, Ebonyi State, Nigeria. It was authenticated at the botany unit of the Department of Science Laboratory Technology, Akanu Ibiam Federal Polytechnic, Unwana, Ebonyi state, Nigeria where a voucher specimen with voucher number V/No. 2001602 has been deposited. The seeds of the plant were harvested with a sterilized knife, air dried at room temperature for three (3) weeks, ground with a mechanical blender to a coarse form, extracted with methanol and fix-dried.

Extraction Procedure: Exactly 568.5 g of dried ground sample of *Citrullus lanatus* seed were macerated with 1400 ml of analytically graded methanol for 72 hours with occasional stirring using a stirring rod. The extract was sieved using a fine sieving cloth. The filtrate was passed through Whatman No 4 filter paper, concentrated by rotary evaporator and dried at room temperature.

Method of Induction of Liver Damage: The minimum dose of paracetamol that causes death in rats is 1060 mg/kg and the median dose (LD₅₀) is 765 mg/kg [6, 7]. Paracetamol hepatotoxicity was induced by single administration of solution of paracetamol at 750 mg/kg b. w. orally. After 4 days of administration, only rats with AST levels above 65 U/l were considered hepatotoxic and used for the study.

Experimental Design: A total of twenty male albino rats weighing between 180-220 g were used for the study, the rats were obtained from the Faculty of Veterinary Medicine, University of Nigeria, Nsukka, Nigeria. The animals were used according to the NIH animal care guidelines with approval of the Departmental Animal Committee (AIFP/AFK-EB/1-07). They were acclimatized for seven days in the Department of Science laboratory technology animal house with regular feeding and water *ad libitum*. The rats were divided into five different groups with four animals per group (n=4):

- Group I: Negative control
- Group II: Positive control (Acetaminophen exposed).
- Group III: Acetaminophen challenged + 25 mg/kg body weight of silymarin
- Group IV: Acetaminophen challenged + 200mg/kg body weight of the extract.
- Group V: Acetaminophen challenged + 400mg/kg body weight of the extract.

Acute Toxicity and Lethality (LD50) Test: The acute toxicity and lethality of methanol extract of the *Citrullus lanatus* was determined using the modified method of Lorke [8]. The test was divided into two stages. In stage one, nine (9) randomly selected adult mice were divided into three groups, three per group (n=3) and received 10, 100 and 1000 mg/kg body weight of the methanol extract and the signs of toxicity and number of deaths for a period of 24-hours were recorded. After 24 - hour observation, the doses for the second phase were determined based on the outcome of the first

phase. Since there was zero death, a fresh batch of animals were used following the same procedure in phase I but with higher dose ranges of 1900, 2600 and 5000 mg/kg body weight of the extract. The animals were also observed for 24-hours for signs of toxicity and possible number of deaths. The LD50 was calculated as the geometric mean of the high non-lethal dose and lowest lethal dose [8].

Phytochemical Test: Basic quantitative phytochemical screening of the methanol extract of the *Citrullus lanatus* seed sample was carried out by testing for the concentration of the following plant constituents: flavonoids, tannins, saponins, steroids, alkaloids, reducing sugar, cyanogenic glycosides and soluble carbohydrate. The phytochemical analysis of the sample was carried out using procedures outlined by Harborne [9] and Pearson [10].

Biochemical Assay: The activity of aminotransferase (AST and ALT) was determined by the method of Reitman and Frankel [11]. Plasma alkaline phosphatase activity was assayed spectrophotometrically according to the method described by King and King [12]. The concentration of bilirubin was determined by the method of Mallony and Evelyn [13] as described in Randox assay kits.

Liver Histology: The animals were sacrificed after 7 days of treatment and the abdominal cavity of each rat opened, the liver taken out. The organ was fixed in 10% formalin. After complete fixation the blocks was embedded in paraffin and sections cut at 5µm (Micron) which was then stained with haematoxylin and eosin and mounted in Canada balsam. Microscopic examination of the sections was then carried out under a light microscope [14].

Statistical Analysis: The data obtained was analyzed using One Way Analysis of Variance. The data was further subjected to LSD post hoc test for multiple comparisons and differences between Means regarded significant at $P < 0.05$. The results were expressed as Mean \pm SEM.

RESULTS

Yield of the Methanol Extract of *Citrullus lanatus* Seed: The yield for the extract was 25.7 g (4.52%).

Acute Toxicity and Lethality (LD50) Test: Intraperitoneal administration of up to 5000 mg/kg body weight of methanol extract of *Citrullus lanatus* seed to mice caused no death in the two stages of the test. Thus, the intraperitoneal LD₅₀ of methanol extract in the mice was estimated to be greater than 5000 mg/kg body weight.

Phytochemical Test: Results of the quantitative phytochemical components analysis of methanol extract of *Citrullus lanatus* seed (Table 1) showed presence of alkaloids, flavonoids, soluble carbohydrate, tannins and steroids. The results indicated the relative abundance as: alkaloids > steroids > terpenoids > flavonoids > saponins > tannins > phenol.

Table 1: Quantitative Phytochemical Composition of Methanol extract of *Citrullus lanatus* Seed

phytochemical Compounds	Quantity (mg/100g)
Saponins	1.333 \pm 0.0071
Tannins	0.536 \pm 0.057
Alkaloids	33.795 \pm 0.0071
Steroids	2.458 \pm 0.0099
Terpenoids	2.415 \pm 0.0071
Flavonoids	2.310 \pm 0.014
Phenol	1.371 \pm 0.042
Cyanogenic glycosides	0.00325 \pm 0.00035

Data represented in Mean \pm SEM

Effect of Methanol Extract of *Citrullus lanatus* Seed on Liver Function Parameters of Acetaminophen Intoxicated Rats: As shown in Table 2, there was non-significant ($P > 0.05$) increase in AST & ALT activities and total bilirubin level of hepatic damaged rats administered 0.5 ml of distilled water compared with normal control rats. The ALP level of rats in group II increased non-significantly ($P > 0.05$) compared with the normal control rats. Hepatic damaged rats administered 200 and 400 mg/kg b. w. of the plant extract showed non-significant ($P < 0.05$) decrease in ALT activity compared with the hepatic damaged rats administered 0.5 ml of distilled water. The animals exposed to paracetamol and treated with silymarin and varying dose of the extract showed non-significant ($P > 0.05$) decrease in the AST and ALT activities compared with the paracetamol exposed animals administered 0.3 ml of distilled water. The animals in group IV administered 400 mg/kg b. w of the extract showed non-significant ($P > 0.05$) decrease in AST and ALT activity compared with group III rats treated with 200 mg/kg b. w of the extract after hepatic damage (Table 2).

Table 2: Effect of methanol Extract of *Citrullus lanatus* Seed on Liver Function Parameters of acetaminophen intoxicated rats

Group	Treatment	AST (IU/l)	ALT (IU/l)	ALP (IU/l)	T.BIL (mg/dl)
I	Normal Control	34.25 ± 4.75	11.82 ± 1.22	40.82 ± 2.79	7.07 ± 1.52
II	Hepatic damage administered 0.3 ml of distilled water	54.00 ± 7.67	17.85 ± 1.70	36.08 ± 2.86	11.23 ± 3.82
III	Hepatic damage administered 25 mg/kg b. w. of silymarin	51.50 ± 3.94	15.33 ± 1.76	29.33 ± 1.20*	5.33 ± 0.19*
IV	Hepatic damage treated with 200 mg/kg b. w. of extract	51.50 ± 8.63	15.67 ± 2.97	29.43 ± 0.88*	13.60 ± 1.33*
V	Hepatic damage treated with 400 mg/kg b. w. of extract	48.00 ± 3.74	14.15 ± 2.70	30.48 ± 0.89*	20.93 ± 1.86*

n = 4; *P<0.05 compared with the control (one way ANOVA; LSD post hoc test); values represented in Mean ± SEM

Results of the Liver Histology:

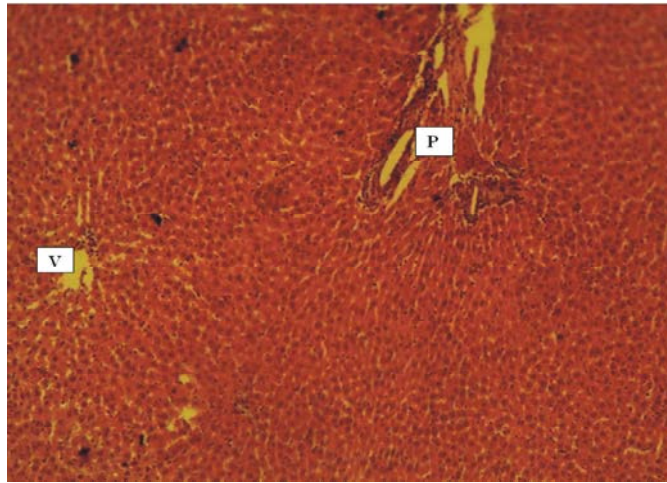


Fig. 1: Photomicrograph of the section of the liver showing normal hepatocytes (Black arrow) arranged in radiating chords, around the central vein (V), Portal area (P) (H&EX100). Sections of the liver histoarchitecture of the Rats in the control group that were given distilled water without paracetamol administration. Liver from this group showed normal hepatic histoarchitecture, it showed normal hepatocytes arranged in radiating chords around the central veins, diverging towards the portal areas with normal bile ducts, hepatic arteries and hepatic veins.

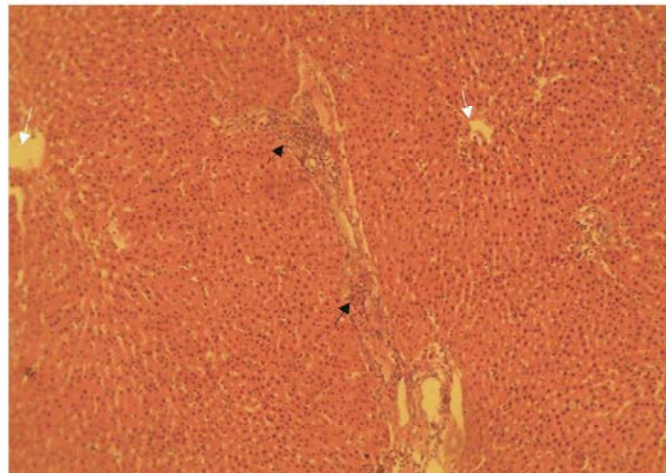


Fig. 2: Section of the liver histoarchitecture of the Rats administered with acetaminophen, treated with 25 mg/kg b.w of silymarin. Sections of the liver from this group revealed a mild to moderate hepatitis. Like the others, normal lobular outlines with individual lobules showing normal hepatocytes arranged in interconnecting chords were observed. At the periphery of most of the lobules mild to moderate aggregations of mononuclear leukocytes were observed. Also multifocal areas of coagulative necrosis with mild infiltrations of mononuclear leukocytes were observed. Central vein (White arrow). (H&Ex100).

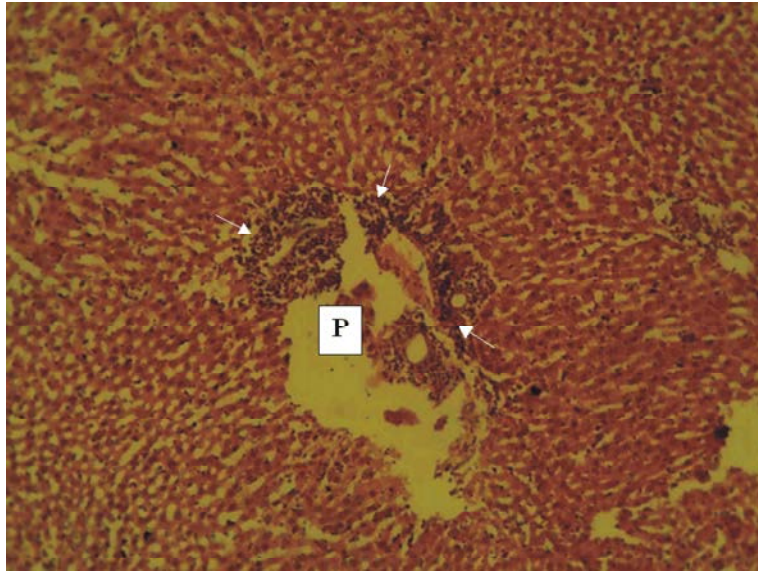


Fig. 3: A photomicrograph of liver showing a severe infiltration of mononuclear leucocytes (Arrows) around the portal area (P) (H&E X 100). Sections of the liver histoarchitecture of the rats that were given distilled water after paracetamol administration. Sections of the liver from this group showed multiple, mild to moderate, periportal infiltration of mononuclear leucocytes (Primarily lymphocytes and macrophages). A few random aggregates of these mononuclear cells were also observed.

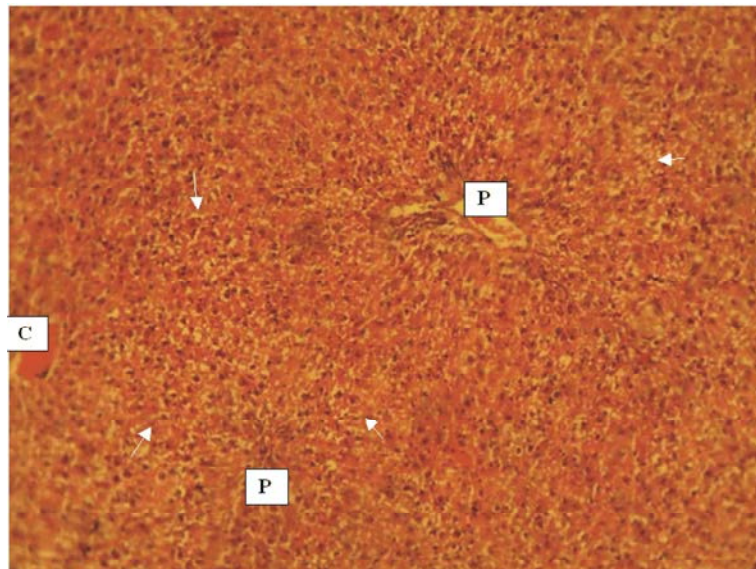


Fig. 4: A photomicrograph of the liver showing cytoplasmic vacuolation in the hepatocytes around the portal triad (Arrow). Portal area (P), sinusoids (White arrow) (H & EX400). Sections of the liver histoarchitecture of the rats that were treated with 200 mg/kg body weight of methanol extract of *Citrullus lanatus* seed after high dose of paracetamol (750 mg/kg b.w) administration. Section of the liver from this rat showed a severe hepatocellular vacuolar degeneration of the periportal and mid-zonal hepatocytes. Also, some sections showed a moderate infiltration of mononuclear leucocytes which are comprised primarily of lymphocytes and macrophages. Occasionally, the vacuolar hepatocellular degeneration shows a pan lobular distribution.

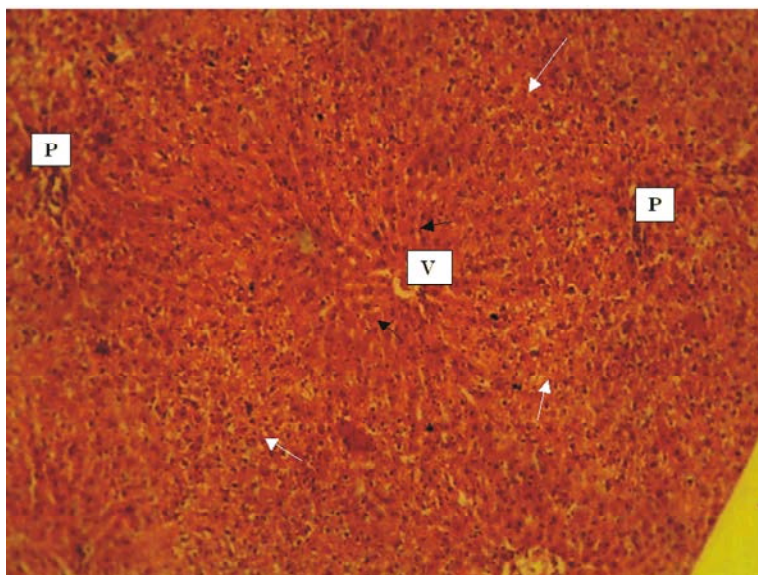


Fig. 5: A photomicrograph of the liver showing a mild to moderate cytoplasmic vacuolation of the periportal hepatocytes (Arrow). Central vein (V), Portal area (P) (H&EX100). Section of the liver histoarchitecture of the rats that were treated with 400 mg/kg body weight of methanol extract of *Citrullus lanatus* seed after high dose of paracetamol (750 mg/kg b.w) administration. Section from this rat showed a severe widespread hepatocellular vacuolar degeneration. This observed degenerative change tend to be primarily of periportal pattern. However, pan lobular hepatocellular degenerative pattern is observed.

DISCUSSIONS

The liver is an organ of paramount importance which plays an essential role in the metabolism of foreign compounds entering the body. Human beings are exposed to these compounds through environmental exposure, consumption of contaminated food or during exposure to chemical substances in the occupational environment. In addition, human beings consume a lot of synthetic drugs during disease conditions which are alien to body organs. All these compounds produce a variety of toxic manifestations [7, 15].

The liver gets damaged after high dose of paracetamol which produces hepatotoxicity; it leads to leakage of cellular enzymes into the plasma [16]. The increased level of serum enzymes such as ALT & AST activities and total bilirubin observed in hepatotoxic rats are indicator of liver damage, increased permeability and necrosis of the hepatocytes [17]. The significant ($P < 0.05$) increase observed in the level of plasma aminotransferase activities (AST and ALT) in high dose paracetamol treated rats compared with the normal rats in this study could be due to hepatocellular damage because these enzymes are normally located in the cytoplasm and released into the circulation at high concentration after cellular damage [7]. The result from the phytochemical

studies of the methanol extract of *C. lanatus* seed indicated the presence of terpenoids, alkaloids and flavonoids that may play a role in plant extract metabolism. The reduction in AST and ALT activities by high dose of the extract may suggest repairing of the rats' liver by *C. lanatus* seed extract. This may be ascribed to the bioactive compounds present in *C. lanatus* which could have possibly increase the levels of glutathione which binds to the toxic metabolites of paracetamol such as N-acetyl-p-benzoquinone imine (NAPQ1) and increased its rate of metabolism and excretion from the body system. It might also result in inhibition of cytochrome P-450 enzyme system which decreased the formation of NAPQ1 from ingested paracetamol [18]

The elevation in total plasma bilirubin observed in paracetamol hepatotoxic rats suggested abnormal conjugation of bilirubin by the liver due to generalized hepatocellular damage [19]. Total plasma total bilirubin was decreased in paracetamol hepatotoxic rats after treated with the standard drug (Silymarin). The possible mechanism of action of *C. lanatus* extract may be through their anti-oxidative effect. This is because *C. lanatus* possesses bioactive compounds that are capable of free radical scavenging in living system [20]. The results obtained in this study are consistent with the findings of Omoboyowa *et al.* [7].

The primary histopathological change observed in this case was vacuolar degeneration of the hepatocytes. This lesion varied in its distribution from periportal to mid-zonal and pan-lobular across the groups. The control group showed normal hepatic micro-architecture, the group treated with paracetamol only, showed a severe periportal infiltration of inflammatory leucocytes without evident degenerative change in the hepatocytes. This is not consistent with the commonly reported paracetamol induced hepatocellular damage (Incomplete induction of liver damage or poor tissue collection for histopathology). The other slides from the groups treated with the test extracts showed changes in the hepatic histoarchitecture which are consistent with paracetamol induced hepatic damage. For the group treated with *Citrullus lanatus*, the high dose group (400 mg/kg) showed a much milder lesion (Periportal vacuolar degeneration of the hepatocytes) than those treated with the low dose (200 mg/kg) which showed a much severe lesion (Periportal and mid zonal vacuolar degeneration of the hepatocytes). This could mean that the group exposed to the higher dose exerted a more hepatoprotective effect on the liver than the low dose.

CONCLUSIONS

The results demonstrated that *Citrullus lanatus* seed acted as anti-hepatotoxic agent because of the significant ($P < 0.05$) reduction in the elevated level of plasma liver enzyme activity in the rats exposed to paracetamol. The observed anti-hepatotoxic activity might be linked with the presence of flavonoids, alkaloids and other bioactive compounds in the plants.

ACKNOWLEDGEMENT

The authors wish to acknowledge the Technologists at the Biochemistry laboratory, Department of Science Laboratory Technology, Akanu Ibiam Federal Polytechnic, Unwana, Ebonyi State for their assistance in the laboratory experiment. We also wish to appreciate the effort of Dr. Ezeasor of Department of Veterinary Medicine, University of Nigeria, Nsukka, for the interpretation of the Liver histology.

REFERENCES

1. Maton, A., H. Jean, W.M. Charles, J. Susan, Q. Mayama, L. David and D. Jill, 1993. Human biology and health. Eaglewood cliffs, New Jersey, USA: Prentice Hall, pp: 32-33.

2. Sarojini, T.R., 1990. Liver function. Modern biology for senior secondary school (3rd ed.). African first publisher Limited Onitsha, Nigeria, pp: 288-289.
3. Murray, R.K., D.K. Grammar, P.A. Mayers and V.W. Rodwel, 2003. Harper's Biochemistry. 26th ed. McGraw Publishers, New York, pp: 234-242.
4. O'Shea, R.S. and A.J. Mc-Cullough, 2005. Treatment of alcoholic hepatitis. Clin. liver Dis., 9: 103-134.
5. Collins, J.K., G. Wu, P. Perkins-veazie and K. Spears, 2007. Watermelon consumption increases plasma arginine concentration in adult. Nutrition, 23: 261-266.
6. Boyd, E.M. and S.E. Hogan, 1968. The chronic oral toxicity of paracetamol at the range of the LD₅₀ (100 days) in albino rats. Can. J. Physiol. Pharmacol., 46: 239-245.
7. Omoboyowa, D.A., N.A. Obasi, G. Otuchristian, G.J. Danladi and M.U. Okon, 2016. Protective effect of methanol stem bark extract of *Cocos nucifera* on paracetamol-induced hepatotoxicity in adult wistar rats. International Journal of Tropical Disease & Health, 11(4): 1-10.
8. Lorke, D., 1983. A new approach to practical acute toxicity testing. Arch. Tox., 53: 275-280.
9. Harborne, J.B., 1984. Phytochemical methods. A guide to modern technique of plant analysis. Chapman and Hall. London., pp: 54-60.
10. Pearson, D., 1976. The chemical analyses of food. 7th Edition. London, Churchill Living Stone, pp: 3-4.
11. Reitman, S. and R. Frankle, 1957. Colorimetric method for the determination of serum transaminases. Am. J. Clin. Pathol., 28: 56-61.
12. King, P.R. and E.J. King, 1984. Estimation of alkaline phosphatase. J. Clin. Pathol., 7: 251-271.
13. Mallory, H.T. and K.A. Evelyn, 1973. The determination of bilirubin with the photometric colorimeter. J. Biol. Chem., 199: 481-490.
14. Ogunneye, A.L., D.A. Omoboyowa, O.O. Banjoko and H. Adetokunbo, 2014. Effect of sub-chronic Lamivudine-Quinine co-administration on the liver of normal adult wistar rats. Int. J. Pharm. Sci. Rev. Res., 24(2): 345-350.
15. Athar, M., S. Hussain and N. Hassan, 1997. Drug metabolizing enzymes in the liver in Rona, S. V. S, Taketa, K, Editors. Liver and environmental Xenobiotics. New Delhi: Narosa Publishing House, pp: 53-61.
16. Baldi, E., P. Burra, M. Plebani and M. Salvagnini, 1993. Serum Malodialdehyde and mitochondrial aspartate aminotransferase activity as markers of chronic alcohol intake and alcoholic liver disease. Italian J. Gastro., 25: 429-432.

17. Goldberg, D.M. and C. Watt, 1965. Serum enzyme changes as evidence of liver reaction to oral alcohol. *Gastroentero.*, 49: 256-261.
18. Franciscus, A., P. Fener and C.D. Mazoff, 2007. Hepatitis C support project: www.hcadvocate.org. San Francisco, pp: 941-94.
19. El-Sherbiny, E.A., G.A. Abdul-Allah and S.T. Goneim, 2003. Relationship of liver function tests to different stages of chronic liver diseases in HCV carriers. *J. Egypt. Soc. Zool.*, 40: 71-93.
20. Mitra, S.K., M.V. Venkataranganna, R. Sundaran and S. Gopumadhavan, 1998. Effects of HD-0₃, a herbal formulation, on the antioxidant defense system in rats. *Phytother. Res.*, 12: 114-117.