

Experimental Infection with BVD Virus in Pregnant Does with Emphasis on Pathological and Hormonal Changes

¹H.M. Desouky, ¹A.A. Younis, S.A. ¹Shalaby and ²A. Hegazy

¹Department of Animal Reproduction & AI, National Research Centre, Postal Code: 12622, Giza, Egypt

²Department of Pathology, Faculty of Veterinary Medicine, Cairo University, Giza, Egypt

Abstract: Nine healthy pregnant does free from BVD neutralizing antibodies were I/V and I/P inoculated with two cytopathic strains of BVD virus (NADL-camel) at about 65 days of gestation. In NADL strain of BVDV group, abortion occurred in 3 out of 5 virus inoculated does on 7, 17 and 21 days post inoculation (PI). The mean serum progesterone values of pregnant does significantly decreased on days 7(P<0.01) and 14(P<0.05) PI. In camel strain of BVDV group, 1 of 4 aborted on day 65 PI. The progesterone values significantly decreased on 14(P<0.05), 21-42(P<0.01) and 49-70(P<0.05) days PI. The microscopical examination of placenta of aborted does revealed focal areas of necrosis associated with calcification of both cells of layer chorioallantoic villi. Meanwhile, the uterus of aborted does showed intensive aggregation of neutrophils in decidua basalis of endometrium. Moreover, ovaries of aborted cases displayed luteolytic changes of almost lutein cells of corpora lutea. Multiple interstitial foci of lymphocytic cell aggregation, associated with intraluminal accumulation of leukocytes mainly neutrophils was seen in mammary gland. The immunofluorescent results revealed presence of viral antigen in the tissue of placenta and spleen. On the other hand, the histopathological picture of reproductive organs of camel strain of BVDV was similar to that of NADL strain group, but was somewhat mild in severity. It could be concluded that goats are susceptible to BVD virus infection. Also, BVD virus had adverse effects on reproductive performance of goats. Immunofluorescent technique is a valuable and confirmative tool in diagnosis of BVD virus infection.

Key words: Abortion • Bovine viral diarrhea virus • Goats • Histopathology • Immunofluorescence

INTRODUCTION

Recently, BVD virus had attracted increasing attention because of its severe economic losses among the livestock industry, whereas transplacental infection during pregnancy leads to fetal infection and abortion [1]. BVD virus and ovine border disease BD virus are both members of the genus pestivirus in family Togaviridae and are closely antigenically related. Ovine as well as bovine pestivirus strains can cross infect sheep, cattle and also goats [2 - 4]. In goats, serological surveys in different countries showed widespread of neutralizing antibodies against pestivirus in Norway [5], Austria [6], USA [7] and India [8]. Moreover, experimental studies on BVD virus in pregnant goats [3, 4, 7, 9-12] have emphasized the importance of pestivirus as a cause of caprine reproductive failure and have also indicated that pestivirus infection in goats might have characteristics in

common with those in sheep, but seemed to have a more severe fetopathogenic effects in goats. Therefore, the present work aimed to clarifying the susceptibility and pathological profile of pregnant does to experimental infection with BVD virus of bovine and camel origin.

MATERIALS AND METHODS

Animals: The present work was carried out on 13 healthy pregnant does which were free from BVD virus neutralizing antibodies, brucella and parasitic infestation. Their ages ranged from 12-24 months old and body weight ranged from 18-20 Kg.

Virus Inoculum: Two cytopathic strains of BVD virus were kindly obtained from the Department of Virology, Faculty of Veterinary Medicine, Cairo University.

- National Animal Disease Laboratory (NADL) strain of BVD virus of bovine origin. The titre of this strain was 10^9 tissue culture infective dose (TCID₅₀) per ml.
- Camel strain of BVD virus. The titre of this strain was 10^{11} tissue culture infective dose (TCID₅₀) per ml.

Both strains of BVD virus were propagated and titrated in Madin-Darby bovine kidney cell line (MDBK).

Experimental Design

The Animals Were Allocated into Three Groups:

- Group I included 5 animals, each doe was inoculated with 10ml {5ml I/V and 5ml I/P} of tissue culture suspension of NADL strain containing 10^9 TCID₅₀ per ml at about 65 days of gestation.
- Group II comprised 4 animals; each doe was inoculated with 10ml {5ml I/V and 5ml I/P} of tissue culture suspension of camel strain containing 10^{11} TCID₅₀ per ml at about 65 days of gestation.
- Group III consisted of 4 animals which kept non infected along the whole period of experimental work and served as control.

Following inoculation; pregnant does were kept under daily observation throughout experimental period for any clinical manifestations. Also, all animals were penned separately and kept at the same managerial conditions and under complete quarantine and preventive measures.

Collection of Blood Sample: Blood samples were aseptically collected through jugular vein puncture at day after days during the first PI, followed by weekly sampling from pregnant goats till kidding. Serum samples were harvested by centrifugation at 3000 rpm for 10 min. and kept frozen at -20°C till used for serological test and evaluation of progesterone level.

Hormonal Assay: Progesterone level in the serum of pregnant goats was determined by radioimmunoassay technique –coat A count procedure [13] using kits purchased from Diagnostic Product Corporation, Los Angeles, USA.

Fluorescent Microscopical Method: The direct immunofluorescent antibody technique was adopted by Goldman [14] as rapid confirmatory method to detect the topographical distribution of BVD virus within the tissues.

Histopathological Study: Tissue samples from placenta, uterus, ovaries, mammary gland and spleen were taken from pregnant does after slaughtering. These tissues were washed, dehydrated by alcohol, cleared in benzene and embedded in paraffin. Tissues were sectioned at 5μ thickness and stained with H&E for histopathological examination.

Statistical Analysis: Data were statistically analyzed according to Snedecor and Cochran [15].

RESULTS

Reproductive Performance of Pregnant Goats Inoculated with Either NADL or Camel Strain of BVD Virus Is Summarized in Table (1): In NADL strain of BVDv group, abortion occurred in 3 of 4 does inoculated with virus at 7, 17 and 21 days PI with the virus at day 65 of gestation. The first doe aborted twin fetuses 7 days PI, one of both was dehydrated, partially mummified, while the other fetus had mild generalized anasarca. The aborted case in second doe was missed and the dam was sacrificed 17 days PI, however the uterus showed red spots on surface of uterine mucosa. Also, the histopathological examination of uterus revealed endometrial changes suggestive pregnancy associated with presence of corpora lutea in both ovaries. It is noteworthy that progesterone values of this case were 9.45, 9.51, 7.45, 8.66 and 8.0 ng/ml at 1, 3, 5, 7 and 14 days post inoculation of virus, respectively. Meanwhile, on day 17, the progesterone value was sharply dropped to 0.302 ng/ml. The third doe aborted one fetus 21 day PI the aborted fetus had crown-rump length about 7 cm and showed subcutaneous edema and scattered areas of hemorrhages particularly on poll and shoulder. There were advanced organ analysis and excess of blood stained fluid in all body cavities. The fourth doe delivered at full term a twin kids, one was clinically healthy with body weight 1,300g and crown rump length 30cm. the other one died within 4hrs post kidding (Perinatal death). This kid was noticeably weak, unable to stand and undersized body weight 850g and crown –rump length 29.5cm. Moreover, the kid showed varying degrees of body tremors and apparently respiratory distress. Post mortem examination revealed thymic hypoplasia associated with presence of petechial hemorrhages. Mesenteric lymph nodes and Peyer's patches were congested and haemorrhagic. The remaining doe from NADL strain group of BVD virus gave birth to full term kid. The post mortem examination showed haemorrhagic and edematous prescapular L.N. of right side in addition to mesenteric L.N.

Table 1: Reproductive performance of pregnant goats inoculated with either camel or NADL strain of BVDV

Group	Gestation length/days at time of inoculation	Virus inoculations**			No. of aborted goats	Time of abortion (days)
		Strain	Amount (TCID ₅₀)	No. of goats per group		
I	65	NADL	10 ⁹	5	3	72, less than 82*, 86
II	65	Camel	10 ¹¹	4	1	130
III	-	-	-	4	-	-

* Missed abortion

** All inoculations were done simultaneously by intravenous and intraperitoneal routes.

Table 2: Mean values \pm SE of birth weights (kg) and crown-rump lengths (cm) of affected and control kids

Newly born kids Parameters	Kids born to control does	Kids born to does inoculated with camel strain of BVDV	Kids born to does inoculated with NADL strain of BVDV
Birth weight (kg)	1.950 \pm 0.08	1.940 \pm 0.12	1.075 \pm 0.13**
Crown-rump length (cm)	35.3 \pm 0.68	34.7 \pm 0.88	29.8 \pm 0.14**

** Significant at P<0.01

Table 3: Serum progesterone profile (ng/ml) of pregnant goat following inoculation with either camel or NADL strain of BVD virus on the 65th day of gestation

Days post inoculation	Control group	Camel strain of BVDV group	NADL strain of BVDV group
1	9.1 \pm 1.5	8.0 \pm 0.68	9.9 \pm 1.6
3	9.0 \pm 1.4	7.3 \pm 0.29	8.9 \pm 0.56
5	9.2 \pm 1.5	7.3 \pm 1.2	7.1 \pm 1.1
7	9.4 \pm 0.4	7.2 \pm 0.93	6.6 \pm 0.57**
14	9.9 \pm 0.86	6.9 \pm 0.72*	6.1 \pm 1.2*
21-42 @	10.2 \pm 0.44	7.9 \pm 0.55**	
49-70 @	11.4 \pm 0.53	9.3 \pm 0.94*	

* Significant at P<0.05 ** Significant at P<0.01

Mean value \pm S.E.

@ the values represent the mean of 4 successive analysis at weekly interval

In camel strain of BVD virus group, one of four goats that received the virus at 65 days of gestation, aborted one fetus at 65 days PI of virus. The aborted fetus was small in size and severely autolysed and was obviously dead in uterus for long period. Meanwhile, the macroscopical examination of this kid showed no consistent gross lesions except for congestion of meninges. The mean values of body weight and crown-rump length of live born kids were 1.940 \pm 0.12 Kg and 34.7 \pm 0.88 Cm, respectively. These values were more or less similar to control vales as shown in Table 2.

In control group, the four does gave birth at full term to 6 kids all of which were normal, viable and clinically healthy with mean values of body weight 1.950 \pm 0.08Kg and mean values of crown – rump length 35.3 \pm 0.68 Cm.

Progesterone Level: The changes in mean serum progesterone values of pregnant goats inoculated with either NADL strain or camel of BVD virus are shown in Table 3. The mean serum progesterone value (ng/ml) of pregnant does inoculated with NADL strain of BVD

virus revealed significant decrease on days 7 (P<0.01) and 14(P<0.05) PI. Abortion occurred in 3 out of 5 does at 7, 17 and 21 PI. The progesterone values of these cases sharply dropped to 0.064, 0.302 and 0.047ng/ml ,respectively following abortion. On the other hand, the mean serum progesterone value (ng/ml) of pregnant does inoculated with camel strain of BVD virus showed a significant decrease at 14(P<0.05), 21-42(P<0.01) and 49-70 (P<0.05) days PI , associated with abortion in one of four does, at 65 days PI. The progesterone value of this case was abruptly dropped to zero ng/mg following abortion.

Histopathological Findings

Uterus and Placenta: The microscopical examination of uterus of normal kidding does revealed partial desquamation of the epithelium lining of endometrium associated with extensive accumulation of inflammatory cells mainly neutrophils in the endometrial stroma. Meanwhile, the uterus of aborted does of NADL strain of BVDv group showed intensive aggregations of neutrophils in deciduas basalis of endometrium

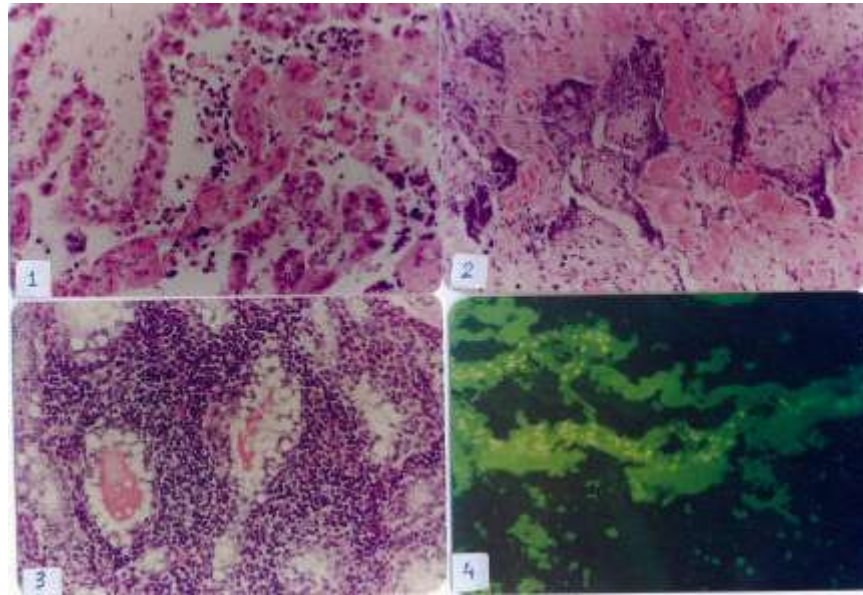


Fig. 1-4: 1: Placenta, showing necrosis and desquamation of epithelium cell covering of chorioallantoic villi, cellular debris, inflammatory cells, calcified foci of necrotic trophoblast cell within the caruncular crypts (H&E stain, X400).
2: Placenta, showing focal areas of necrosis associated with calcification of chorioallantoic villi (H&E stain, X250).
3: Mammary gland, showing multiple interstitial foci of lymphocytic cell aggregation among secretory acini (H&E stain, X250).
4: Placenta, showing positive fluorescent reaction in the epithelial lining of chorio allantoic villi. DIF stain, X250.

associated with endometrial oedema and mild periglandular accumulations of neutrophils. Meanwhile, the placenta showed myxomatous degeneration of almost chorioallantoic villi. Moreover, some villi revealed hydropic mole or degeneration (Hydatiform mole). There were necrosis and desquamation of epithelial cell covering of chorioallantoic villi. In caruncular crypts, fibrinonecrotic cellular debris, inflammatory cells, hemorrhages and calcified foci of necrotic trophoblast cells were seen (Fig. 1). Focal areas of necrosis associated with calcification of chorioallantoic villi were observed (Fig. 2). The maternal blood capillaries were thrombosed accompanied with necrosis of caruncular septal stroma and mild mineral deposition. In camel strain, the microscopic examination of placenta of normal kidding does showed mild to moderate degenerative changes of chorioallantoic villi associated with presence of inflammatory cells mainly neutrophils, on the other hand, fibrinoid necrosis and intensive calcification of chorioallantoic villi were seen in placenta of aborted fetus, in addition to presence of excessive aggregation of neutrophils, lymphocytes and macrophages in decidua basalis of endometrium.

Ovaries of aborted does displayed luteolytic changes of almost lutein cells of regressed corpora lutea in addition to mild proliferation of spindle cells and focal aggregations of neutrophils in between the lutein cells were observed.

Mammary Glands: This organ showed multiple interstitial foci of lymphocytic cell aggregation (Fig. 3), in addition to intraluminal accumulation of leukocytes mainly neutrophils was seen. In camel strain, similar results were found in one case; meanwhile the other three cases appeared within normal limit.

Spleen: It revealed marked depletion of lymphoid tissue in external zone of Malpighian corpuscles, in addition to lymphocytes appeared smaller and pyknotic. The red pulp was extensively infiltrated with neutrophils aggregation particularly around the lymphoid follicles. In camel strain, similar results were seen in 2 cases out of 4 in addition to presence of multiple foci of haemosiderosis within the red pulp.

Immunofluorescent Results: Placental tissue showed moderate intensity of specific fluorescent reaction in the epithelial cell lining of chorioallantoic villi (Fig. 4). Also, antigen was detected in few scattered small round cells in the maternal tissue. No specific fluorescent reaction could be seen in ovaries including those of aborted does. In spleen, antigen was identified in small round (lymphocytes) in white pulp. Also, the antigen was detected in few scattered macrophages in the red pulp.

DISCUSSION

The present work was carried out to clarify the pathogenesis of BVDV in the pregnant does particularly its effect on reproductive performance.

Inoculation of pregnant does with NADL resulted in early abortion in 3 out of 5 does at 7, 17, 21 days PI and late abortion in one doe inoculated with camel strain at 65 days PI. These findings were previously recorded on BVD in sheep [16 – 20] and goats [3, 4, 9-11]. In this respect, Barlow *et al.* [21] stated that the high frequency of fetal death and abortion in infected goats with border disease virus was due acute placentitis. This concept was supported by observations of Snowdon *et al.* [16] who reported that placentomes appeared to be the organ of choice for multiplication and persistence of BVD virus and highest concentration of virus was recovered from placentomes and fetal membranes. Parsonson *et al.* [17] added that the highest level of BVD virus in placentomes and fetal tissues occurred between 9 and 15 days after inoculation and fetal fluid between 11 and 18 days post inoculation. Moreover, Hewicker-Trautwein *et al.* [22] reported that BVD virus present longer in the allantoic fluid in fetal tissues and continued to be present in placentomes despite the presence of neutralizing antibodies in the circulation of does. Recently, Broaddus *et al.* [4] noticed that BVD virus antigen in placentomes of goats from 7 to 36 days PI and in fetal fluids and tissues from 10 to 28 days PI accompanied by severe ulcerative placentitis. Thus the pathogenicity of the virus may be related to its ability to multiply in the placentomes and bring about pathological changes resulting in fetal death. The histopathological examination of aborted placenta in current work revealed necrosis and desquamation of epithelial cell covering of chorioallantoic villi associated calcification in addition to accumulation of cellular debris, inflammatory cells within the caruncular crypts. These results were in agreement with previous recorded findings [1, 4, 16, 17]. These authors stated that fetal death result from loss of intimate contact between

the fetal and maternal placentomal layers due to thrombosis of blood capillaries of caruncles, hemorrhage, necrosis and inflammatory changes within the intercryptal villi with subsequent degenerative changes in the trophoblast cells and loss of chorionic epithelium. Murrar [23] concluded that non specific pathological changes associated with BVD infection in placenta may allow secondary opportunist pathogens to cross the fetal maternal barrier, thereby threatening the health of fetus and the physiological and endocrinological functions of placenta which maintain pregnancy.

It was noteworthy that immunofluorescent study revealed presence of antigen or specific fluorescent reaction in trophoblast cells of epithelium lining of chorioallantoic villi and in endothelial cells of some villi. Also, the antigen was detected in few scattered small round cells in maternal tissue. These findings were previously supported by many investigators [1, 17, 24]. Lamm *et al.* [1] indicated that the trophoblastic epithelium of cotyledonary villi and mononuclear infiltrate are capable of being infected with BVD virus. They added that placenta, heart, thymus and brain are the most reliable tissues for BVD virus antigen detection using immunohistochemistry (IHC) in aborted goat fetuses. It could be concluded from the histopathological findings of present work that early changes were presented in the form of vasculitis as well as degenerative changes of trophoblast cells. By progressive changes of lesions the physiological functions of placenta were impaired leading to intrauterine deaths. However, the teratogenic effect of the virus on the fetus cannot be rolled out. On the other hand, the present study showed that mean serum progesterone value of pregnant does either inoculated with NADL or camel strain of BVD virus was significantly decreased. These results were in agreement with those of Carlsson *et al.* [19] in ewes, who also added that decrease of progesterone was associated with higher levels of prostaglandins that were risen only after or in connection with death of the fetus and during abortion, reflecting inflammatory and pathological processes around the dead fetus and in its placenta. In this respect, Fredriksson *et al.* [25, 26] reported that infectious processes in the uterus stimulate the production of prostaglandin with resultant higher circulating levels in plasma, with subsequent causing luteolysis of corpus luteum. It is well known that in goat corpus luteum alone is responsible for production of progesterone and is essential for maintenance of pregnancy during the entire gestation period, however, the life span of corpora luteum is not inherent and PGF₂ will terminate it and expulsion of dead fetus before term

can occur [27]. In bovine, the viral infection significantly decreased mean plasma progesterone concentrations between day 3 and day 11 after ovulation and non-cytopathogenic BVDV viraemias during the follicular phase can modulate the secretion of gonadotrophins and sex steroids, in particular progesterone by disrupting the capacity of the ovulatory follicle to form a competent corpus luteum [28].

The alterations in progesterone levels in the current work were in parallel line with the histopathological results of the ovaries of aborted does which revealed luteolytic changes of almost all lutein cells of regressed corpora lutea associated with focal aggregations of neutrophils among the lutein cells. However, mild ovaritis was observed in 2 does inoculated with NADL strain and in one doe inoculated with camel strain of BVD virus. In this respect, immunostaining of BVD virus antigen in luteal cells and macrophage-like cells was evident in ovaries from cows persistently infected with BVD virus and viral antigen was detected in macrophage-like cells and stromal cells in the ovarian cortex and oophoritis was evident from 6 to 60 days post acute infection [29, 30]. The effect of maternal exposure to BVD virus on fetal development at term revealed that mean values of body weight and crown-anus length of kids born to inoculated does with NADL strain of BVD virus were significantly decrease as compared with those of control ones. These findings are agreed with those previously obtained [17, 18] who reported that intrauterine growth retardation whether in form body weight, crown-anus length or selective stunting of vulnerable tissues or organs affected ovine or bovine fetuses was due to radiographically presence of multiple growth arrest lines in both long and around bones indicative of abnormal osteogenesis. The infection of thyroid and other organs of internal secretion may disturb the production of some hormones resulting in low birth weight and poor weight gains postnatally. Anderson *et al.* [31] found that affected lambs with border disease virus showed deficiency of thyroid hormones triiodothyronin (T3) and thyroxine (T4). It is suggested that these hormones may in turn affect the growth not only of affected fetus in utero, but metabolic perturbation and hormonal deficiency may extend for sometime after birth [32]. Moreover, Larsson *et al.* [33] mentioned that mean concentration of thyroxine (T4) and triiodothyronine (T3) were lower in the persistently or transiently infected BVD virus calves that appeared small for their age. Extensive placental necrosis that occurred in the present work may also cause impairment of fetal nutrition and temporary growth retardation.

Finally it could be concluded that goats are susceptible to BVD infection either with camel or NADL strain. BVD virus had an adverse effect on reproductive performance of goats. The pathological effects of NADL strain seemed to be more powerful than that of camel strain. Also; immunofluorescent technique has to be valuable and confirmative tool in diagnosis of BVD virus infection.

REFERENCES

1. Lamm, C.G., C.C. Broaddus and G.R. Holyoak, 2009. Distribution of bovine viral diarrhoea virus antigen in aborted fetal and neonatal goats by immunohistochemistry. *Vet. Pathol.*, 46: 54-8.
2. Barlow, R.M., J.C. Rennie and A.C. Gardiner, 1980. Infection of pregnant sheep with NADL strain of bovine virus diarrhoea virus and their subsequent challenge with border IIB Pool. *J. Comp. Path.*, 90: 67-72.
3. Loken, T. and I. Bjerkas, 1991. Experimental pestivirus infection in pregnant goats. *J. Comp. Path.*, 105: 123-140.
4. Broaddus, C.C., G. Lamm, S. Kapil, L. Dawson and G.R. Holyoak, 2009. Bovine viral diarrhoea virus in goats housed with persistently infected cattle. *Vet Path.*, 46: 45-53.
5. Løken, T., 1992. Pestivirus infections in ruminants in Norway. *Rev. Sci. Tech.*, 11: 895-9.
6. Krametter-Froetscher, R., A. Loitsch, H. Kohler, A. Schleiner, P. Schiefer, K. Moestl, F. Golja and W. Baumgartner, 2006. Prevalence of antibodies to pestiviruses in goats in Austria. *J. Vet. Med. B. Infect. Dis. Vet. Public Health*, 53: 48-50.
7. Nelson, D.D., M.J. Dark, D.S. Bradway, J.F. Ridpath, N. Call, J. Haruna, F.R. Rurangirwa and J.F. Evermann, 2008. Evidence for persistent Bovine viral diarrhoea virus infection in a captive mountain goat (*Oreamnos americanus*). *J. Vet. Diagn. Invest.*, 20: 752-759.
8. Mishra, N., K. Rajukumar, A. Tiwari, R.K. Nema, S.P. Behera, J.S. Satav and S.C. Dubey, 2009. Prevalence of Bovine viral diarrhoea virus (BVDV) antibodies among sheep and goats in India. *Trop. Anim. Health Prod.*, 41: 1231-1239.
9. Loken, T., 1987. Experimentally-induced border disease in goats. *J. Comp. Path.*, 97: 85-89.
10. Depner, K.R., O.J.B. Hubschle and B. Liess, 1990. Transplacental BVD virus transmission following experimental inoculation of goats in different gestational stages. *Dtsch. Tierarz. Wschr.*, 97: 421-423.

11. Wohlsein, P., G. Trautwein, K.R. Depner, O.J. Hübschle and B. Liess, 1992. Pathomorphological and immunohistological findings in progeny of goats experimentally infected with pestiviruses. *Zentralbl Veterinarmed B.*, 39: 1-9.
12. Depner, K.R., O.J.B. Hübschle and B. Liess, 1991. BVD virus infection in goat: Experimental studies on transplacental transmissibility of the virus and its effect on reproduction. *Arch. Virol.*, 3: 253-256.
13. Abraham, G.E., 1981. The application of natural steroid radioimmunoassay of gynecologic endocrinology. In G.E. Abraham, (eds.), *Radioassay Systems in Clinical endocrinology*. Basel. Marcel Dekker, pp: 475-529.
14. Goldman, M., 1968. *Fluorescent antibody method*. Academic Press, New York and London.
15. Snedecor, G.W. and W.G. Cochran, 1980. *Statistical methods 6th Edit.e Univ. Press Iowa, USA*.
16. Snowden, W.A., I.M. Parsonson and M.L. Broun, 1975. The reaction of pregnant ewes to inoculation with mucosal disease virus of bovine origin. *J. Com. Path.*, 85: 241-251.
17. Parsonson, I.M., L.O. Halloran, Y.C. Zee and W.A. Snowden, 1979. The effects of bovine viral diarrhea-mucosal disease BVD virus on the ovine fetus. *Vet. Micro.*, 4: 279-292.
18. Terlecki, S., C. Richardson, T. Done, W. Harknes, J.J. Sands, I.G. Shaw, C.E. Winkler, S.J. Duffell, D.S.P. Paterson and D. Sweasy, 1980. Pathogenicity for the sheep fetus of Bovine virus diarrhoea-mucosal disease virus of bovine origin. *Br. Vet. J.*, 136: 602-611.
19. Carlsson, U., G. Fredriksson, H. Kindahl and S. Alenius, 1987. Effect of bovine virus diarrhea virus on pregnancy in the ewe monitored by ultrasound scanning and levels of 15-keto-13,14-Dihydro-PGF2 α and progesterone. *Am. J. Reproductive immunology and Micro.*, 14: 91-98.
20. Scherer, C.F., E.F. Flores, R. Weiblen, L. Caron, L.F. Irigoyen, Neves and J.P.M.N. Maciel, 2001. Experimental infection of pregnant ewes with bovine viral diarrhea virus type-2 (BVDV-2): effects on the pregnancy and fetus. *Vet Microbiol.*, 79: 285-299.
21. Barlow, R.M., J.C. Rennie, W.A. Keir, A.C. Gardiner and J.T. Vantsis, 1975. Experimental in border disease. VII. The disease in goats. *J. Comp. Path.*, 85: 291-297.
22. Hewicker-Trautwein, M., B. Liess, H.R. Frey and G. Trautwein, 1994. Virological and pathological findings in sheep fetuses following experimental infection of pregnant ewes with cytopathogenic bovine virus diarrhea virus. *J. Vet. Med. B.*, 41: 264-276.
23. Murray, R.D., 1991. Lesions in aborted bovine fetuses and placenta associated with bovine viral diarrhea virus infection. *Archives of Virol.*, 3: 217-224.
24. Gardiner, A.C., 1980. The distribution and significance of border disease viral antigen in infected lambs and fetuses. *J. Com. Path.*, 90: 513-518.
25. Fredriksson, G., H. Kindahl and L.E. Edqvist, 1985a. Endotoxine-induced prostaglandin release and corpus luteum function in goats. *Animal. Reprod. Sci.*, 8: 109-121.
26. Fredriksson, G., H. Kindahl, K. Sandstedt and L.E. Edqvist, 1985b. Intrauterine bacterial findings and release of PGF2 α in the post partum dairy cow. *Zentralbl Veterinarmed A.*, 32: 368-380.
27. Jubb, K.V.F., P.C. Kenndy and N. Palmer, 1985. *Pathology of domestic animals 3rd Ed.* Academic Press INC.
28. Fray, M.D., G.E. Mann, E.C. Bleach, P.G. Knight, M.C. Clarke and B. Charleston, 2002. Modulation of sex hormone secretion in cows by acute infection with bovine viral diarrhoea virus. *Reproduction*, 123: 281-289.
29. Grooms, D.L., K.V. Brock and L.A. Ward, 1998. Detection of bovine viral diarrhea virus in the ovaries of cattle acutely infected with bovine viral diarrhea virus. *J. Vet. Diag. Invest.*, 10: 125-129.
30. Grooms, D.L., L.A. Ward and K.V. Brock, 1996. Morphologic changes and immunohistochemical detection of viral antigen in ovaries from cattle persistently infected with bovine viral diarrhea virus. *Am. J. Vet. Res.*, 57: 830-883.
31. Andreson, C.A., M. Sawyer, R.J. Higgins, N. East and B.I. Osburn, 1987. Experimental induced ovine border disease: Extensive hypomyelination with minimal viral antigen in neonatal spinal cord. *Am. J. Vet. Res.*, 48: 499-503.
32. Sawyer, M.M. and B.I. Osburn, 1992. Long term effects of persistent pestivirus infection on thyroid secretions in border disease in sheep in *Proc. Sec. Symposium on pestiviruses. European Society for Veterinary Virology, Lyon*, pp: 127-130.
33. Larsson, B., M. Traven, C. Hulten, C. Hardaf Segerstad, K. Belak and S. Alenius, 1995. Serum concentration of thyroid hormones in calves with a transient or persistent infection with bovine viral diarrhoea virus. *Res. Vet. Sci.*, 58: 186-189.