Acta Parasitologica Globalis 9 (2): 44-52 2018
ISSN 2079-2018

DOI: 10.5829/idosi.apg.2018.44.52

Equine Myiasis Caused by *Gastrophilus* Flies: A review

[1]*Yohannes Akele,* [1]*Gashaw Enbiyale,* [2]*Ayalew Negash and* [1]*Eyachew Ayana*

[1]Faculty of Veterinary Medicine, College of Medical and Health Science,
University of Gondar, P.O. Box: 196, Gondar, Ethiopia
[2]Lecturer at University of Gondar, Faculty of Veterinary Medicine,
Department of Veterinary Pharmacy, Gondar, Ethiopia

Abstract: This review focuses on gasterophilosis in equine population and its objective is to give highlight about epidemiology and parasitic points of *Gasterophilus*. Larvae of flies belonging to this genus are common obligate parasites in the gastrointestinal tract of equine (including horses, donkeys and zebras) and cause gastrointestinal myiasis. The results of most studies have shown that *Gasterophilus* profoundly affect the health status of equines. The effects of these parasites are more evident in young and under nourished horses, although virtually all equids are infected with *Gasterophilus.* Small numbers causes minimal damage, but large number pose a risk for colic and other gastrointestinal roblems. Clinical symptoms, season of the year, geographical location of the place, fecal examination of feces and equines hairs, necropsy or indirectly by serological tests are helpful for diagnosis. Biological, chemical and physical measurements are some approaches to control and preventing of *Gasterophilus* in equine. The prevalence of botfly larvae in these animals and its distribution with more species and greater abundance in tropical, subtropical and warm temperate region poses a serious epizootic and economic problem in world. So, Ethiopia in the world where the habitats of different equids overlap and is an important area where Zebra, wild ass and domestic horse, donkey live sympatric ally and share pastures seasonally which increased risk of acquiring infection. Therefore, to control and prevent the diseases, strategic deworming and rotational grazing program, continuous deforming and improvement of housing and feeding management are recommended.

Key words: Gasterophilus · Equine · Ethiopia

INTRODUCTION

In the developing world, there are estimated 110 million of equines. Ethiopia has about 7.9 million equines and possesses approximately half of the Africa's equine population with 37% donkeys, 58% horses and 46% mules. Equines have enormous contribution through their involvement in different social and economic sector. In Ethiopia, they have been considered as beasts of burden for long period of time and still render valuable services mostly as pack animals, throughout the country particularly in areas where modern means of transportation are absent, unaffordable cost or inaccessible [1].

Contrary to the huge size of equine population and the valuable services they provide in worldwide, the attention given to these animals is low [2]. Parasitism is one of the most common factors that constrain the health, behaviour and working performance of donkeys and horses worldwide. They cause various degrees of damage depending on the species and number at present, nutritional and the immune status of equids [3, 4].

Arthropod diseases particularly myiasis are one of the major health problems of equids worldwide and cause a broad range of infections depending on the location of larvae on the body of the host (e.g. dermal sub dermal, nasopharyngeal, internal organs, intestinal and urogenital myiasis) or their relationship with the host (e.g. obligatory, accidental or facultative myiasis). So, Myiasis varies widely in the forms it takes and its effects on equine. Such variations depend largely on the fly species and where the larvae are located [5].

Corresponding Author: Yohannes Akele, Faculity of Veterinary Medicine, College of Medical and Health Science, University of Gondar, P.O. Box: 196, Gondar, Ethiopia.

One of the myiasis agent affecting equine in both tropical and temperate regions is dipteran fly, G. Class Insecta, Order Diptera, Family Oestridae), larvae of *Gastrophilus* which are found in the gastrointestinal tract of horse and donkey and causing gastrointestinal myiasis. They are prone to *Gasterophilus* infections because the pastures where they graze are contaminated with infective stages (Eggs and larvae) of *Gasterophilus,* resulting in continuous infestation and reinfestation [6].

Gasterophilosis is a myiasis affecting equids hosts caused by *Gasterophilus* spp.larvae (Diptera: Oestridae) mainly originated from Pala arctic and Afro tropical regions [7]. But now a day it can thrive in different geographical environment.

The genus *Gasterophilus* (Diptera, Oestridae) includes nine species primarily affecting horses and donkeys. The bot flies are in the family Oestridae. Within this family are four subfamilies, including the Gasterophilinae, the stomach bot flies. All subfamilies within Oestridae are related by their larval feeding characteristics. The larvae demonstrate obligatory myiasis because completion of the bot flies' life cycle is dependent on the larvae consuming nutrients from tissues in the gastrointestinal tract of the horse [8]. They are present for about 10 months in different regions of the equids gastrointestinal tract and causing gastrointestinal myiasis. A large number of eggs can be laid by the female fly and the eggs of various species differ in color and laying different location in the host body [4, 9]. When the eggs are introduced into the mouth, the first instar larvae hatch and molt to L2, which can be present in different regions of the gastrointestinal tract where the L3 remains attached to the mucosa [10]. The direct damage of the botfly occurs after the larvae enter the animal's mouth and gastrointestinal tract.

The clinical signs showed by horses infested by *Gasterophilus* may includes difficulties swallowing, gastrointestinal ulcerations, gut obstructions or volvulus, rectal prolapses, anaemia, diarrhoea or digestive disorders [11]. Although only few, there are reports of human myiasis associated with *Gasterophilus* larvae, causing subcutaneous or ophthalmic myiasis by *Gasterophilus* spp. first and second stage larvae [12, 13]. The presence of this myiasis is commonly diagnosis by at the slaughter of the horses, or even when L3 instars are observed in the rectum or they are passed by feces [11]. Another possibility consists of the examination of eggs laid on the hair of the horses [14]. Few studies on the suitability of immune enzymatic probes for the diagnosis of gasterophilosis have been developed [15].

Therefore, the aim of this review is to give a snapshot on equine myiasis caused by *Gasterophilus.*

Review Literature

General Background of Myiasis: Myiasis, a noun derived from Greek word mya, which mean fly, was first proposed by Hope to define diseases of humans caused by dipterous larvae, as opposed to those caused by insect larvae in general food [10]. But now a day, Myiasis has a greater economic impact as an infestation of animals than of humans; there are no species of Diptera which are restricted to humans for their development but there are many that have a very restricted host range on animals and cause infestations [16].

Myiasis is defined as the infestation of live vertebrate's animals with dipterous larvae, which feed on the host's living or dead tissue, liquid body substance, or ingested food. The infestation is most often subcutaneous and produces a furunculous or boil-like lesion, but it is also known to occur in wounds and certain body cavities. The larval stages are obligate and host specific parasites living in the hosts' tissues or organs, causing what is commonly known as maggot infestation. Its distribution is worldwide, in tropical, subtropical and warm temperate areas. So, it is a challenging disease of domestic animals in global world [17].

***Gasterophilus*:** *Gasterophilus* larvae in the digestive tracts are the only arthropods reported frequently from equines spp. They are present for about 10 months in different regions of the equids in the gastrointestinal tract of equine (Including horses, donkeys and zebras) and cause gastrointestinal myiasis [18].

Morphology: An adult are 2 cm in length and resembles a bee with its black and yellow hairs. Because it is a fly, is has only one pair of wings. The adult has small, nonfunctional mouthparts and does not feed [19]. The female's abdomen is elongated, curled under and serves as an ovipositor, which is strong and protuberant [8]. The females are short lived, about two weeks, but during this time each can deposit up to 1000 egg in at different site of equine body depend on the species of *Gasterophilus*.

Third larvae are cylindrical, reddish orange with posterior spiracles and relatively larger than LI and L2. They are adapted to life in the gastrointestinal tract with their rounded body, narrow, hooked mouthparts and spines the hooked mouthparts, maxillae enable the larvae to securely attach to the lining of the stomach and

intestinal tract. The larvae use their flat mandibles to abrade the tissue of the stomach. The distribution and number of the spines in various segments is helpful in identifying the species. Gasterophilinae are characterized with rows of smaller spines amongst rows of larger spines. The third instar larva is also distinguished by its yellowish color [20].

Life Cycle: Species of *Gasterophilus* are obligate parasites of animals like horses, donkeys. They undergo complete metamorphosis (Egg, larvae, pupae and adult). Inseminated females lay between 150 and 1000 eggs directly on single hairs of the horse's front legs (Cannon bone area), abdomen, flanks and shoulder. Except *G. pecorum,* lay eggs on plants. Ovipositing on the rear legs appears to be discriminated against by most flies, whereas age, breed, size and sex do not appear to be a factor [21]. The laid eggs are essentially stalk less and are attached near the tip of the hair and develop into first star larvae within five days of being deposited by the female. Eggs hatch into a maggot within seven to 10 days of being laid on wounds. Larvae are stimulated to emerge by the horse licking or biting. The attached, fully developed eggs larvae at the first stage reach the oral cavity of horses passively (*G. intestinalis*, *G. pecorum)* or actively. The larvae either crawl to the mouth or are ingested and subsequently bury themselves in the tongue, gums, or lining of the mouth and remain for approximately 28 day and the larva stay in the oral cavity for some time. After wandering in the mucosa of the mouth, the larvae molt to the second stage and move into the stomach inhabit typical sites such as the stomach and duodenum where they grow and transform into the third stage larva. The second and third star larvae remain immobile for the following nine to 12 months. While, after the third star larvae have matured, they detach from the gastrointestinal tract and devoid with feces then metamorphose into chrysalis from which insects emerge into the environment [22].

The stages of the life cycle are not restricted to certain seasons due to the varied climates found in different geographical locations. It varies lasting from 1 week to several months depending on the season and climatic conditions. Under favorable condition (temperature and humidity) development of the eggs hatch to L1 takes place within few days [23]. When flies are active throughout the year, two or three generation are possible, but in cool or cold weather the laid egg by female become dormant to over winter. However, a general cycle begins with eggs laid in the early summer month [24].

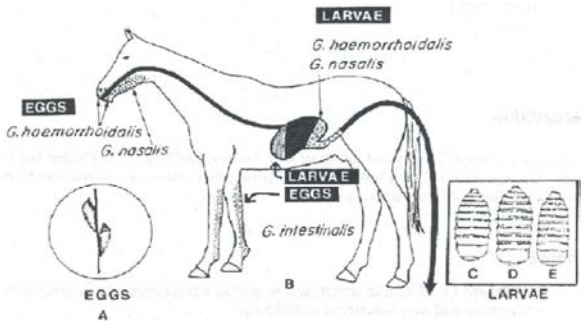

Fig. 1: General lifecycle of *Gasterophilus*, Source [26];
A = eggs on the grass and inter body hrough mouth and intramandibular region; B = eggs on the forelegs (G. intestinalis); C=larva of hoemorrhoidalis; D=larva of nasalis; E=larval of intestinals
Throat Bot fly - *Gasterophilus nasalis* = intermanibular region
Horse Bot Fly - *Gasterophilus intestinalis* = forelegs
Nose Bot Fly - *Gasterophilus hemorrhoidalis* = lips

In the temperate region, adult flies are active from May-June to September-October. So, in the summer, large number of eggs can be laid frequently by the female fly and the eggs of various species differ in color and laying location in the host body. Rapid larval development occurs whereas L1 arrested development (L1 hypobiosis) takes place in the late autumn and winter and corresponds the period of the year favourable to the adult fly activity. The hypo biotic first instar larvae represent the totality of *Gastrophilus* pecies density during the winter. From February to April, larvae resume their development and newly hatched flies are seen in May–June. In some region the hypobiosis period is shorter and in tropical and subtropical countries, adult fly activity and larval development occur all around the year [25].

Pathogenesis: The direct pathological effect of gasterophilosis varies considerably and depends on the species, the density of larvae and the site of infestation. The first instar larvae (L1) are usually localized in the oral mucosa and constantly irritating by cuticle spines and oral hooks of the larvae, together with certain toxic substances excreted by them induce acute inflammation (Stomatitis, gingivitis), painful congestion with ulceration on tongue. While L2 and L3 inhabit the gastrointestinal tract and attach to the stomach and intestine and produce multiple complications may arise. On attachment by their oral hooks to the stomach lining larva provoke an inflammatory reaction with the formation of funnel shaped ulcer surrounding by hyperplasic epithelium. This usually detected at PM [27].

Larvae present in large numbers in the stomach can also cause blockages and lead to colic. Large numbers of larvae impact the host by damaging the tissue of the stomach or the gut lining and consuming the nutrients that would otherwise be beneficial to the hosts' wellbeing. Other health issues that may develop due to a severe infestation of these larvae include: chronic gastritis, ulcerated stomach, esophageal paralysis, peritonitis, stomach rupture, squamous cell tumors and anemia [28].

Clinical Signs and Pathology: Gasterophilosis is wide spread myiasis, which may severely impair the health of equine. It is depends on where the larvae are located, types densities of larvae and the host response. Although the parasites considered to be well tolerated by the host, they have been incremented in inducing difficulties in swallowing, gastrointestinal ulcerations, gut obstructions or volvulus, rectal prolapses, anemia, diarrhea, digestive disorders and debilitating with heavy infestation, sometimes proven fatal [9].

The larvae use their anterior spines and mouth hooks to attach to the wall of the gastrointestinal tract. When the first instar larvae burrow into the mouth, the horse may experience severe irritation, as well as the development of pus pockets and loosened teeth. Loss of appetite may develop due to the larva's inhabitance [21]. In donkey, macroscopic lesions such as multiple erosive crater like lesions and well circumscribed ulcerated mounds caused by *G. intestinalis* is common finding and small prominent circular and funnel like or punctiform lesions associated with an inflamed duodenum and pylorus characterized lesions created by *G. nasalis*. At higher levels of infestation multiple lesions of coalescent and crater-like lesions, which were smaller in size, were evident at the duodenal ampulla and pylorus.

In most cases the numbers of mucosal lesions were higher than the number of larvae at detached site. The other problem is rectal associated with gasterophilosis is rectal prolapse in Ethiopian working donkey majorly due to *G. nasalis*. The incidence of rectal prolapse is significantly higher during the rainy season even though it's incidence year round. Circular demarcated ulcer like and deep circumferential pits or ring-like mucosal lesions significant at the larval attachment sites [2].

Bot larvae attached to the mucosa of the stomach present a condition called gastric myiasis. Attachment to the gut can cause ulceration and hemorrhage. Migration by larvae under the skin and mucous membranes causes lesions in the mouth that may make eating painful. These lesions are also subject to secondary bacterial infection. Deposition of eggs by adult flies causes nervousness (Parasite worry). There are virtually no clinically apparent effects with low levels of infestation [11]. The mucous membranes of the stomach demonstrated crater like alterations caused bot fly larvae (Fig. 2).

Although botfly larvae are known to attach to aberrant sites within the digestive tract, Lapointe and his colleagues [30] reported the first case of deep penetration of the colon by a *Gasterophilus* larva, with the resulting leakage of intestinal content leading to septic peritonitis.

Epidemiology: Many factors are known to influence the transmission and prevalence of *Gasterophilus* infestation. Broadly the three influencing factors that can determine the occurrence of gastrointestinal tract infestation could be mentioned as environmental host interaction, environmental parasitic interaction and host parasitic interaction. So, the development and survival egg and larvae of *Gasterophilus* with faces and on pasture are depending on temperature and moisture. Thus forming suitable environment for development and for completes its life stage [31].

They are currently worldwide distribution and originally from Pala arctic and Afro tropical regions but the three common *Gasterophilus* species are found in North America. *Gasterophilus intestinalis* (DeGeer) is the more common horse bot fly, which is an internal parasite of the gastrointestinal tract. *G. nasalis* (Linnaeus), the nose bot fly and *G. haemorrhoidalis* (Linnaeus), the throat bot fly, are also distributed throughout North America [27].

There are many reports on the prevalence of *Gasterophilus* in temperate and tropical areas; According to Gokçen *et al.* [11] its prevalence in temperate climate conditions of Western Europe countries between the rates of 43 and 69%, respectively. Only seven *Gasterophilus* species were detected in Turkey, namely *G. intestinalis, G. nasalis, G. haemorrhoidalis, G. inermis, G. nigricornis, G. pecorum* and *G. meridionalis.* While as six of the nine known *Gasterophilus* species occur in China: *G. pecorum, G. nasalis, G. nigricornis, G. haemorrhoidalis, G.intestinalis* and *G.inermis* [32, 33]. In Poland, four species, including *G. intestinalis*, *G. nasalis*, *G. haemorrhoidalis* and *G. pecorum,* were described [34].

There are seven species of equine bot flies *Gasterophilus* spp. reporting from the Ethiopian region, two of them only from zebras. Most probably, however, all species are able to develop in horses and donkeys as well as in zebras, so that the latter form true reservoirs for

Fig. 2: Crater like ulcerative lesions and 3rd instars *Gasterophilus* larvae on the horse stomach mucosal membrane; Source [29]

these parasites [10]. Currently, its prevalence in different region of Ethiopia: in mekelle [31], Gondar [1] in central oromia [3] in East Hararghe [35] is less than 5%. As they reported, Botfly usually associated with large and small *Strongylus*, *Parascaris*, Pinworm and Liver flukes. The common host of this particular species of bot fly is the horse. Other equid species, including mules and donkeys, can also serve as hosts. Although accidental, the horse bot also has been reported in man causing either ocular or cutaneous myiasis [36].

The Importance of *Gasterophilus* Causing Flies on Equids: Flies may cause a severe problem to equine. Their bites are painful constituting a nuisance to horse, donkey and mules, blood loss, allergic reactions such as skin rashes, itching and body swelling, interference with normal grazing habits and increased energy utilization by the equine in its effort to remove flies [37]. In addition, biting and nuisance flies may act as mechanical and biological vectors for a range of pathogenic diseases and cause myiasis in human and animals [38]. However, sometimes, some myiasis causing flies are beneficial to the host due to their antimicrobials activity or maggot therapy [39].

Medical Importance of Myiasis Causing *Gasterophilus* Flies: Human myiasis is the infestation of any part of the body by larvae of Diptera (Flies) which feed on the host's tissue or body fluids. People living in close proximity to livestock in rural areas are particularly at risk, thus the disease can be mentioned as an occupation disease. Most of the fly larvae are transmitted to human. Fly larvae comprise both medical and veterinary importance as a *legal* evidence in forensic entomology and are responsible as a vector for transmission of livestock parasites/pathogen [13].

The horse botfly occasionally can cause what is called ocular myiasis or invasion of the eye by first stage larvae. Although these cases are rare, they often occur in individuals handling horses that have botfly eggs on their hair. Occasionally, these botfly larvae will enter the eye, rather than reside on the surface as is more common with the sheep nose bot, *Oestrus ovis* Linnaeus. An additional rare form of horse bot myiasis is called cutaneous myiasis. In this case, hatching larvae enter the skin of humans and begin burrowing through the skin causing visible, sinuous, inflamed tracks accompanied by considerable irritation and itching [40]. Anyone working with horses during botfly season should be familiar with the risks and take appropriate precautions.

Diagnosis: *Gasterophilus* larvae infestation has great importance in the horse medicine; gastrointestinal ulcerations, gut obstructions or volvulus, rectal prolapses, anaemia, diarrhoea or digestive disorders. Therefore, an accurate diagnosis of gasterophilosis is essential to study its epidemiology and control so, it is crucial to understand the actual incidence and epidemiology of this myiasis in equines [41].

So, diagnosis can be made based history, on parasite-host interactions, seasons and other epidemiological features, signs and symptoms. Eggs may be identified by color and site of deposit. The diagnosis of bot infestation of horse's stomach can be also made by identifying the larvae in feces. In some cases, the diagnosis is made upon examination of the stomach at necropsy [23].

Direct Detection of Infestation: The examination of the hair equines' for the visual identification of yellow to whitish bot eggs attached on the lower legs, lips or jaw. Depending on the female eggs laying site. Faeces are also macroscopically examined for the demonstrating of 3rd instars *Gasterophilus* larvae [42]. Knowing the local seasonal behavior of the flies can also help to estimate whereas the observed symptoms could be due to these flies or to other unrelated factors.

Indirect Detection (Serological Examination): Immunodiagnostic methods are instrumental in the detection of gasterophilosis, thus replacing the need for fecal and post-mortem examinations for equine botflies. They are a simple and economic means to perform diagnoses on living animals, allowing the planning of

timely treatments before larvae have caused economic losses and the monitoring of eradication programs across broad areas [43]. The humoral immune response of equines against *Gasterophilus* can be detected by an ELISA and *G. intestinalis* excretory/secretory antigens. The rising in the IgG response could be related to the presence of hooked mouthparts and spines in the *Gasterophilus* larvae, responsible for the occurrence of hemorrhages, chronic gastritis, ulcerated stomach or even stomach rupture, which enhances the antigen presentation to the immune system in the host [15].

Necropsy: The final diagnosis could be achieved by PM examination on equine stomach to detect *Gasterophilus* larvae of L2 and L3 at different developmental stages in the gastrointestinal tract [21].

Treatment and Control: Horses are susceptible to one or more fly pests at any time of the year. All flies have the same life stages. The adult fly is the pest stage of the life cycle for most flies, but the horse bot is one of several exceptions where the fly larva is the primary pest stage that challenge to control but, there are three approaches to control it [43].

The first control method is preventive and aims to eradicate the adult flies before they can cause any damage and is called vector control through sterilization technique by irradiation, where a significant number of artificially reared sterilized (Usually through irradiation) male flies are introduced. The male flies compete with wild bred males for females in order to copulate and thus cause females to lay batches of unfertilized eggs which can't develop into the larval stage [44].

Myiasis inducing flies can be also control by applications of insecticides in the environment where equine is kept. An insecticide can also be applied weekly during the peak egg lying season to the areas of the body covered with bot eggs. Many of the endectocide treatments another options control horse bots when routinely applied. The horse should be treated orally within one month after eggs are seen. A second treatment should be administered in the fall to control the second and third instar larvae. Larvicides and Insecticides labeled as in different formulation such as liquids, gels, boluses and feed additives for horse bot control. Internal medications like ivermectin will usually control 2nd larvae but may not control 3rd larvae. Most effective treatments should be applied 1 month after first sighting of eggs to control 2nd stage larvae. Materials which control both 2nd and 3rd stage larvae should be applied during outbreak. Equines can be also treated prophylactic ally with slow release boluses containing ivermectin which can provide long-term protection against the development of the larvae [45, 46].

Although chemotherapeutic products, sterile insect technique and biological control methods, have been successful in the control of myiasis causing larvae, there are many constraints linked to the use these methods to the risks of animal and environment. Currently the developments of molecular techniques myiasis causing larvae control strategies makes right way and easy to improve farm management practices and to integrate them with measures consistent with the principles of environmental sustainability [47].

Myiasis is usually treated by surgical removal of larvae and treatment of associated infestations. Maggot-infested wounds should be thoroughly cleansed and infested tissue should be surgically removed. Wounds should then be treated with insecticide-containing wound ointments, followed by further supportive treatment. Repellents are helpful in the prevention of myiasis in wounds. In many circles the first response to cutaneous myiasis once the breathing hole has formed, is to cover the air hole thickly with petroleum jelly. Lack of oxygen then forces the larva to the surface, where it can more easily be dealt with. In a clinical or veterinary setting there may not be time for such tentative approaches and the treatment of choice might be more direct, with or without an incision. First the larva must be eliminated through pressure around the lesion and the use of forceps. Secondly the wound must be cleaned and disinfested. Further control is necessary to avoid further reinfestation. However, some maggots are deliberately used in wound treatment, technically referred to as maggot debridement therapy [48]. They are known to benefit wounds by removing dead and necrotic tissue, secreting antimicrobial compounds and sometimes stimulating wound healing.

But, the successful control program is removing the environment most favourable to the flies includes: weekly removal of bedding, proper choice of bedding material, use of less-toxic insecticides, release of biological control agents and use of physical controls, such as traps. The incorporation of these methods is required to manage flies across animal farms or areas to breaking the lifecycle of the botfly [36].

CONCLUSION AND RECOMMENDATIONS

In conclusion, as most study revealed, the high densities of *Gasterophilus* and other myiasis causing flies occur in tropical and subtropical areas, where favorable agroeological zones for multiplication of fly

larvae. However, a general life cycle begins with eggs laid in the early summer months. So, gasterophilosis is the most devastating and challenging diseases in world.

The prevalence of *Gasterophilus intestinalis* more dominant than *G. nasalis* and *G.haemorrhoidalis* However, rectal prolapse due to *G. nasalis* is the major problem in Ethiopian donkey.

These differences in the species composition, prevalence and larval burdens of *Gasterophilus* spp. in different countries are probably due to ecological conditions, management factors (e.g., pharmaceutical treatments, different animal husbandry), the host (e.g., genetic differences, race susceptibility) and the parasite (e.g., genetic differences, population compositions). In Ethiopia where farm animals are kept on pasture throughout the year and climatic conditions are favourable for development and survival of infective stages of myiasis causing flies. So, Animals that fed only pasture and lived in poor house or free grazing animals, which heighten to contact with female botflies, to live with other equine reservoir to these larvae causing gastrointestinal myiasis at increased risk of acquiring infestation.

Based on taking in mind the above points, the following recommendations are forwarded:

- Improvement of housing and feeding management system for equines.
- Regular deforming and promotion of equine husbandry practices.
- Owners should be trained to improve the management system, especially in terms of the level of nutrition so that the animal can have good body condition that confers some level of resistance against *Gasterophilus* infestation
- Further study should be done covering large and different agro ecologies of the region.
- Strategic deworming using broad spectrum anthelmintic drugs and rotational grazing program should be implemented to reduce pasture contamination and disease burden.

ACKNOWLEDGMENTS

It is our great pleasure to give deep gratitude for our advisor Dr. Basaznew Bogale for his guidance, devotion of time and for his suggestion to correct this correction. Lastly, but not least my indebted goes to all my friends, officials and classmate, who were key during my campus life; I wish to them all the best.

REFERENCES

1. Mezgebu, T., K. Tafess and F. Tamiru, 2013. Prevalence of Gastrointestinal Parasites of Horses and Donkeys in and around Gondar Town, Ethiopia: Open Journal of Veterinary Medicine, 3: 267-272 http://dx.doi.org/10.4236/ojvm.2013.36043 Published Online October 2013 (http://www.scirp.org/journal/ojvm.
2. Getachew, A.M., G. Innocent, A.F. Trawford, S.W.J. Reid and S. Love, 2012. Gasterophilosis: a major cause of rectal prolapsed in working donkeys in Ethiopia. Tropical animal health and Production, 44: 757-762.
3. Asefa, Z., B. Kumsa, B. Endebu, A. Gizachew, T. Merga and E. Debela, 2011. "Endoparasites of Donkeys in Sululta and Gefersa Districts of Central Oromia, Ethiopia, " Journal of Animal and Veterinary Advances, 10(14): 1850-1854. http://dx.doi.org/10.3923/javaa.2011.1850.1854.
4. Zaheri, B.A., H. Ronaghi, M.R. Youssefi, S.M. Hoseini, S. Omidzahir, R. Dozouri, S.R. Eshkevari and A. Mousapour, 2014. *G. pecorum* and *H. muscae* in Persian onager (Equus hemionus onager), histopathology and parasitology survey. Journal of Comparative Clinical Pathology, 24: 1009-1013.
5. John, D., Petri, Markell and Voge, 2006. Medical Parasitology: 9th Edition. Missouri: Saunders Elsevier, pp: 328-334.
6. Ibrayeva, B., L. Lidera and B. Christian, 2015. Gasterophilus spp.infections in horses from northern and Central Kazakhstan, Veterinary Parasitology, 207: 94-98.
7. Colwell, D.D., M.J.R. Hall and P.J. Schol, 2006. A Synopsis of the biology, hosts, distribution, Disease Significance and management of the genera. In: Colwell DD, Hall MJR, Scholl PJ (Eds.), the Oestrid Flies: Biology, Host-Parasite Relationships, Impact and Management. CAB International.
8. Zurek, L., 2004. Horse bots: Gasterophilus intestinalis, horse bot fly; G. nasalis, throat bot fly; G. haemorrhoidalis, nose botfly Kansas State research and education http://www.oznet.ksu.edu/entomology/medicaveterinary/ GASTRO.html (8 September 2007).
9. Cogle, T.P. and M.C. Cogle, 2000. Field observations of the host parasite relationship associated with the common horse bot fl y, Gasterophilus Intestinalis. Vet. Parasitol., 88: 93-105.

10. Zumpt, F., 1965. Myiasis in man and animals in the Old World Butterworth, London, United Kingdom, 111-128.
11. Gokcen, A.M., Sevgili, M.G. Alta and I. Camkerten, 2008. The presence of Gasterophilus species in Arabian Horses in Sanliurfa region. Türkiye Parazitol Dergisi, 32(4): 337-339.
12. Royce, L.A., P.A. Rossignol, M.L. Kubitz and F.R. Burton, 1999. Recovery of a Second Instar Gasterophilus Larva in a Human Infant: A Case Report. Am. J. Trop Med. Hyg., 60: 403-404.
13. Anderson, J.R., 2006. Oestrid Myiasis of Humans: In: The Oestrid Flies: Biology, Host Parasite Relationships, Impact and Management: Colwell DD, Hall MJR, Scholl PJ (Eds): CAB International, pp: 201-209.
14. Dawson, K., 2003. A Non-Lethal Method for Assessment of Efficacy of Antiparasitics against Parasites in horses such as A. perfoliata and G. intestinalis. Vet. Parasitol., 115: 67-70.20
15. Cortinas, F.J., I. Francisco, J. Sánchez, P. Mula, C. Cazapal, J.L. Suárez, L. Vázquez, R. Francisco, M.S. Arias, P. Díezbanos, A. Scala, P. Morrondo, A. Pazsilva and Sanchezandrader, 2010. Chronobiology of Gasterophilus infestations In Silvopasturing Horses from Nw Spain Rev. Ibero-Latinoam. Parasitol, 69(1): 66-71.
16. Noutsis, C. and L.E. Millikan, 1994. Myiasis. Dermatology, Clin., 12: 729-736.
17. Safdar, N., D.K. Young and D. Andes, 2003. Autochthonous furuncular myiasis in the United States: case report and literature review. Clin. Infect. Dis., 36(7): e73-e80.
18. Kettle, D.S., 1993. Medical and Veterinary Entomology: CAB International, Wallingford, UK., pp: 262-284.
19. Otranto, D., P. Milill, G. Capell and D.D. Colwell, 2005. Species composition of *Gasterophilus* spp. (Diptera, Oestridae) causing equine gastric myiasis in southern Italy: parasite biodiversity and risks for extinction. Vet. Parasitol., 133: 111-118.
20. Agneessens, J., S. Engelen, P. Debever and J. Vercruysse, 1998. Gasterophilus intestinalis infections in horses in Belgium. Veterinary Parasitology, 77: 199-204.
21. Mashayekhi, M. and B. Ashtari, 2013. Study of Gasterophilus role in Equine Gastric Ulcer Syndrome in Tabriz area. Bulletin of Environment, Pharmacology and Life Sciences, 2(12): 169-172.
22. Betschart, B. and K. Pfister, 2009. Protein Expression Profi Le of Gasterophilus intestinalis Larvae Causing Horse Gastric Myiasis and characterization of Horse Immune reaction. Parasit Vectors, 2, pp: 6.
23. Merial, 2001. Gasterophilus SPP: Common horse bot, throat botfly, nose botfly. http://ph.merial.com/ equine/pdf/ equine vteq bot. pdf (8 September 2007).
24. Pfizer, 2007. Bots. Animal Health. http://www.pfizerah.com/health.asp?country=US&lang=EN&species=EQ&drug=PU&t=2329&key=2271&type=3 (8 September 2007)
25. Urquhart, G.M., J. Armour, J.L. Dunncan and F.W. Jennings, 1996. Veterinary Parasitology, 2nd. Blackwell, U.K.
26. Hall, M.J.R. and R. Wall, 1995. Myiasis of humans and domestic animals. Adv. Parasitol., 35: 257-334.
27. Taylor, M.A., R.L. Coop and R.L. Wall, 2007. Veterinary Parasitology, 3rd edition. Blackwell Publishing, UK, pp: 874.
28. Ismail, A., A.D. Abakar, N.K. Ahmed, H.I. Seri, A.E. E.L. ATigani Asil1 and A.E. Bashar, 2013. Gasterophilus spp. larvae infection rates and seasonal variation in donkeys autopsied in Nyala, South Darfur, Sudan. Journal Of Science And Technology, 14(1): 54-65.
29. Ozdal, N., K. Bicek, O. Orunc and S. Deger, 2010. Presence of gasterophilus species of horse in van region.; YYUveteriner fakultesi dergisi. Van, Turkey, 21(2): 87-90.
30. Lapointe, J.M. Leste, C. Ce and A. Villeneuve, 2003. Septic Peritonitis Due to Colonic Perforation Associated with Aberrant Migration of a Gasterophilus intestinalis Larva in a Horse. Veterinary Pathology, 40: 338-339.
31. Belete, S. and S. Derso, 2015. Prevalence of major gastrointestinal parasites of horses in and around mekelle (Quiha and wukro), World Journal of Animal Science Research , Available online at http://wjasr.com/: University of Gondar, Department of Veterinary Clinical medicine, PO BOX 196, 3(3): 1- 10
32. Li, K., Z. Wu and D.F. Hu, 2007. The new pathogens (Gasterophilus spp.) reports of Przewalski horses (Equus przewalskii) gastric myiasis in China , Anim. Husb. Vet. Sci., 38(8): 837-839.
33. Liu, S.H., 2012. Morphology and epidemiological investigation and the mitochondrial Cytochrome Oxidase I (COI) and 16 S rRNA gene phylogenetic of Gasterophilus. MSC. Beijing Forestry University, pp: 54-56.

34. Studzinska, M.B. and K. Wojcieszak, 2009. Gasterophilus sp. Botfly larvae in horses from the South Eastern part of Poland. Bulletin of the Veterinary Institute in Pulway, 53: 651-655.
35. Sultan, A., G. Ayele, B. Tadesse and A. Ahmed, 2014. Prevalence of gastrointestinal parasites of horses and donkeys in Kurfa Chale District, East Hararghe, Ethiopia, Livestoke Research and Rural Developments, 26(7).
36. Kaufman, P.E., D.A. Rutz and S. Frisch, 2005. Large sticky traps for capturing house flies and stable flies in dairy calf greenhouse facilities. J. Dairy Sci., 88: 176-181.
37. Karshima, S.N., I. Ajogi, G. Mohammed and A.I. Lawal, 2011. A survey for biting flies in three local Government areas of Taraba state, Nigeria. Journal of Veterinary Sciences, 9(1): 36-38.
38. Andrade, S.R., F.J. Cortinas, J. Francisco, A. Sanchez, P. Mula, C. Cazapal, L. Vázquez, J.L. Suárez, R. Francisco, M.S. Arias, P. Díezbanos, A. Scala and A. Pazsilva, 2010. A novel second instar Gasterophilus xcretory/secretory antigen based Elisa for the diagnosis of Gasterophilosis in grazing horses. Veterinary Parasitology, 171: 314-320.
39. Catts, E.P. and G. Mullen, 2002. Medical and Veterinary Entomology: Myiasis (Muscoidea, Oestroidea) In Mullen G, Durden L. (editors). San Diego: CA. Academic Press, pp: 318-347.
40. Traversa, D. and D. Otranto, 2006. A new approach for the diagnosis of myiasis of animals: The example of horse nasal myiasis. Vet. Parasito, 141: 186-190.
41. Sievers, G. and B. Weber, 2005. Períodic oviposition of Gasterophilus nasalis and G. intestinalis in equines: VIII Región, Chile. Arch Med. Vet., 37: 169-171.
42. Kornas, S., J. Gawor, M. Skalska and B. Nowosad, 2006.Occurrence of botfly in horses from small farms Med. Weter., 62: 452-459.
43. Mullen, G.R. and L. A. Durden, 2002. Medical and veterinary entomology: Elsevier Science, USA, pp: 637.
44. Duponte, M.W. and L.B. Larish, 2003. Horse bot fly: horse throat bot fly: College of tropical Agriculture and Human resources.
45. Coles, G., M. Hillyer, F. Taylor and I. Villard, 2003. Efficacy of an ivermectin praziquantel Combination in equids against bots and tapeworms. Vet. Record, 152: 178-179
46. Peter, R.J., V. Den, P. Bossche, B. Penzhorn and B. Sharp, 2005. Tick, fly and mosquito Control lessons from the past, solutions for the future, Veterinary Parasitology, 132: 205-215.
47. Otranto, D. and J.R. Stevens, 2002. Molecular approaches to the study of myiasis-causing larvae International Journal for Parasitology 32: 1345-1360.
48. Vilcinskas, A., 2011. From traditional maggot therapy to modern bio surgery. In: Vilcinskas A, ed. Insect Biotechnology: Dordrecht: Springer, pp: 67-75.