

## Prevalence of *Demodex* Mites (Acari: Demodicidae) Parasitizing Human in Babol, North of Iran

<sup>1</sup>Mohammad Reza Youssefi, <sup>2</sup>Rabeeh Tabari Pour and <sup>3</sup>Mohammad Taghi Rahimi

<sup>1</sup>Department of Veterinary Parasitology, Islamic Azad University Babol-Branch, Iran

<sup>2</sup>Young Researchers Club, Islamic Azad University Babol-Branch, Iran

<sup>3</sup>Department of Parasitology and Mycology, School of Medicine,  
Mazandaran University of Medical Science, Sari, Iran

**Abstract:** *Demodex* is a cigar-shaped mite which has various species that are able to cause gale or itch in animal and human. Two species living on human, *Demodex folliculorum* and *Demodex brevis* have been identified as causative agents of formation of acne. In present study, 308 participants in Babol from three different groups (students, patients and elder people of Senior Care Centers) examined from April 2011 to July 2011 for surveying prevalence of Demodecosis. Lateral of individuals' nose pressed and cleared by lactophenol. Findings indicated that 14 (04.54%) were positive including 7 females and 7 males that 21.42% belonged to age group 0-20 years, 64.28% to age group 21-40 and 14.28% to age group 41-60 years, respectively. However, further studies are required to attain comprehensive information about Demodecosis in our country and relationship between this infestation and dermal problems.

**Key words:** *Demodex folliculorum* • *Demodex brevis* • Mite • Prevalence • Babol • Iran

### INTRODUCTION

*Demodex* spp. mites belong to the order Prostigmata and family Demodicidae. These parasites are tiny and cigar-shaped. The length of mature *Demodex* is variable from 100µm to 400µm [1]. These mites have four-segmented legs which appeared short and stumpy on the anterior half of the body. The striated opisthosoma is remarkable [2]. *Demodex* spp. has various species however, two species which found on human are able to cause itching, inflammatory diseases of human skin and eye [3]. *Demodex folliculorum* which is frequently found in hair follicles and *Demodex brevis* living in sebaceous glands (fat glands) connected to hair follicles [1]. These mites are found in hair follicles, fat glands, eyelids, nose and its surroundings, cheeks and ear discharge (ear wax), small facial rashes [4]. The unusual locations of this parasite include scalp, breast, nipple, penis, head of the penis and exterior fat glands at cheek mucus [5]. Demodectic larvae are naturally minute and feed on subcutaneous secretions especially fat glands or sebum and they get matured and multiplied. The female mite lays eggs at the base of hairs, inside of follicles and produces

six-leg larvae [6, 7]. These types of mites are effective in formation of acne and also may play roles in formation of black-head rashes.

A few articles previously reported the Demodectic mites causing acne rosacea in some provinces of Iran including Hamadan, Gorgan and Arak provinces [8-10]. However, there is a little information on human infectious status of *Demodex* mites in Babol. Thus, the aim of this study was to investigate the prevalence of follicular *Demodex* on human in different age groups in Babol city from April to July 2011.

### MATERIALS AND METHODS

**Data Collecting:** Initially, a questionnaire was prepared to record information including: age, gender, residence area and clinical manifestations. Three different groups were selected: 200 students (132 females and 68 males) from Babol Islamic Azad University, the second one comprised of 81 patients (67 females and 14 males) who had referred to Babol Shahid Beheshty Hospital and 27 elderly residing in one of the Babol Senior Care Centers.

**Sampling:** The recognizing of mites carried out by laterally pressing of individuals' nose and preparing smear on slides. Afterwards the slides were cleared using a drop of lactophenol and then examined meticulously under light microscopic with magnification of 4 and 10X.

**Data Analyzing:** Eventually, information on infestation of examined individuals with *Demodex* during April 2011 to July 2011 were recorded in SPSS 14 statistical software for further analysis, using statistical test ( $\chi^2$ ).

## RESULTS

This study was performed through 4 months in Babol city in 2011 in which 308 individuals were participated, 257(83.4%) lived in city and 51(16.6%) in rural areas and 81 individuals were (22.93%) male and 227 (73.07%) female, respectively (Table 1). The highest rate of prevalence was in age group 21-40 years (76.62%) and the lowest in age group 0-20 years (01.94%), respectively (Fig. 1). The examinations indicated that 14 (04.54%) were positive, including 7 female and 7 males and 21.42% belonged to age group 0-20 years, 64.28% to age group 21-40 and 14.28% to age group 41-60 years, respectively.

24 (07.08%) of examined individuals had a close relation with domestic animals suchlike cow and sheep that are source of *Demodex* parasite and 5 (1.6%) had dermal problems. Some of participants had clinical manifestations that include 51 (16.06%) rash, 5 (1.6%) skin scaling, 8 (2.6%) excessive fat secretion. The individuals' awareness of mange was also measured so that, 52 (19.02%) people were familiar with name and symptoms of *Demodex*.

Table 1: Residence area and gender of examined individuals in the current study

Residence Place		Gender	
Urban	Rural	Male	Female
257 (83.4%)	51 (16.6%)	81 (26.3%)	227 (73.7%)

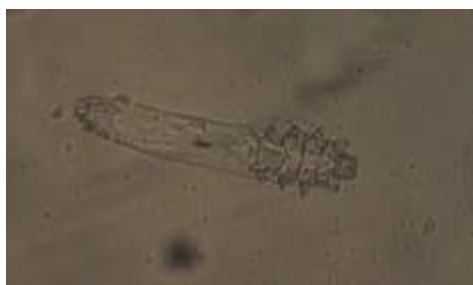

Fig. 1: *Demodex* mite separated from sebaceous glands surrounding nose

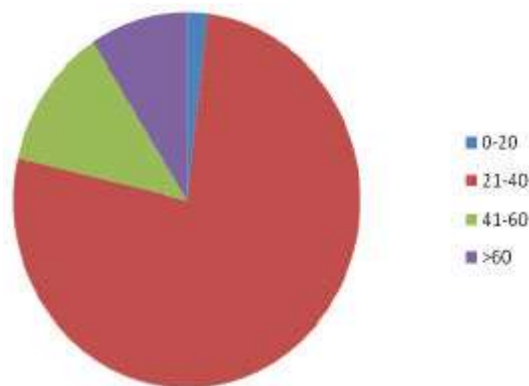


Diagram 1: Age distribution of examined individuals for Demodocosis in Babol in 2011

## DISCUSSION

Demodocosis infestation normally is benign, though sometimes it is causative agent of losing eyelashes and granulomatous skin eruption [11]. In addition, *Demodex* causes localized Keratitis and these mites have ability of penetrating into the skin and dwelling in various internal organs and causing granulomatous response [1, 12]. Moreover, *demodex* in susceptible individuals may be involved in introducing bacteria causing acne into the skin follicles and it causes blepharitis from synergetic bacterial infection [13]. Both *D. folliculorum* and *D. brevis* can multiply opportunistically and cause infection occurring with immunosuppression individuals [14]. This genus has different species such as *D. bovis*, *D. equei* and *D. phylloides* which have various consequences in their hosts and they could have more severe consequences predominantly specially in dogs. This is noteworthy that dog follicle mite, *D. canis* which causes red mange together with bacterium of *Staphylococcus pyogenes* can lead death in puppies [1]. Considering close relation between human and domestic animals, probably these hosts are primary source of infection and transmission.

Prevalence of *Demodex* in human was high and is about 20% in younger age of 20 years and in the aged people almost 100% [15]. Demodocosis in human is able to infect both males and females. Ghazaei indicated that the prevalence of infection in females is 2.5 times more than males and our study is corresponding to Ghazaei report [10]. While Roihu in Finland mentioned that the prevalence in males is more than females (59%) [16]. According to the studies conducted by Elston in America, it was concluded that men are 20% to 80% more infested

with *Demodex* parasite than women, because they have more sebaceous glands therefore they can produce more food for mange [17].

In the current study, age distribution of infestation was 21.42%, 64.28 % and 14.28% in three different age groups including (lower than 20), (21-40) and (41-60) years, respectively. According to studies undertaken by Ghazaei in Arak city the percentage of infestation in individuals who were younger than 20 years was 43%, in 20-40 years was 66% and in the individuals older than 40 years was 85% that it reveals a significant relationship between age and rate of prevalence [10]. In addition, according to study that was carried out by Elston, the prevalence of *Demodex mangle* in two age groups including 3-15 and 31-50 years, were 13% and 69% respectively and in 71 years old individuals even reached the border of 95% [17].

Demodectosis mites may play some roles in arousing inflammatory responses in acne Rosacea, Moravvej conducted a study on patients referred to Bouali and Loghman Hospital in Gorgan city in the years 1995-2004 in order to determine the relationship between *Demodex* mites and acne Rosacea. The patients afflicted with Rosacea, 26 (34.7%) were men and 49 (65.3%) women. The mean age of patients was 43 years and they were 21 to 93 years [9]. In addition, according to studies carried out by Pilehvar in Hamedan province during 1993-1998, the mean age of people afflicted with Rosacea was 45.3% that 63.4% of them were females and 36.6% males [8]. These studies indicated that *Demodex* mites increase the risk of being afflicted with acne Rosacea [9].

Considering that individuals are subject to possibility of transmission of this parasite particularly in the families through direct contact and using shared appliances suchlike hat, comb and shared scarves, it is necessary to consider some cautionary practices and apply preventive actions in the home. Therefore, it is imperative to regard Demodectosis as one of the differential diagnosis of cases of Dermatitis.

#### ACKNOWLEDGEMENT

The authors would like to appreciate very much for kind collaboration of Mr. Soleimani. The authors declare that they have no conflicts of interest.

#### REFERENCES

1. Larry, S.R. and J. Janovy, 2006. Foundations of parasitology. Seventh edition. Mcm Graw. Hill companies, America, pp: 590.
2. Baima, B., 2002. Demodectidosis revisited. Acta Derm. Venereol, 82(1): 3-6.
3. Walker, A., 1994. The arthropods of human and domestic animals: a guide to preliminary identification. Springer Company, pp: 112-115.
4. Zaem, M.R., 1991. Fundamental of Entomology. 3rd Edn, Tehran University Publication.
5. Murat, U. and K. Ozlem, 2009. The prevalence of *Demodex folliculorum* on the Scrotum and Male Perineal skin. Turk Parasitol., 33(1): 28 -31.
6. Desch, C. and W.B. Nutting, 1972. *Demodex folliculorum* (Simon) and *D. brevis* Akbulatova of man: Redescription and reevaluation. J. Parsitol., 58: 169-177.
7. Service, M.W., 1986. Lecture Notes on Medical Entomology. Black Well Scientific Publication, Oxford.
8. Pilehvar, M., A. Zamanian Monsef and K. Kashani, 2001. Follicular *Demodex* and Acne Rosacea. Scientific J. Hamedan Treatment and Health Services and Medical Sciences University. 22: 5-8.
9. Morrravej, H. and M. Dehghan, 2004. The Relationship between Demodectic Mites and Acne Rosacea. Scientific Journal of Gorgan Medical Sci., 13: 62-66.
10. Ghazaei, M.R. and A. Farhad Pour, 2009. The report on a Case of Demodectosis. The Scientific and Research Journal of Arak Medical Sciences University. 1(46): 107-110.
11. Sefidgar, S.A.A., M.R. Youssefi and S.M. Rezvany, 2006. The Report on a Case of Head Demodectosis in a 6 Years Girl. Babol Medical Sciences J., 6: 63-66.
12. Meral, T. and S. Kucuk, 2007. Compavison of Inc: dence of *Demodex folliculorum* on the Eyelash Follicule in Normal people and Blepharitis pat: ents. Turkinge para zitoloji Dergisi. 31(4): 296-297.
13. Kemal, M., Z. Sumer, M.I. Toker, H. Erdogan, A. Topalkara and M. Akbulut, 2005. The prevalence of *Demodex folliculorum* in blepharitis patients and the normal popu lation. Ph thamic Epidemiol., 12(4): 287-90.
14. Ivy, S.P., C.L. Mackall, L. Gore, R.E. Gress and A. Hartley, 1995. Demodectidosis in childhood acute lymphoblastic leukemia: An opportunistic infection occurring with immunosuppression. J. Pediatrics. 127: 751-754
15. Grosshans, E., M. Dremer and J. Malevill, 1974. *Demodex folliculorum* and histogenesis of granulomatous acne rosace. Hautartz. 25: 166-177.
16. Roihu, T. and A.L. Kariniemi, 1998. *Demodex* mites in acne rosacea. J. Cutan Pathol., 25(10): 550-2.
17. Eston, M.D. and M. Dirk, 2010. Demodex mites: facts and controversy Clinics Dermatol., 2: 502-504.