

Effect of Dibutyl Phthalate on Sperm Quality and Liver Injury in Adult Male Rabbits

Lamia Rihani, Bachir Loukil and Kamel Khelili

Laboratory of Research Ecophysiology, Department of Animal Biology,
Faculty of Sciences, university Badji Mokhtar. Annaba 23000, Algeria

Abstract: The modifying effects of liver injury and semen quality after DBP exposure were studied using male adult rabbits. Twenty for male animals, aged 6 months at the commencement, were divided into 4 groups of 6 rabbits each. Rabbits in DBP-exposed groups were given DBP at a dose of 250, 500 and 750 mg/kg/day for 4 weeks. As the result of our treatment, liver injury was confirmed by histopathological and serum Transaminase levels at sacrifice. The relative weights of testis, epididymis were decreased. However, the relative weight of the liver was increased. Also, the sperm abnormality rate was increased. The serum Transaminase levels were elevated in the treatment groups compared with the control group. Furthermore, histopathological abnormality of the liver, such as fibrosis was seen in the rabbits treated with DBP. This data suggested that DBP induces semen quality and liver injury.

Key words: DBP • Toxicity • Liver • Sperm • Serum Transaminase

INTRODUCTION

Phthalate esters are omnipresent industrial chemicals usually used as plasticizers [1, 2] and found in such different consumer products as cosmetics [3]. Some phthalate esters apply hepatic and reproductive toxicity in rodents [1-3]. It is thought that their hepatotoxicity may not be related to humans because of species-specific induction of peroxisome proliferation [4]. DBP a commonly used industrial health solvent and plasticizer, has been recognized as ubiquitous contaminant of environment and is suspected to be an endocrine disrupter [5]. Besides its role as endocrine disruptor, DBP has been shown to exert hepatotoxic, cytotoxic, mutagenic effects and produce renal, pulmonary and reproduction dysfunction in experimental animals [6].

DBP is a developmental toxicant in rats and mice [7]. It is known to affect male fertility, cause testicular atrophy in young rats and produce embryo mortality and teratogenicity in rodents [8]. Two recent human studies have explored associations between conventional measures of semen quality and urinary concentrations of phthalates [9]. Toxicological studies on animals shows that DEHP, DBP, DEP causes decrease in testicular and epididymal weight, cryptorchidism, lesion in testes,

Leydig cell hyperplasia, deterioration of semen quality and decrease in fertility index [10]. In addition to the toxic effects in the reproductive tract, DBP exposure also causes an increase in liver weight and creates hepatic lesions [11]. The increase in liver organ weight is accompanied by enhanced total cytochrome P450 (CYP) enzyme activity [12].

The objective of the current study was to determine whether exposure to DBP at the dose levels caused morphological changes in the adult rabbit's liver also altered semen quality.

MATERIALS AND METHODS

Animals: Twenty four male adult rabbits *Oryctolagus cuniculus* (east Algeria, Annaba) weighing 1700 to 2000 g were used for this study. The animals were acclimatized to laboratory conditions for at least 7 days prior to initiating the study in rooms with a 12-h light/dark cycle designed to control relative humidity 50±5% and temperature 22±1°C. Food and tap water were available *ad libitum*.

Experimental Design: The rabbits were divided into four groups, each comprising 06 individuals. Solutions of DBP were prepared by diluting DBP (CAS 84-74-2, 99.8% pure

PM: 278.345, density: 1.047) in deionized water. Rabbits in DBP-exposed groups were given DBP at a dose of 250, 500 and 750 mg/kg/day (5 ml/ kg body weight), by oral gavage for 4 consecutive weeks. Rabbits in the control group were orally administered corn oil in the same volume for 4 consecutive weeks.

At the end of the behavioral experiment, all animals were killed by decapitation at week 5. Before sacrifice, blood samples were taken for measurement of serum Transaminase. The liver, testes and epididymis were immediately removed and weighed. The liver of each rabbits was used for histopathological study.

Sperm Analysis: Six rabbits from each group were used for sperm analysis. The morphology of sperm is measured using method (O.M.S, 1993) [13]. Abnormal shapes were defined as follows: no head, banana shape head, excessive hook, pin head, tow head, amorphous, two tails and short tail.

Histopathological Evaluation: After sacrifice, rabbit's liver of each group were fixed in Bouin's solution and dehydrated with 70% ethanol. The tissues were fixed in paraffin and then 5 mm sections were cut and mounted onto slides. The slide sections were stained with haematoxylin and eosin. The histopathological features of the livers were determined by optical microscopy [14].

Statistical Analysis: Data were presented as mean ± standard all through the text. DBP effects were analyzed by ANOVA. Significance was set less than 0.05. When a significant treatment effect was observed,

a Dunnett's test (control vs. treatment groups) was used to compare the treatment groups with the control group.

RESULTS

Relative Organ Weights: The relative weight of liver was significantly larger in the treatment groups(250,500 and 750 mg/kg/day) than those of each corresponding control group. However, the relative weights of the testes and epididymis were significantly lower in the treatment groups (250,500 and 750 mg/kg/day) than the corresponding control group (Table 1).

Sperm Analysis: The results of sperm analysis are summarized in (Table 2).Sperm abnormality of the treated groups (250,500 and 750 mg/kg/day) was significantly larger than the corresponding control group.

Serum Transaminase Levels: Both serum aspartate aminotransferase (AST) and alanine aminotransferase (ALT) levels were significantly elevated in the treated groups (500 and 750 mg/kg/day) compared to control group (Figure 1).

Histopathological Findings: On histopathological examination (Fig. 1), we note fibrosis, increased area of Glisson's, pigmentation and infiltration of inflammatory cells were seen in the liver samples from the treated groups (500 and 750 mg/kg/day) compared to the control group.

Table 1: Relative organ weights of animals

Relative organ weight (g)	DBP (mg/kg/day)				Experimental groups
	Control group	250 mg/kg	500 mg/kg	750 mg/kg	
Testis	1.460 ± 0.114	1.360 ± 0.114	1.220 ± 0.083**	0.880 ± 0.13***	
Epididymis	0.256 ± 0.032	0.222 ± 0.019	0.190 ± 0.01*	0.170 ± 0.01**	
Liver	3.060 ± 0.114	3.244 ± 0.084*	3.744 ± 0.260**	4.462 ± 0.344**	

Data are mean ± SD values

Abbreviation: DBP, Di-n-butyl phthalate.

*(P=0.05); ** (P=0.01); (***)P=0.001): significant difference from the control group.

Table 2: The data of sperm abnormality of animals

Sperm analysis rate (%)	DBP (mg/kg/day)				Experimental groups
	Control group	250 mg/kg	500 mg/kg	750 mg/kg	
Sperm abnormality	3.300±0.797	3.560±0.619	6.206±0.724**	9.174±0.581***	

Data are mean ± SD values

Abbreviation: DBP, Di-n-butyl phthalate.

*(P=0.05); ** (P=0.01); (***)P=0.001): significant difference from the control group.

Table 3: Serum Transaminase levels of animals

Serum Transaminase levels (IU/L)	DBP (mg/kg/day)				Experimental groups
	Control group	250 mg/kg	500 mg/kg	750 mg/kg	
AST	30,4 ± 7,37	30,2± 3,56	39,8±5,72	65,8±16,9**	
ALT	42,4 ± 8,65	43,8 ± 9,39	56,2± 6,46*	72 ±12,5**	

Data are mean ± SD values

Abbreviation: DBP; Di-n-butyl phthalate. AST; aspartate aminotransferase. ALT; alanine aminotransferase.

*($P=0.05$); ** ($P=0.01$): significant difference from the control group.

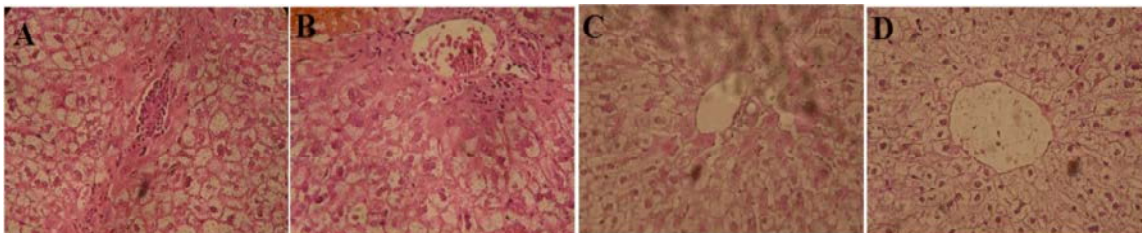


Fig. 1: Histological changes of the rabbit's liver in the different treatment groups. The photomicrographs were taken at X 400 magnification by hematoxylin and eosin staining. (Figs. A and B), no such evidence change of liver injury in control group and group treated at dose 250 mg/kg/day. (Figs. C and D), note fibrosis, increased area of Glisson's, pigmentation and infiltration of inflammatory in the liver samples from the treated groups (500 and 750 mg/kg/day).

DISCUSSION

The present study clearly showed that liver injury altered in animals treated with DBP. Furthermore, reproductive organ toxicity could be seen in the sperm abnormality in this study. Although the doses used in our study were higher than the levels found in the general environment, it should be considered that people are exposed to this chemical throughout his entire life-time. The lipophilicity and long half-life of DBP could result in his accumulation to ultimately high levels in the body.

Male reproductive organ toxicity of DBP was shown to increase sperm abnormalities in rabbits, whereas relative organ weights of testes and epididymis were decreased in the treatment group. A major target organ for DBP reproductive toxicity in rodents is the testis in general and the seminiferous tubules in particular [1, 15].

Sperm evaluation is a useful indicator for assessing the effects of environmental pollutants on the reproductive function of the testis in experimental animals and humans. The abnormal sperm percentage simultaneously increased significantly after DBP exposure. Our observations are in concordance with those reported by Ramesh *et al.* [16] showing that subchronic inhalation exposure (60 days) to BaP altered sexual function in rats by impairing testicular endocrine and exocrine function, increasing the rate of spermatozoa with abnormal morphologies [17]. Furthermore, epidemiological

studies also found a direct relationship between exposure to PAHs and poor semen quality in young men in the Czech Republic, who were exposed to air that, was highly polluted with PAHs [18]. Morphological sperm abnormalities are thought to reflect genetic toxicity to the germ cell. PAHs are a class of strong mutagens, especially when they are metabolically activated [19, 20].

The relative liver weights of the 500 and 750 mg/kg/day DBP treated rabbits were significant higher than those of control rabbits and this was probably due the hepatotoxic effect of DBP.

In this study, the liver injury was confirmed by histopathological examination and serum Transaminase. We founded that AST and ALT (serum Transaminase) were elevated in the treated groups; which indicated the damage of liver cells after DBP exposure. Histopathology examination revealed that with prolonged exposure, DBP imparted adverse effects on the liver. The toxicological effects of dibutyl phthalate in liver (increase in liver weight and histopathological changes) are correlated with an increase in the marker enzyme (palmitoyl CoA oxidase) for peroxisome proliferation [21].

CONCLUSION

The results of the present study suggested that liver injury and semen quality were the results of DBP toxicity. This data might be caused by the inhibition of its

metabolism in the liver and its accumulation. Furthermore, this implies that other endocrine disrupters which are detoxified in the liver will be also having their effects under liver dysfunction. The effects of DBP on humans should not be underestimated and further examination of this issue is needed.

REFERENCES

1. Thomas, J.A. and M.J. Thomas, 1984. Biological effects of di-(2-ethylhexyl) phthalate and other phthalic acid esters. *Critical Reviews in Toxicology*, 13: 283-317.
2. Wams, T.J., 1987. Diethylhexylphthalate as an environmental contaminant a review. *Science of the Total Environment*, 66: 1-16.
3. Goldy, E.W. and A.E. Mortlock, 1973. The determination of Di-n-alkyl phthalates in cosmetic preparations by gas-liquid chromatography. *Analyst*, 98: 493-501.
4. Ashby, J., A. Brady, C.R. Elcome, B.M. Elliott Ishmael and J. Odum, 1994. Mechanistically based human hazard assessment of peroxisome proliferator induced hepatocarcinogenesis. *Human and Experimental Toxicology*, 13: 111-7.
5. Koisumi, M., M. Ema, A. Hirose and R. Hasegawa, 2000. Recent studies on toxic effects of phthalate esters on reproduction and development focus on di (2-ethyl hexyl) phthalate and di n utyl phthalate. *The Japan Food Chemical Research Foundation*, 7: 65-73.
6. Maff, 1984. Phthalates in food and infant formulae, Food Surveillance Information acid esters. *Crit. Rev. Toxicol.*, 13: 283-317.
7. Fisher, J.S., S. Macpherson, N. Marchetti and R.M. Sharpe, 2003. Human 'testicular dysgenesis syndrome': a possible model using in-utero exposure of the rat to Dibutyl phthalate. *Human Reproduction*, 18: 1383-1394.
8. Kavlock, R., K. Boekleheide, R. Chapin, M. Cunningham, E. Faustman and P. Foster, 2002. NTP Center for the Evaluation of Risks to Human Reproduction: Phthalates Expert Panel report on the reproductive and developmental toxicity of Di-n-butyl phthalate. *Reproductive Toxicology*, 16: 489-527.
9. Duty, S.M., M.J. Silva, D.B. Barr and J.W. Brock, 2003. Phthalate exposure and human semen parameters. *Epidemiology*, 14: 269-277.
10. Akingbemi, B.T., G.R. Klinefeter, B.R. Zirkin and M.P. Hardy, 2004. Phthalate-induced Leydig cell hyperplasia is associated with multiple endocrine disturbances. *Proceedings of the National Academy of Sciences USA*, 101: 775-80.
11. Wine, R.N., L.H. Li, L.H. Barnes, D.K. Gulati and R.E. Chapin, 1997. Reproductive toxicity of di-n-butylphthalate in a continuous breeding protocol in Sprague-Dawley rats. *Environ. Health Perspectives*, 105: 102-107.
12. Walseth, F. and O.G. Nilsen, 1986. Phthalate esters: Effects of orally administered dibutylphthalate on cytochrome P-450 mediated metabolism in rat liver and lung. *Acta Pharmacologica and Txicologica. Copenh*, 59: 263-269.
13. O.M.S, 1993. Organisation Mondiale de la Santé. Analyse du sperme humain et de l'interaction des spermatozoïdes avec le mucus cervical. éd,INSERM. pp: 55-56.
14. Martojar and M. Martoja, 1967. Initiation aux techniques de l'histologie animale, éd. MASSON, pp: 346.
15. Marsman, D., 1995. NTP technical report on the toxicity studies of Dibutylphthalate (CAS No. 84-74-2) administered in feed to F344/N rats and B6C3F1 mice. *Toxic. Rep. Ser.*, 30: 1-5.
16. Ramesh, A., F. Inyang, D.D. Lunstra, M.S. Niaz, P. Kopsombut, K.M. Jones, D.B. Hood, E.R. Hills and A.E. Archibong, 2008. Alteration of fertility endpoints in adult male F-344 rats by subchronic exposure to inhaled benzo(a)pyrene. *Exp. Toxicol. Pathol.*, 60: 269-280.
17. Jeng, H.A. and L. Yu, 2008. Alteration of sperm quality and hormone levels by polycyclic aromatic hydrocarbons on airborne particulate particles. *J. Environ. Sci. HealthA: Tox.Hazard. Subst. Environ. Eng.*, 43: 675-681.
18. Sram, R.J., B. Binkova, P. Rossner, J. Rubes, J. Topinka and J. Dejmek, 1999. Adverse reproductive outcomes from exposure to environmental mutagens. *Mutat. Res.*, 428: 203-215.
19. Revel, A., H. Raanani, E. Younglai, J. Xu, R. Han, J.F. Savouet and R.F. Casper, 2001. A natural aryl hydrocarbon receptor antagonist, protects sperm from DNA damage and apoptosis caused by benzo(a)pyrene. *Reprod. Toxicol.*, 15: 479-486.

20. Singh, R., R.J. Sram, B. Binkova, I. Kkalina, T.A. Popov, T. Georgieva, S. Garte, E. Tailoli and P.B. Farmer, 2007. The relationship between biomarkers of oxidative DNA damage, polycyclic aromatic hydrocarbon DNA adducts antioxidant status and genetic susceptibility following exposure to environmental air pollution in humans. *Mutat. Res.*, 620: 83-92.
21. NTP (National Toxicology Program), 2003. NTP technical report on toxicity studies of dibutyl phthalate administered in feed to F344/N rats and B6C3F1 mice. Toxicity Report Series Number 30.1995. NIH Publication, pp: 95-3353.